

Case Report

Hyperpigmentation on Head and Neck Caused by Polymyxin B: A Rare Case

F Kaya, E Tuğcugil¹

Department of Anesthesiology and Critical Care, Ahi Evren Thoracic and Cardiovascular Surgery Training and Research Hospital, Health Sciences University Trabzon, ¹Department of Anesthesiology and Critical Care, Karadeniz Technical University, Faculty of Medicine, Trabzon, Turkey

Received:

13-Mar-2023;

Revision:

17-Apr-2023;

Accepted:

01-May-2023;

Published:

21-Sep-2023

ABSTRACT

Polymyxin B was widely used to treat drug-resistant gram-negative bacteria and showed a better antibacterial effect. However, it is associated with some side effects. It should be remembered that polymyxin B may cause hyperpigmentation, albeit rare. This is a case report of a 68-year-old male patient who developed hyperpigmentation following treatment of a chest infection with polymyxin B. He was a known patient with chronic kidney disease and chronic obstructive pulmonary disease followed up in the intensive care unit due to acute exacerbation of COPD. Later, polymyxin B treatment was started due to the development of pneumonia caused by the multidrug-resistant *Acinetobacter baumannii*. On the second day of polymyxin B treatment, hyperpigmentation developed in the face and neck region. The fact that the patient had chronic kidney disease possibly facilitated the development of skin hyperpigmentation due to the cumulative effect of polymyxin B. Hyperpigmentation which a rare side effect of polymyxin B may occur in those with underlying kidney disease.

KEYWORDS: *Chronic obstructive pulmonary disease, polymyxin B, skin hyperpigmentation*

INTRODUCTION

Polymyxin B (PMB) is an antibiotic effective against commonly drug-resistant, gram-negative bacteria. Polymyxin B binds to the lipopolysaccharide in the membrane of gram-negative bacteria, displacing Mg^{2+} and Ca^{2+} , thus disrupting the integrity of the bacterial cell membrane and increasing permeability.^[1,2] Combined administration of PMB and meropenem restores meropenem's penetrating ability and susceptibility and treats carbapenem-resistant bacterial infections.^[3-5]

Nephrotoxicity and neurotoxicity are the most common adverse drug reactions of intravenous polymyxin B treatment.^[6] Cases of skin hyperpigmentation caused by PMB are not very common. Currently, the pathogenesis of PMB-induced skin hyperpigmentation is controversial and still unknown.

In this case, we discuss a patient with pneumonia who was treated with intravenous PMB in the intensive care

unit and subsequently experienced a rare adverse drug reaction, skin hyperpigmentation.

CASE PRESENTATION

A 68-year-old man, diagnosed with Chronic Obstructive Pulmonary Disease (COPD) 20 years ago, was using an inhaler bronchodilator, β -mimetic and home-type BiPAP device. He was followed up for hypertension and chronic kidney disease in his medical history. He was brought to the emergency department of our hospital due to a cough and shortness of breath. He was followed up in the chest diseases service with the prediagnosis of acute exacerbation of COPD and pneumonia. Meropenem 500 mg BDS and Linezolid 2 mg BDS (empirical), methylprednisolone

Address for correspondence: Dr. E Tuğcugil,

Department of Anesthesiology and Reanimation, Karadeniz Technical University/Parabi Hospital, Kalkınma Mahallesi, Ortahisar, Trabzon - 61080, Turkey.
E-mail: erstug@gmail.com

Access this article online

Quick Response Code:



Website: www.njcponline.com

DOI: 10.4103/njcp.njcp_185_23

This is an open access journal, and articles are distributed under the terms of the Creative Commons Attribution-NonCommercial-ShareAlike 4.0 License, which allows others to remix, tweak, and build upon the work non-commercially, as long as appropriate credit is given and the new creations are licensed under the identical terms.

For reprints contact: WKHLRPMedknow_reprints@wolterskluwer.com

How to cite this article: Kaya F, Tuğcugil E. Hyperpigmentation on head and neck caused by polymyxin B: A rare case. *Niger J Clin Pract* 2023;26:1393-5.

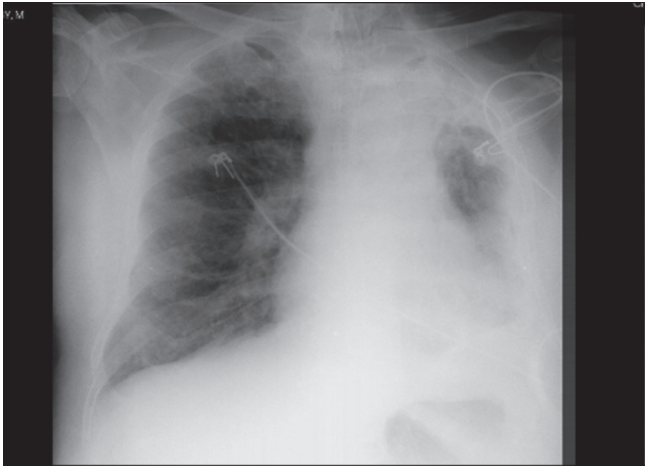


Figure 1: Pulmonary infiltrates in both lungs

40 mg. OD, salbutamol-ipratropium inhaler 600 µg. OD, and budesonide 400 µg.OD were started for treatment. He was transferred to our intensive care unit due to the development of respiratory failure on the fifth day of his follow-up in COPD exacerbation and pneumonia. When the laboratory results are examined, HB: 14 g/dl, CRP: 194 mg/L, leukocytes: 4,200 µL, neutrophils: 65%, lymphocytes: 23.9%, arterial blood gas pH: 7.21, glucose: 140 mg/dl, PO₂: 59.2, HCO₃: 30.2, PCO₂: 65.4, BUN: 191 mg/dl, CR: 3.8 mg/dl and GFR: 15 mL/min/1.73 m² were observed. (PA chest x-ray showed atelectasis in the left lung, and pulmonary infiltrates in both lungs [Figure 1]. He was intubated and followed up on a mechanical ventilator. Upon the growth of *acinetobacter baumannii* in the sputum culture, a loading dose (2.000.000 IU) and maintenance dose PMB (1.250.000 IU twice daily) was started in addition to the current antibiotic treatment. On the fourteenth day of intubation, when there was no improvement in the clinical picture, a percutaneous tracheostomy was performed. Cutaneous hyperpigmentation limited to the area around the scalp, face, and neck was observed on day 2 when the tracheostomy was opened, and PMB was initiated [Figure 2]. After consultation with a chest diseases specialist, it was decided to continue the current treatment. Hyperpigmentation changes were monitored daily. Sixteen days after discontinuation of PMB, the patient's eye area improved significantly, followed gradually by the whole face and neck.

DISCUSSION

Polymyxins are prescribed more frequently due to the increasing incidence of infections caused by multidrug-resistant gram-negative bacteria in hospital settings. Nephrotoxicity is the most common side effect of polymyxin.^[7] In addition to nephrotoxicity, mild and rare side effects of polymyxin, such as pruritus, rash, cough, and skin hyperpigmentation, have also been observed.^[8]

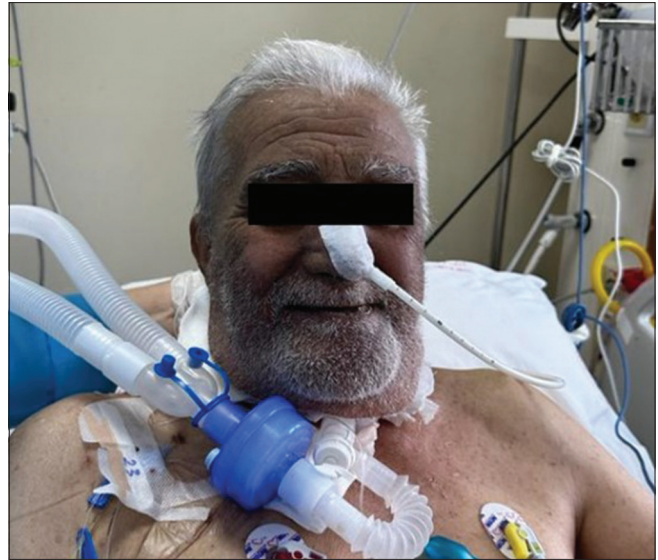

Figure 2: Head and facial hyper-pigmentation after Polymyxin B therapy

In one study, it was stated that 8% of 249 patients had hyperpigmentation.^[9] Since PMB is mainly excreted by the kidney, it has been argued that the immature renal function of newborns may be a possible cause for hyperpigmentation due to the cumulative effect of polymyxin.^[8] In addition, existing kidney damage is a risk factor for hyperpigmentation due to PMB.^[10] Since our patient had stage 5 (GFR <15) chronic kidney disease,^[11] we thought, like Gothwal *et al.*,^[12] that the reason for the gradual increase in hyperpigmentation was due to the cumulative effect of PMB. In the literature, it has been shown that hyperpigmentation occurs in the early period, on the third day of treatment, in only 15% of the cases.^[13] In our case, we thought that the onset of hyperpigmentation in the early period (on the second day of treatment) was associated with chronic kidney disease. It is thought that hyperpigmentation due to PMB is frequently seen in the head and neck region due to the greater distribution of melanocytes.^[14] In our case, hyperpigmentation was observed in the head and neck region, supporting this information. In our case, the development of hyperpigmentation 1 hour after the tracheostomy was opened with local anesthesia (prilocaine 4 mg/kg) suggested methemoglobinemia. Methemoglobinemia can occur even at non-toxic local anesthetic doses.^[15] Peripheral cyanosis other than methemoglobinemia was not observed in our case.

Moreover, we did not encounter neurological and cardiological symptoms caused by local anesthetic toxicity. There were no findings related to hypoxemia and hypercarbia in control arterial blood gas after hyperpigmentation. The absence of any change in arterial blood gas and peripheral cyanosis also helped exclude it in COPD exacerbation.

CONCLUSION

Once PMB-induced hyperpigmentation has been observed, we must weigh the advantages and disadvantages of using PMB and strike a balance between therapeutic effects and adverse effects by measures such as dose adjustment, discontinuation of drug administration, and switching to alternative antibiotics. Particular attention should be paid to dose adjustment in patients with kidney damage. In the differential diagnosis, other causes of hyperpigmentation should be excluded.

Declaration of patient consent

The authors certify that they have obtained all appropriate patient consent forms. In the form, the patient has given his consent for his images and other clinical information to be reported in the journal. The patients understand that their names and initials will not be published and due efforts will be made to conceal their identity, but anonymity cannot be guaranteed.

Statement of ethics

In this study, written permission was obtained from individuals in accordance with the Helsinki Declaration of the World Medical Association.

Financial support and sponsorship

Nil.

Conflicts of interest

There are no conflicts of interest.

REFERENCES

1. Neiva LB, Borges FT, Watanabe M, Pessoa Ede A, Barbosa DA Vattimo Mde F. Nephrotoxicity of polymyxin B: Experimental study in cells and implications for nursing practice. *Rev Esc Enferm USP* 2014;48:272-7.
2. Yu Z, Qin W, Lin J, Fang S, Qiu J. Antibacterial mechanisms of polymyxin and bacterial resistance. *Biomed Res Int* 2015; 2015:679109.
3. Kim KS, Kim T, Pan JG. *In vitro* evaluation of ciclopirox as an adjuvant for polymyxin B against gram-negative bacteria. *J Antibiot (Tokyo)* 2015;68:395-8.
4. Zavascki AP, Goldani LZ, Li J, Nation RL. Polymyxin B for the treatment of multidrug-resistant pathogens: A critical review. *J Antimicrob Chemother* 2007;60:1206-15.
5. Falagas ME, Kasiakou SK, Tsiodras S, Michalopoulos A. The use of intravenous and aerosolized polymyxins for the treatment of infections in critically ill patients: A review of the recent literature. *Clin Med Res* 2006;4:138-46.
6. Landman D, Georgescu C, Martin DA Quale J. Polymyxins revisited. *Clin Microbiol Rev* 2008;21:449-65.
7. Justo JA, Bosso JA. Adverse reactions associated with systemic polymyxin therapy. *Pharmacotherapy* 2015;35:28-33.
8. Molina J, Cordero E, Pachón J. New information about the polymyxin/colistin class of antibiotics. *Expert Opin Pharmacother* 2009;10:2811-28.
9. Cervellini G, Comelli I, Lippi G. Rhabdomyolysis: Historical background, clinical, diagnostic and therapeutic features. *Clin Chem Lab Med* 2010;48:749-56.
10. Zheng G, Cao L, Che Z, Mao E, Chen E, He J. Polymyxin B-induced skin hyperpigmentation: A rare case report and literature review. *BMC Pharmacol Toxicol* 2018;19:41.
11. Murtagh FE, Sheerin NS, Addington-Hall J, Higginson IJ. Trajectories of illness in stage 5 chronic kidney disease: A longitudinal study of patient symptoms and concerns in the last year of life. *Clin J Am Soc Nephrol* 2011;6:1580-90.
12. Gothwal S, Meena K, Sharma SD, Polymyxin B. Induced generalized hyperpigmentation in neonates. *Indian J Pediatr* 2016;83:179-80.
13. Mattos KP, Lloret GR, Cintra ML, Gouvea IR, Betoni TR, Mazzola PG, *et al.* Acquired skin hyperpigmentation following intravenous polymyxin B treatment: A cohort study. *Pigment Cell Melanoma Res* 2016;29:388-90.
14. Mattos KPH, Cintra ML, Gouvea IR, Ferreira LA, Velho P, Moriel P. Skin hyperpigmentation following intravenous polymyxin B treatment associated with melanocyte activation and inflammatory process. *J Clin Pharm Ther* 2017;42:573-8.
15. Shibuya M, Hojo T, Hase Y, Kimura Y, Fujisawa T. Methemoglobinemia caused by a low dose of prilocaine during general anesthesia. *J Dent Anesth Pain Med* 2021;21:357-61.