

Is Endometrial Sampler SAP-1 a Good Way to Diagnose the Common Intrauterine Occupying Lesions?—A Diagnostic Study

Y Hong

Department of Obstetrics and Gynecology, Kiangwu Hospital, Macau Special Administrative Region, P.R. China

ABSTRACT

Background: Intrauterine occupying lesion is clinically common in the female reproductive organs. Endometrial cancer is the most critical one among intrauterine occupying lesions, which accordingly is considered as the main indication for endometrial cancer screening, for which endometrial sampler SAP-1 was recommended as an effective sampling tool. **Objective:** This study aimed to evaluate the diagnostic efficacy of SAP-1 for endometrial polyp and uterine submucous myoma. **Materials and Methods:** From August 2018 to June 2022, patients who were hospitalized for undergoing hysteroscopy examination were enrolled in this study. Before the procedure, endometrial samples were collected by the method of SAP-1. The histological results were compared with those by hysteroscopy sampling to analyze the diagnostic efficacy of SAP-1. **Results:** The qualified rate for the SAP-1 sampling was 92.1%, which is a bit lower than that by method of hysteroscopy (95.3%). And the difference was not statistically significant ($P > 0.05$). Endometrial polyp (47.5%) and uterine submucous myoma (7.1%) accounted for the majority of endometrial lesions, while only 11.3% endometrial polyps (17/151) and 0% submucous myomas (0/23) were detected by SAP-1 sampling. **Conclusion:** Endometrial sampler SAP-1 is not effective in detection of solid intrauterine lesions indicated by the imaging examination. Hysteroscopy is recommended for definite diagnosis.

KEYWORDS: Endometrial polyp, endometrial sampler, intrauterine occupying lesion, submucous myoma

Received:
02-Aug-2022;
Revision:
06-Feb-2023;
Accepted:
27-Feb-2023;
Published:
03-Aug-2023

Intrauterine occupying lesions are the common causes of abnormal uterine bleeding, mostly endometrial polyps and submucosal myomas, which totally could constitute over 70%.^[1,2] The clinical manifestations are often atypical, and some lesions have the tendency of malignant transformation, which leads to missed diagnosis and misdiagnosis easily, thus impairing the physical and mental health and quality of life of the patients. As the main method of evaluating intrauterine occupying lesions, ultrasonography has the advantage of being non-invasive, repeatable, and cost-effective but with low specificity. It is not able to judge the specific nature of the lesions, hence, it cannot provide a reliable basis for clinical diagnosis and treatment.^[3,4] Currently, hysteroscopy-guided biopsy still remains the gold standard for confirming the nature of the lesions.^[2,5,6]

In recent years, the incidence of endometrial cancer has shown a younger and rising trend, and early screening among high-risk patients has been a research hotspot and widely recognized. Recently, relevant research has focused on more minimally invasive screening devices and detecting methods. The endometrial sampler SAP-1 [Figure 1], designed by Chinese scholar, is composed of a ring-shaped burr like structure (6 toothed scraps), which can be used for 360-degree circular curettage to obtain small-amount but enough endometrial tissue samples for pathological

Address for correspondence: Dr. Y Hong, Department of Obstetrics and Gynecology, Kiangwu Road #33, Kiangwu Hospital, Macau Special Administrative Region, P.R. China.
E-mail: xmdehy@126.com

This is an open access journal, and articles are distributed under the terms of the Creative Commons Attribution-NonCommercial-ShareAlike 4.0 License, which allows others to remix, tweak, and build upon the work non-commercially, as long as appropriate credit is given and the new creations are licensed under the identical terms.

For reprints contact: WKHLRPMedknow_reprints@wolterskluwer.com

How to cite this article: Hong Y. Is endometrial sampler SAP-1 a good way to diagnose the common intrauterine occupying lesions?—A diagnostic study. *Niger J Clin Pract* 2023;26:896-901.

Access this article online	
Quick Response Code: 	Website: www.njcponline.com
	DOI: 10.4103/njcp.njcp_515_22

diagnosis.^[7] In our previous report,^[8] even in the menopausal population, the satisfaction rate of SAP-1 sampling and the diagnostic accuracy were 88.9% and 97.9%, respectively. A consensus of domestic experts pointed out that obtaining a small amount of endometrial tissue through SAP-1 for pathological examination is an effective method for screening and early diagnosis of endometrial cancer.^[9]

Considering intrauterine occupying lesions are the common indication for endometrial cancer screening, this study aims to explore the diagnostic efficacy of endometrial sampler SAP-1 for endometrial polyps and submucosal myomas.

MATERIALS AND METHODS

This prospective study was performed in the Obstetrics and Gynecology Department of Macau Kiangwu Hospital. Patients who were hospitalized between August 2018 and June 2022 for hysteroscopy due to abnormal uterine bleeding or abnormal echo/intrauterine occupying lesions indicated by ultrasound were enrolled into this trial. The exclusion criteria were listed as below: anticoagulation therapy, diagnosed coagulopathy, acute vaginitis, or acute pelvic infection, a previous diagnosis of invasive cervical cancer, severe cardiopulmonary insufficiency. This study was conducted in accordance with the ethical standards described in an appropriate version of the 1975 Declaration of Helsinki, as revised in 2000, and was approved by the Institutional Review Board of Kiangwu Hospital. An informed written consent was obtained from all the participants. There was no financial interest or any arrangement with the companies producing the instruments used in the study.

Hysteroscopy was carried out by the same experienced gynecologic endoscopist according to the conventional procedure under intravenous anesthesia. A hysteroscope was first inserted into the uterine cavity to have a preliminary view and then withdrawn, then endometrial tissues were sampled sequentially by endometrial sampler SAP-1 (produced by Saipujiuzhou Company, Beijing, China)^[8], and then by routine hysteroscope-assisted sampling method of D and C (dilatation and curettage), or electrocution when necessary.

The endometrial specimens of each patient were sent to the Department of Pathology in two different containers labeled “SAP-1 sampling” and “hysteroscopic sampling” separately. Endometrial samples were routinely fixed in neutral buffered formalin, embedded in paraffin, and stained with hematoxylin and eosin. Each slide was examined by the same pathologist to avoid inter-observer variability.

The slides were considered satisfactory samples when there were enough tissues endometrial glands and stroma under the microscope. Those with no endometrial tissue or without endometrial glands and stroma under the microscope were categorized as unsatisfactory sample and eliminated from the next analysis [see flowchart Figure 2]. The endometrial histological diagnosis used in this study were in accordance with the WHO criteria in 2014.^[10]

Statistical analysis was conducted using Statistical Product and Service Solutions 20.0 (SPSS, Chicago, IL, USA). Satisfactory sampling rate of two sampling methods was defined as the proportion of satisfactory specimens. The distinction of satisfactory sampling between SAP-1 and D and C or electrocution was assessed using Chi-square test. The pathology results of two sampling methods were compared using a double access table. The efficacy of SAP-1 sampling for diagnosing endometrial polyp and submucosal myoma was evaluated by the following indicators: sensitivity, specificity, misdiagnosis rate, missed diagnosis rate, accuracy (true positive plus true negative/true and false positive plus true and false negative). The statistical significance level was set at $P < 0.05$.

RESULTS

1. The comparison of specimen satisfaction rate between two sampling methods

A total of 342 patients were included in this study. The flowchart is given in Figure 2. The satisfaction rate of SAP-1 sampling was 92.1%, which was slightly lower than 95.3% of hysteroscopic D and C or electrocution, but there was no significant difference between the two methods ($P > 0.05$), as indicated in Table 1.

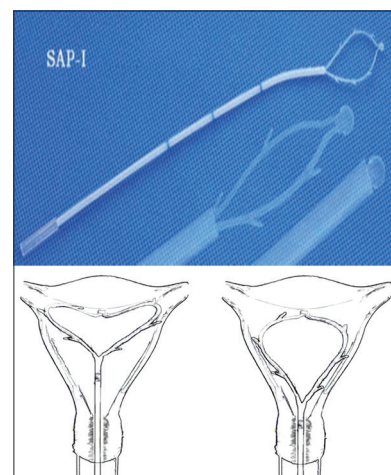


Figure 1: The SAP-1 sampler device. (Reprinted with permission from Hong Y, Xie X, Li CK. The application of endometrial sampler SAP-1 to screening of endometrial cancer in postmenopausal women: A diagnostic test study. *Int J Clin Obstet Gynaecol*, 2021, 5(5):147-151)

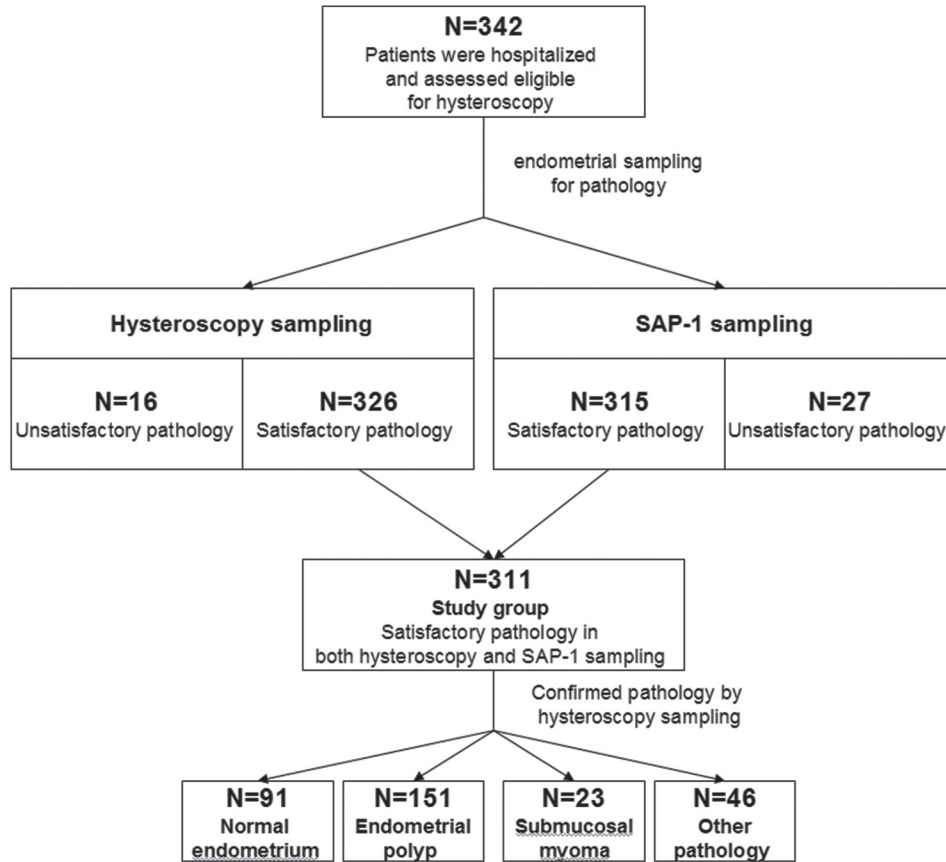


Figure 2: Flowchart of this study

Table 1: Satisfactory and unsatisfactory specimens obtained using two methods

Sampling method	Satisfactory (n)	Unsatisfactory (n)	Satisfactory rate (%)	χ^2	P
SAP-1	315	27	92.1	3.00	0.083
Hysteroscopic	326	16	95.3		

Table 2: Comparison between SAP-1 sampling and hysteroscopic sampling on diagnosing endometrial polyp and submucous myoma

	SAP-1 sampling	Hysteroscopic sampling		P
		+	-	
Endometrial polyp	+	17	0	<0.001
	-	134	160	
Submucosal myoma	+	0	0	<0.001
	-	23	288	

2. Histological results of two methods

In this study, hysteroscopic sampling specimens of 326 patients were considered satisfactory in histopathological evaluation. The histological results were as follows: 97 cases of menopausal or proliferative or secretory endometrium, 155 cases of endometrial polyps, 23 cases of submucosal myoma, 9 cases of endometritis, 4 cases of pregnancy tissues, 1 case of hydatidiform mole,

15 cases of endometrial hyperplasia disorder, 3 cases of simple endometrial hyperplasia, 3 cases of complex endometrial hyperplasia, 3 cases of atypical endometrial hyperplasia, and 13 cases of endometrial cancer. The satisfactory histological results of 315 patients with SAP-1 were as follows: 253 cases of menopausal or proliferative or secretory endometrium, 17 cases of endometrial polyps, 7 cases of endometritis, 4 cases of pregnancy tissues, 1 case of hydatidiform mole, 14 cases of endometrial hyperplasia disorder, 3 cases of simple endometrial hyperplasia, 4 cases of atypical endometrial hyperplasia, and 12 cases of endometrial cancer. Endometrial samples of 311 patients were considered as satisfactory both with SAP-1 and hysteroscopy sampling. Taking histological diagnosis of hysteroscopy sampling as the gold standard and eliminating those unsatisfactory samples in SAP-1 sampling, 91, 151, and 23 patients were enrolled

Table 3: The pertinent indexes of SAP-1 sampling for histological diagnosis

	SAP-1 sampling	Hysteroscopic sampling		Sensitivity (%)	Specificity (%)	Misdiagnosis rate (%)	Missed diagnosis rate (%)	Accuracy (%)
		+	-					
Normal endometrial group	+	88	163	96.7	25.9	64.9	5.0	46.6
	-	3	57					
Endometrial polyp group	+	17	0	11.3	100	0	45.6	56.9
	-	134	160					
Submucosal myoma group	+	0	0	0	100	0	7.4	92.6
	-	23	288					

in normal endometrium group, endometrial polyp group, and submucous myoma group respectively.

3. The comparison of SAP-1 sampling with hysteroscopic sampling for diagnosing endometrial polyp and submucous myoma

Taking the pathological result of hysteroscopic sampling as the gold standard, only 11.3% cases of endometrial polyps (17/151) and 0% case of submucous myomas (0/23) were detected by SAP-1 sampling. The diagnosis rate of SAP-1 sampling for either endometrial polyp or submucous myoma was significantly lower than hysteroscopic sampling, as shown in Table 2.

4. The indexes of efficacy of SAP-1 sampling for histological diagnosis in different groups

Compared with hysteroscopic sampling, the sensitivity, specificity, misdiagnosis rate, missed diagnosis rate, and accuracy of SAP-1 for histological diagnosis are shown in Table 3. Among 151 patients with endometrial polyps, only 17 cases were detected by SAP-1. None of the 23 patients with submucosal myoma was detected. 88 of 91 cases of normal endometrium were detected (2 cases and 1 case showing endometritis and endometrial hyperplasia disorder, respectively, by SAP-1 sampling). The sensitivity and specificity of SAP-1 sampling for diagnosing normal endometrium were 96.7% and 25.9%, respectively, and the accuracy was 46.6%.

DISCUSSION

Intrauterine occupying lesion is clinically common in the female reproductive system. Patients often present with abnormal uterine bleeding, while those without any symptoms are mostly detected by ultrasound examination, with good sensitivity and positive predictive value. Saline infusion sonohysterography (SIS), by instilling normal saline into the endometrial cavity to enhance detection of endometrial abnormalities, has been reported to better define lesions already detected by standard trans-vaginal ultrasonography, and be able to reach a diagnostic accuracy as high as hysteroscopy.^[11] Despite all this, even after large-scale imaging examinations such as

CT and MRI, accurate diagnostic results cannot be provided. Ultimately, invasive operations such as D and C and hysteroscopy are often needed to make a clear diagnosis.^[12]

In the past, the common methods of endometrial cancer screening include ultrasound, serum tumor markers, diagnostic curettage, hysteroscopy, endometrial cytology, etc. There has not been uniform recommendation at home and abroad.^[13] Endometrial samplers, represented by Pipelle and Tao brush, using principle of circular scraping or negative pressure suction to obtain endometrial samples for micro histopathological diagnosis, have recently become a new, simple, safe, painless, high-quality, and low-cost screening method. Endometrial sampler SAP-1, designed by Chinese scholar and manufactured by Chinese company, is considered among Chinese experts as an effective way to screen and early diagnose endometrial cancer,^[8] although the relevant research articles in English are quite limited. SAP-1 was proved to provide more sufficient materials for cytology than D and C for histology (95.9~96.2% vs. 76.2~87.2%). Even among postmenopausal women, the adequacy rate of endometrial samples obtained by SAP-1 for cytology was 96%.^[7,14] In addition, SAP-1 sampling could be used for histology. In Li's research^[15] and our previous study among postmenopausal women,^[8] the adequate endometrial specimens were obtained by SAP-1 for histopathological examination in 81.32 ~ 88.9% of subjects. In this study, the satisfaction rate of SAP-1 sampling was remarkable as well, at 91.6%. Furthermore, when taking atypical hyperplasia and endometrial carcinoma as a positive result, the diagnostic accuracy of SAP-1 sampling for cytology or histology was up to 81.5~96%,^[7,14,15] and also similar to other different types of endometrial sampling devices.^[16] Accordingly, sampling method of SAP-1 has been widely recognized by Chinese experts.^[9]

Considering intrauterine occupying lesion is one of the main indications for endometrial cancer screening, we explored to evaluate the diagnostic efficacy of SAP-1 for endometrial polyp and uterine submucous myoma. The most common pathological types of endometrial lesions

in this study are endometrial polyps (47.1%, 155/326) and submucous myomas (7.1%, 23/326), but only 17 cases of endometrial polyps were detected by SAP-1, with a diagnostic sensitivity of only 11.3%, and none of submucous myoma was detected. The missed diagnosis rate is quite high. In Li's research,^[15] 182 patients who required an endometrial biopsy were enrolled. The diagnostic sensitivities for endometrial polyps and submucous myoma using the SAP-1 sampler were 12.5% and 0%, respectively. The similar unsatisfactory result could be found in researches with other sampling devices, such as Pipelle and Uterobrush.^[17,18] This is because the two lesions mentioned above belong to solid intrauterine occupying lesions. Although the burr design of SAP-1 presenting a certain ability to scrape the endometrium, it can only collect the mucosal tissue on the surface of the uterine cavity, and cannot go deep into the interstitial or muscular tissue below it. Therefore, the corresponding pathological diagnosis cannot be obtained,^[7,15] often leading to the misdiagnosis as normal endometrium. According to this study, the sensitivity of SAP-1 for diagnosing normal endometrium can reach 97.4%, but the misdiagnosis rate is also as high as 74%, revealing that for patients highly suspected with endometrial lesions, if SAP-1 screening is negative, further curettage or hysteroscopy should be performed.

CONCLUSION

Hysteroscope-assisted sampling method of D and C or electrocision is better than endometrial sampler SAP-1 in the diagnosis of solid intrauterine occupying lesions like endometrial polyps and submucous uterine fibroids. Hysteroscopy is recommended for definite diagnosis.

Acknowledgements

The author thanks all the investigators involved in this study, including the physicians, nurses, and pathologist. This article does not contain information that overlaps with prior publications, and the content is solely the responsibility of the author.

Authorship contributions

The author confirm contribution to the paper as follows: study conception and design, data collection, analysis and interpretation of results, and draft manuscript preparation were done all by YH. The author reviewed the results and approved the final version of the manuscript.

Ethical statement

All procedures performed in studies involving human participants were in accordance with the ethical standards of the institutional and/or national research committee and with the 1964 Helsinki declaration and

its later amendments or comparable ethical standards. This article does not contain any studies with animals performed by the author. Informed consent was obtained from all individual participants included in the study. This study was approved by the ethics committee of Macau Kiangwu Hospital.

Financial support and sponsorship

This study was financially supported by the Science and Technology Development Fund (FDCT 0003/2022/A) of Macau Special Administrative Region.

Conflicts of interest

There are no conflicts of interest.

REFERENCES

1. Deutsch A, Sasaki KJ, Cholkeri-Singh A. Resectoscopic surgery for polyps and myomas: A review of the literature. *J Minim Invasive Gynecol* 2017;24:1104-10.
2. Filiz T, Doğer E, Corakçı A, Ozeren S, Çalışkan E. The efficacy, cost and patient satisfaction of classic versus office hysteroscopy in cases with suspected intrauterine space occupying lesions with 3-dimension ultrasound and abnormal uterine bleeding. *J Turk Ger Gynecol Assoc* 2009;10:189-93.
3. El-Khayat W, Sleet ME, Mahdi EY. Comparative study of transvaginal sonography and hysteroscopy for the detection of pathological endometrial lesions in women with perimenopausal bleeding. *Middle East Fertil Soc J* 2011;16:77-82.
4. Leão J, Brock MF, Lima GL, Bandeira de Melo M. EP33.01: Intrauterine ultrasonographic evaluation compared to hysteroscopy in the diagnosis of endometrial pathologies at a tertiary oncology hospital in the Amazon. *Ultrasound Obstet Gynecol* 2019;54:434.
5. Gan DE, Jawan RA, Moy FM. Concordance between hysteroscopic impression and endometrial histopathological diagnosis. *Prev Med* 2013;57:S21-3.
6. The Use of Hysteroscopy for the Diagnosis and Treatment of Intrauterine Pathology: ACOG committee opinion, number 800. *Obstet Gynecol* 2020;135:e138-48.
7. Yang X, Ma K, Chen R, Zhao J, Wu C, Zhang N, *et al.* Liquid-based endometrial cytology associated with curettage in the investigation of endometrial carcinoma in a population of 1987 women. *Arch Gynecol Obstet* 2017;296:99-105.
8. Hong Y, Xie X, Li CK. The application of endometrial sampler SAP-1 to screening of endometrial cancer in postmenopausal women: A diagnostic test study. *Int J Clin Obstet Gynaecol* 2021;5:147-51.
9. Yu M, Xiang Y, Ma XX, Xue FX, Feng LM, Wang DB, *et al.* Advances on standards of endometrial cancer screening. *Chin J Obstet Gynecol* 2020;55:307-11.
10. Kurman RJ, Carangiu ML, Herrington CS, Young RH. WHO Classification of Tumours of the Female Reproductive Organs. Vol 6. Lyon: IARC; 2014. p. 125-35.
11. Maheux-Lacroix S, Li F, Laberge PY, Abbott J. Imaging for polyps and leiomyomas in women with abnormal uterine bleeding: A systematic review. *Obstet Gynecol* 2016;128:1425-36.
12. Spadoto-Dias D, Bueloni-Dias FN, Elias LV, Leite NJ, Modotti WP, Lasmar RB, *et al.* The value of hysteroscopic biopsy in the diagnosis of endometrial polyps. *Womens Health (Lond)* 2016;12:412-9.

13. Costas L, Frias-Gomez J, Guardiola M, Benavente Y, Pineda M, Pavón MÁ, *et al.* New perspectives on screening and early detection of endometrial cancer. *Int J Cancer* 2019;145:3194-206.
14. Ma K, Yang X, Chen R, Zhao J, Dong Y, Zhang NY, *et al.* Liquid-based endometrial cytology associated with curettage in the investigation of endometrial carcinoma in postmenopausal women. *Taiwan J Obstet Gynecol* 2016;55:777-81.
15. Li MX, Zhou R, Liu C, Shen DH, Zhao LJ, Wang JL, *et al.* Direct uterine sampling using the SAP-1 sampler device to detect endometrial lesions during histopathological examination. *Eur J Gynaecol Oncol* 2017;38:221-6.
16. Du J, Li Y, Lv S, Wang Q, Sun C, Dong X, *et al.* Endometrial sampling devices for early diagnosis of endometrial lesions. *J Cancer Res Clin Oncol* 2016;142:2515-22.
17. Farrell T, Jones N, Owen P, Baird A. The significance of an 'insufficient' Pipelle sample in the investigation of post-menopausal bleeding. *Acta Obstet Gynecol Scand* 1999;78:810-2.
18. Iavazzo C, Vorgias G, Masteorakos G, Stefanatou G, Panoussi A, Alexiadou A, *et al.* Uterobrush method in the detection of endometrial pathology. *Anticancer Res* 2011;31:3469-74.