

# What is the Margin of Error of Surgeons and Radiological Imaging in Diagnosing Acute Appendicitis?

O Aziz, S Nevin<sup>1</sup>, Y Serhan, B Hakan, A Abdulkadir<sup>2</sup>

General Surgery Department, Health Sciences University, İstanbul Kanuni Sultan Suleyman Training and Research Hospital, İstanbul, <sup>1</sup>General Surgery Department, İstanbul Medipol University, İstanbul, <sup>2</sup>Radiology Department, Medipol Bahcelievler Hospital, İstanbul, Turkey

**Received:**  
24-Apr-2022;  
**Revision:**  
15-Feb-2023;  
**Accepted:**  
01-Jun-2023;  
**Published:**  
03-Aug-2023

## INTRODUCTION

Acute appendicitis is the first-rank disease that causes acute abdomen requiring surgical intervention. A person's lifetime risk of developing appendicitis is around 7% and it can be diagnosed in 7-12% of the general population. It affects mostly men with a rate of 8.6% and 7% of women in the 2<sup>nd</sup> and 3<sup>rd</sup> decades.<sup>[1,2]</sup> Clinical course and examination findings are the most of this disease in the important criteria when making a diagnosis, but we know that a definitive diagnosis of appendicitis is made by histopathologic examination. Accurate timing of diagnosis is very important in preventing morbidity and mortality. A delay in diagnosis

### ABSTRACT

**Background:** Acute appendicitis is the most common emergency requiring surgical intervention in general surgery. Negative appendectomy is defined as the removal of a pathologically normal appendix. **Aim:** In this study, we aimed to show our negative appendectomy rate. **Materials and Methods:** This study was carried out among 2990 patients who were operated on for appendicitis between 2015-2020 at the Health Sciences University, İstanbul Kanuni Sultan Suleyman Training, and Research Hospital. Accrual and historical records of the patients were analyzed using NCSS (Number Cruncher Statistical System) 2007 Statistical Software (Utah, USA) package program. The results were evaluated at the significance level of  $P < 0.05$ . **Results:** The mean age of all patients was 33. Of the patients, 1011 were women and 1979 were men. 27 of the women patients were pregnant. We requested a blood test (WBC count) and an abdominal ultrasound for all our patients who came with the complaint of abdominal pain in the right lower quadrant. Negative appendectomy was performed with ultrasonography in 622 patients with pathological diagnoses of lymphoid hyperplasia and fibrous obliteration (20.8%). We had abdominal computerized tomography (CT) for 285 patients and abdominal magnetic resonance imaging (MRI) for 16 of 27 pregnant women (59.25%) due to unclear clinical picture. Diagnostic laparoscopy was performed in 36 of the patients who underwent CT and 4 of the patients who underwent MRI since the diagnosis could not be made. We performed unnecessary appendectomy in 21.2% of the patients. **Conclusion:** With the increasing clinical follow-up experience of surgeons and developing technology in radiology, our aim is to minimize the negative appendectomy rate as much as possible.

**KEYWORDS:** *Appendicitis, leukocytosis, pathological diameter, radiology, surgery*

can lead to sepsis due to perforation. So surgery should not be delayed. At the same time, it is also important to avoid unnecessary surgical intervention by making a correct diagnosis. Uncomplicated acute appendicitis can be treated with a non-operative method. In some patients, clinical and post-operative pathological examinations are not compatible with each other (20%). Therefore, we conducted this study to determine whether there are


**Address for correspondence:** Dr. S Nevin, General Surgery Department, Medipol University, Cobancesme Mahallesi, Fatih Caddesi No:1/8 Bahcelievler/Istanbul, Zip Code: 34197, İstanbul/Turkey. E-mail: nsakoglu@medipol.edu.tr

This is an open access journal, and articles are distributed under the terms of the Creative Commons Attribution-NonCommercial-ShareAlike 4.0 License, which allows others to remix, tweak, and build upon the work non-commercially, as long as appropriate credit is given and the new creations are licensed under the identical terms.

**For reprints contact:** WKHLRPMedknow\_reprints@wolterskluwer.com

**How to cite this article:** Aziz O, Nevin S, Serhan Y, Hakan B, Abdulkadir A. What is the margin of error of surgeons and radiological imaging in diagnosing acute appendicitis? Niger J Clin Pract 2023;26:881-8.

### Access this article online

<b>Quick Response Code:</b> 	<b>Website:</b> www.njcponline.com
	<b>DOI:</b> 10.4103/njcp.njcp_284_22

patients who underwent unnecessary appendectomies and to calculate our negative appendectomy rate. In this situation, the first question that comes to mind is whether every patient with suspected appendicitis should be operated. Our aim is to reduce our negative appendectomy rate with the support of developing radiological technology. So we wanted to see our own margin of error in our 5-year study. This is an introductory post.

## MATERIAL AND METHOD

This retrospective study was approved by the Bioethics Committee of the Medical University of Health Sciences University, İstanbul Kanuni Sultan Suleyman Training and Research Hospital, General Surgery Clinic, İstanbul/Turkey (No. 2021.01.234) All procedures performed in studies involving human participants were in accordance with the ethical standards of the institutional and/or national research committee and with the 1964 Helsinki Declaration and its later amendments or comparable ethical standards.

Accrual and historical records of 2990 patients who were operated for appendicitis between 2015-2020 were analyzed. The age range of all patients was between 14-85. The mean age of all patients was  $32.66 \pm 11.73$ . Of the patients, 1011 were women (33.88%) and 1979 were men (66.12%). The mean age of female patients was  $34.75 \pm 12.64$ . 27 (2.67%) of the women patients were pregnant. The age range of pregnant patients was between 21-40. The mean age of the pregnant patients was 29 years. The age range of men patients was 14-85. The mean age of male patients was  $31.59 \pm 11.09$ .

Clinical follow-up experience of surgeons and experience of the radiologist in ultrasound evaluation, which is the primary imaging method in the diagnosis of appendicitis are very important. So we requested a blood test (WBC count) and an abdominal ultrasound for all our patients who came with the complaint of abdominal pain in the right lower quadrant. All patients underwent ultrasound examination first. In the ultrasound examination (Toshiba Aplio 300), the transverse diameter of the appendix, compressibility, inflammatory changes in the surrounding tissue, presence of intraluminal fecal plug, and perforation findings were examined.

We operated on 2689 of 2990 patients according to ultrasound results. We determined the pathological diagnoses with the measurement of the radiological and pathological diameter of the appendix. The difference between radiological and pathological diameters was evaluated with Paired *t*-test. We also calculated the difference in pathological and radiological diameters according to age groups with a One-Way Analysis of

Variance. The intraclass correlation coefficient was used to determine the compatibility of pathological and radiological measurements. We had abdominal computerized tomography (CT) (Siemens Somatom Emotion 16 eco) for 285 patients and abdominal magnetic resonance imaging (MRI) (Siemens Aera 1.5) for 27 of 16 pregnant women (59.25%) due to unclear clinical picture. 175 of the patients who underwent CT were men. The ratio of patients who could not be diagnosed with ultrasound and who requested CT for more detailed imaging was 9.6% of all men and nonpregnant patients. For all patients; we compared the radiological examination (radiological diameters) and WBC count with the pathological examination (pathological diagnosis and pathological diameter) of the patients we operated on.

## Statistical evaluation

In this study, statistical analyzes were performed with NCSS (Number Cruncher Statistical System) 2007 Statistical Software (Utah, USA) package program. In addition to descriptive statistical methods (mean, standard deviation, frequency, and percentage distributions) in the evaluation of the data, the distribution of the variables was examined with the Shapiro-Wilk normality test, paired *t*-test for time comparisons of normally distributed variables, one-way analysis of variance for comparisons between groups, Tukey for subgroup comparisons. multiple comparison test, independent *t*-test for comparison of paired groups, and Pearson correlation test was used to determine the relations of variables with each other. For the differential diagnosis of appendicitis groups, the areas under the ROC Curve were calculated. Sensitivity specificity, positive predictive value, negative predictive value and LR(+) values, and Radiological Diameter of Ap. and Pathological Diameter of Ap. The cut-off value was determined for the variables. The results were evaluated at the significance level of  $P < 0.05$ .

## RESULTS

All 2990 patients underwent ultrasound examination first. The leukocyte count above 11000 with a left shift in neutrophils was considered significant. Especially in patients diagnosed with plastron appendicitis, the leukocyte value was higher. A positive statistically significant correlation was observed between WBC values and pathological and radiological diameters of the appendix in gangrenous and acute appendicitis, respectively ( $r = 0.733$ ,  $P = 0.0001$ ,  $r = 0.824$ ,  $P = 0.0001$ ) ( $r = 0.730$ ,  $P = 0.0001$ ,  $r = 0.602$ ,  $P = 0.0001$ ) [Table 1]. The appendix diameter could not be measured in 12 patients whose perforation

findings were detected during ultrasound imaging. Of patients evaluated only by ultrasound examination 2067 of them were evaluated as histopathologically positive and 622 as negative appendectomy. In the remaining 2978 patients, the widest diameter of the appendix was measured between 7-20 mm [Figure 1]. According to age groups; <20 age, 21-30 age, 31-40 age, 41-50 age, 51-60 age, and >61 age groups there is no statistically significant difference was observed between the radiological and pathological diameter of the

**Table 1: Correlation of WBC values with pathological and radiological diameter measurements of appendix**

Pathologic diagnosis	Pathologic diameter(P) Radiologic diameter(r)	WBC
Gangrenous appendicitis	Pathological Diameter of Ap.	<i>r</i> 0,733
	Radiological Diameter of Ap.	<i>P</i> 0,0001
Acute Appendicitis	Pathological Diameter of Ap.	<i>r</i> 0,824
	Radiological Diameter of Ap.	<i>P</i> 0,0001
Lenfoid Hyperplasia	Pathological Diameter of Ap.	<i>r</i> 0,730
	Radiological Diameter of Ap.	<i>P</i> 0,0001
Fibrous obliteration	Pathological Diameter of Ap.	<i>r</i> 0,602
	Radiological Diameter of Ap.	<i>P</i> 0,0001
Fibrous obliteration	Pathological Diameter of Ap.	<i>r</i> 0,353
	Radiological Diameter of Ap.	<i>P</i> 0,0001
Fibrous obliteration	Pathological Diameter of Ap.	<i>r</i> 0,472
	Radiological Diameter of Ap.	<i>P</i> 0,0001
Fibrous obliteration	Pathological Diameter of Ap.	<i>r</i> 0,045
	Radiological Diameter of Ap.	<i>P</i> 0,382
Fibrous obliteration	Pathological Diameter of Ap.	<i>r</i> 0,519
	Radiological Diameter of Ap.	<i>P</i> 0,0001

Pearson Correlation test

**Table 2: Radiological and pathological diameter difference of appendix according to age**

	<i>n</i>	Radiological and Pathological Diameter Difference of Appendix
<20 Yaş	365	2,46±1,29
21-30 Yaş	1159	2,56±1,30
31-40 Yaş	820	2,59±1,27
41-50 Yaş	370	2,45±1,24
51-60 Yaş	169	2,64±1,39
>61 Yaş	94	2,49±1,24
<i>P</i>		0,335 <sup>†</sup>

<sup>†</sup>One-Way Analysis of Variance

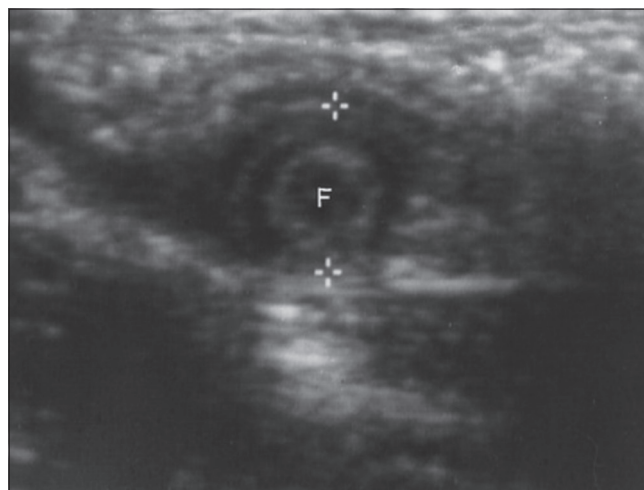
**Table 3: Pathological and radiological diameter of appendix**

	Pathological Diameter of Ap.	Radiological Diameter of Ap.	Difference	<i>P</i>
Gangrenous appendicitis	14,82±2,22	11,67±2,92	3,16±1,74	0,0001 <sup>†</sup>
Acute Appendicitis	13,00±2,29	11,62±2,47	1,38±2,39	0,0001 <sup>†</sup>
Lenfoid Hyperplasia	9,84±1,78	9,92±1,87	-0,09±2,49	0,576 <sup>†</sup>
Fibrous obliteration	8,81±1,37	9,59±1,78	-0,78±2,54	0,0001 <sup>†</sup>
Gangrenous + Acute appendicitis	13,34±2,39	11,63±2,56	1,71±2,38	0,0001 <sup>†</sup>
Lenfoid Hyperplasia + Fibrous obliteration	9,21±1,62	9,72±1,82	-0,51±2,49	0,0001 <sup>†</sup>
All Measurements	12,46±2,81	11,22±2,55	1,24±2,57	0,0001 <sup>†</sup>

<sup>†</sup>Paired *t* test

appendix. ( $P = 0.335$ ) [Table 2]. After the appendectomy was completed during the operation, the pathology specimen was removed from the *in vivo* environment and fixed with 10% buffered formalin in the *in vitro* environment within 5 minutes at least [Figure 2]. During the pathological examination, the widest transverse diameter of the material was measured between 7 mm to 20 mm. In 657 patients, the diameter of the appendix on ultrasound and pathology were not compatible with each other (24.43%). Pathologic diameter (PD) measured 4 to 7 mm diameter larger than the ultrasonic diameter (UD) in 435 of 657 patients, in the rest UD was larger than the pathological [Table 3].

Distribution of pathological diagnosis in groups; Plastrone Appendicitis 12 (0.40%), Gangrenous appendicitis 438 (14.65%), Acute Appendicitis 1906 (63.75%), Lymphoid Hyperplasia 249 (8.33%), and Fibrous obliteration 385 (%) 12.88) was found [Table 4]. The intraclass correlation coefficient was used to determine the agreement of pathological and radiological measurements. Intra-Class Correlation coefficient of Gangrenous appendicitis group 0.874 (0.848-0.896), Intra-Class Correlation coefficient for Acute Appendicitis 0.667 (0.636-0.696), Intra-Class Correlation



**Figure 1: Transverse diameter image of appendix on ultrasound**



coefficient of Gangrenous and Acute appendicitis 0.755 (0.675-0.793), Intra-Class Correlation coefficient for Lymphoid Hyperplasia 0.123 (0.126-0.316), Fibrous obliteration Intra-Class Correlation coefficient was -0.468 (-0.793--0.201), Lymphoid Hyperplasia + Fibrous obliteration Intra-Class Correlation coefficient was -0.088 (-0.272-0.069), Intra-Class Correlation coefficient of all measurement groups was 0.705 (0.680-0.725). The Intraclass Correlation coefficient of Gangrenous appendicitis, Acute Appendicitis, and Gangrenous + Acute appendicitis measurements were found above or close to the desired limit value of 0,700, and the Intraclass Correlation coefficient of all measurement groups was found to be above 0,700. Intraclass correlation coefficient of Lymphoid Hyperplasia, Fibrous obliteration, and Lymphoid Hyperplasia + Fibrous obliteration measurements was found

**Table 4: Distribution of pathological diagnosis**

Pathology result	Number of patients	Percentage
Acute appendicitis	1906	63.7%
Perforated appendicitis	12	0.4%
Gangrenous appendicitis	438	14.6%
Lenfoid hyperplasia	249	8.3%
Fibrous obliteration	385	12.9%
Total operated patients	2990	100%

**Table 5: Concordance of pathological and radiological measurements-Intraclass correlation coefficient**

	Intraclass Correlation coefficient 95% CI
Gangrenous appendicitis	0,874 (0,848-0,896)
Acute Appendicitis	0,667 (0,636-0,696)
Lenfoid Hyperplasia	0,123 (-0,126-0,316)
Fibrous obliteration	-0,468 (-0,793--0,201)
Gangrenous + Acute appendicitis	0,755 (0,675-0,793)
Lenfoid Hyperplasia + Fibrous obliteration	-0,088 (-0,272-0,069)
All Measurements	0,705 (0,680-0,725)

**Table 6: Radiological examination methods**

	USG		CT		MRI	
	n	%	n	%	n	%
Definitive Diagnosis	2067	69,1	249	87,3	12	75,0
Further Examination	301	10,1	25	8,7	3	18,8
Misdiagnosis	622	23	11	3,8	1	6,3

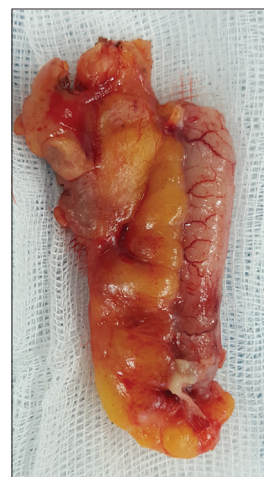**Table 7: The sensitivity and specificity of radiological and pathological diameter measurements**

Diameter of appendicitis	Pathological diagnosis	Cut Off	Sensitivity	Specificity	PPV	NPV	LR (+)
Radiological Diameter of Ap.	Acute Appendicitis	>10	52,57	81,39	89,5	46,3	2,82
	Gangrenous Appendicitis	>11	43,33	94,64	81,1	67,3	6,22
	All Appendicitis	>10	51,41	81,39	91,1	41,2	2,76
Pathological Diameter of Ap.	Acute Appendicitis	>11	85,88	80,28	92,9	65,4	4,36
	Gangrenous Appendicitis	>12	98,40	90,06	87,2	98,8	9,90
	All Appendicitis	>11	88,52	80,28	94,3	65,4	4,49

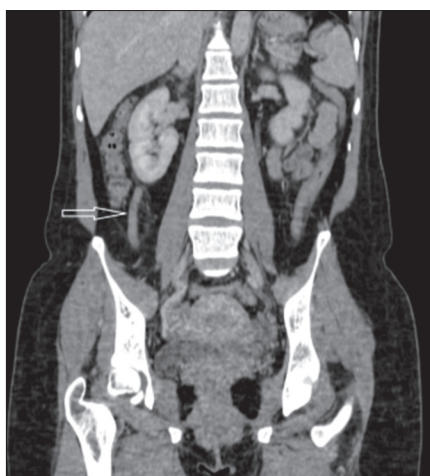
below the desired limit value of 0.700. Measurements were more successful in appendicitis groups [Table 5].

In Gangrenous and Acute appendicitis groups, the pathological diameter of the appendix was found to be statistically significantly higher than the radiological diameter of the appendix ( $P = 0.0001$ ) [Table 3]. In all measurement groups, the mean pathological diameter of the appendix was statistically significantly higher than the mean diameter of the radiological diameter ( $P = 0.0001$ ) [Table 3].

A negative appendectomy rate with ultrasonic examination was performed in 622 patients with pathological diagnosis of lymphoid hyperplasia and fibrous obliteration (23%) [Table 6]. The pathology result was consistent with appendicitis in 2067 of the 2990 patients who have operated on with ultrasound alone. For the remaining 301 patients for whom a clear diagnosis could not be made by ultrasound, extra radiological imaging was planned because of clinical findings that did not regress. The accurate diagnosis rate of ultrasound in our 2990 patients was 69.1%. The success rate of ultrasonography in pregnant patients was 40.74% (11/27). The sensitivity and specificity of radiological and pathological diameter measurements are given in Table 7. In the measurements of patients diagnosed with acute appendicitis, the risk of acute appendicitis positivity in a person with an appendix



**Figure 2: Appendectomy material in vitro environment**



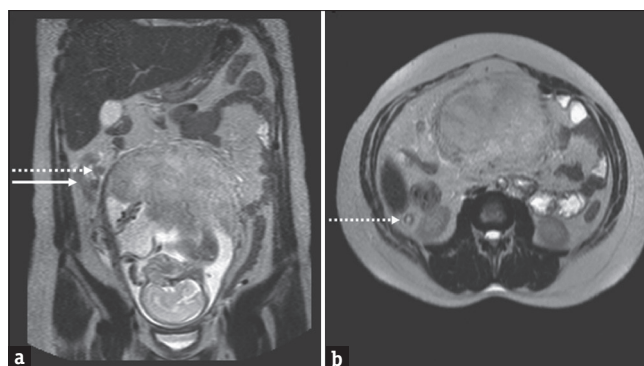
**Figure 3:** Appearance of the appendix, which has increased in diameter and causes inflammation in the surrounding fatty tissue, on abdominal CT (indicated by arrow)

**Table 8: Differential diagnosis of appendicitis groups- ROC Curve**

Pathology result	Diameter of appendix	AUC	SE	95%CI
Acute Appendicitis	Pathological Diameter of Ap.	0,908	0,006	0,896-0,919
	Radiological Diameter of Ap.	0,729	0,011	0,711-0,746
Gangrenous Appendicitis	Pathological Diameter of Ap.	0,983	0,004	0,974-0,990
	Radiological Diameter of Ap.	0,710	0,017	0,692-0,718
All Appendicitis	Pathological Diameter of Ap.	0,922	0,005	0,912-0,932
	Radiological Diameter of Ap.	0,721	0,010	0,705-0,737

diameter of  $>10$  mm is 2.82 times higher than in a person with a radiological diameter of  $<10$  mm with 52.57% sensitivity, 81.39% specificity, 89.5% PPV and 46.3% NPV [Table 7]. In gangrenous appendicitis measurements, sensitivity was 43.33%, specificity 94.64%, PPV 81.1%, and NPV 67.3% in patients with a radiological diameter of the appendix  $>11$  mm. That is, the diameter of the appendix is  $>11$  mm gangrenous appendicitis positivity is 6.22 times higher than in someone with a radiological diameter of  $<11$  mm [Table 7].

If the pathological diameter is  $>11$  mm in patients with acute appendicitis, it has 85.88% sensitivity, 80.28% specificity, 92.9% PPV, and 65.4% NPV in the diagnosis of acute appendicitis. In other words, if the pathological diameter is  $>11$  mm, the risk of acute appendicitis is 4.36 times higher than the person with a pathological diameter of  $<11$  mm. In all appendicitis groups, if the pathological diameter of the appendix was  $>10$  mm, the sensitivity was 88.52, the specificity was 80.28, the positive predictive value was 94.3, the negative



**Figure 4:** An inflamed appendix with increased diameter in T2 weighted coronal (a) and axial (b) images of MRI

predictive value was 65.4, and the LR (+) value was 4.49. In other words, the risk of appendicitis positivity in someone with a pathological diameter of  $>10$  mm is 4.49 times higher than in someone with a pathological diameter of  $<10$  mm.

In the differential diagnosis of all patients with appendicitis, the area of the pathological diameter of the appendix under the ROC curve was 0.922 (0.912-0.932), and the area related to radiological diameter was 0.721 (0.705-0.737). These values are above the desired 0.700 limit value [Table 8].

We had abdominal CT with intravenous contrast agent application for 285 patients due to insufficient diagnosis because of atypical signs of appendicitis. Definitive diagnosis could not be made in 36 of 285 patients (12.6%) because of the inability to detect periappendicular inflammation with appendicular luminal collapse. Therefore, patients underwent diagnostic laparoscopy. During operation, the diameter of the appendix was increased but there was no inflammation of the periappendicular tissue. Pathologic results of 25 patients were compatible with acute appendicitis [Figure 3]. PD of the appendix in the rest of the 11 patients measured 8 mm with a pathologic diagnosis of lymphoid hyperplasia with a negative appendectomy rate of 3.8%. The sensitivity of CT imaging was 90%, with a PPV of 95% [Table 6].

Non-contrast abdominal MRI was performed on 16 pregnant patients with ongoing abdominal pain. MRI is at least as sensitive and specific as CT [Figure 4]. During pregnancy, appendicitis may progress with an atypical clinical course, so in cases where ultrasound is insufficient, MRI is the second preferred imaging method in pregnant women.<sup>[3]</sup> Although MRI was performed, 4 of 16 pregnant patients could not be diagnosed (25%). Diagnostic laparoscopy was performed on 4 patients who could not be diagnosed. Appendectomy was performed. The preoperative diagnosis could not be clarified due

to anatomical changes resulting from pregnancy. The pathology result of 1 patient who underwent MRI was not compatible with appendicitis (1/16-6,25%). This may be due to non-contrast imaging. The sensitivity of MRI imaging was 80% with a 92% PPV [Table 6].

## DISCUSSION

Acute appendicitis is the most common disease-causing right lower quadrant pain in the abdomen. Approximately 7-12% of the general population is affected by this disease every year. However, some of the patients who underwent appendectomy were found to be negative, that is, unnecessary. Negative appendectomy rate, normal uninflamed appendix histopathologically, varies between 20-40% in the literature.<sup>[4]</sup> It may result in serious complications in the postoperative period.<sup>[5]</sup> Therefore, other diseases that may cause right lower quadrant abdominal pain should be excluded. Can appendicitis be diagnosed 100% with developing imaging techniques? Abdominal ultrasound along with clinical examination and lab tests are the first steps to be performed in those with suspected appendicitis. Raised WBC is not 100% specific or sensitive in patients suspected of appendicitis.<sup>[6]</sup> Ultrasonography is an imaging method different from CT and MRI, due to dependence on the experience of the radiologist. The ultrasound image of the normal appendix is in the form of a peristaltic tubular structure. Its normal diameter is smaller than 6 mm. It can be compressed when pressure is applied with the ultrasound probe. Findings in favor of appendicitis are the diameter of the appendix of more than 6 mm, thickening of the cecum and terminal ileum wall, increased perfusion in the appendix wall, and presence of free pericecal fluid during ultrasound imaging.<sup>[4]</sup> But the accuracy of ultrasound is inversely proportional to intestinal gas and peritoneal irritation. In pregnant women, the success rate of ultrasound in diagnosing is limited only in the third trimester due to anatomical changes.<sup>[3]</sup> In cases with suspected appendicitis, ultrasound has a sensitivity of 97.3% and a specificity of 91%. Our definitive diagnosis rate in ultrasonography based on histopathological examination was 69.1%. The success rate of ultrasonography in pregnant patients was 40.74% (11/27). Pathology results of 435 patients whose PD was measured larger than the UD were also compatible with appendicitis. Wrong measurement may have been caused by intestinal gas, anatomic position (retrocecal position), obesity, or inexperience of the radiologist. In 97 of 222 patients whose PD was measured less than UD, the pathology was compatible with acute appendicitis. After the pathology pieces are fixed with 10% buffered formalin, they shrink rather than absorb the liquid.

The biggest disadvantage of ultrasound in patients with pathological diagnosis of acute appendicitis is its inability to image (34-71%).<sup>[6]</sup> Yu *et al.*<sup>[7]</sup> calculated the rate of negative appendectomy as 10% in patients who underwent only ultrasonography. The most important reasons for the primary limitation of the ultrasound method are its dependence on the user's imaging ability, experience, and the patient's anatomical structure.<sup>[8]</sup>

Early diagnosis is very important in appendicitis. The longer the time between the onset of complaints and the diagnosis, the higher the risk of perforation. As a result morbidity and mortality will also increase secondary to this delay.<sup>[9,10]</sup> The correct diagnosis should be our top priority. At the same time, it is necessary to avoid negative appendectomy, which can cause complications such as wound infection, abscess, hospital-acquired infection, and fistula. The negative appendectomy rate reported as 15-25% can be reduced more with improved radiological imaging to prevent postoperative complications.<sup>[11]</sup>

We operated on 12 patients for appendiceal perforation with a delay of 48 hours, because they showed atypical clinical course. The most important factors in our decision to have the surgery were the leukocyte count that did not decrease and the ongoing abdominal pain of the patients. A clear assessment could not be made on ultrasound examination. The proportion of cases diagnosed with appendicitis during surgery and also found to be incompatible with preoperative assessment has been reported between 12-40% in the literature.<sup>[7]</sup> Our negative appendectomy rate was 21.2%. Because of this CT and other imaging systems have been developed to decrease unnecessary surgical intervention.

CT should be preferred in atypical cases where ultrasound is limited. A diameter of appendix greater than 6 mm, appendix wall thicker than 3 mm, inflammation of the adjacent adipose tissue, having an abscess in the appendix lodge, the presence of appendicolith, maximum depth of intraluminal appendiceal fluid >2.6 mm, and presence or absence of adjacent adenopathy are the diagnostic criteria for appendicitis on CT.<sup>[12]</sup>

Overall sensitivity and specificity for CT are 94% and 98% respectively.<sup>[12]</sup> Although it is the best diagnostic method a definitive diagnosis could not be made in 36 of 285 patients (12.6%) because of the inability to detect periappendicular inflammation with appendicular luminal collapse.<sup>[12]</sup> The diagnostic laparoscopy was planned for these 36 patients because of increasing leukocyte count and also worsening of the clinical picture of 7 of 36 patients over 60 years of age with co-morbidities. In 25 of 36 patients, the pathology result was compatible



with acute appendicitis. The remaining 11 patients were histopathologically negative with a diagnosis of lymphoid hyperplasia. In order not to miss the inflamed appendix during diagnostic laparoscopy, we could not decide that the appearance of the appendix was healthy. Because of that, we did appendectomy to all our patients during diagnostic laparoscopy. CT is the gold standard method in appendicitis, but the preoperative assessment rate of CT in our patients was 87% with a negative appendectomy rate of 3.8%.

In the UK, the diagnostic accuracy rate in patients operated on without preoperative imaging is between 76-80%<sup>[13,14]</sup> This corresponds to a 20% negative appendectomy rate. Ultrasonography and CT are used routinely.<sup>[15,16]</sup> 232 patients were included in the study. 69 of these patients had CT performed preoperatively (29.74%). The sensitivity, specificity, and positive and negative predictive values of CT were 77.8%, 100%, 87.5%, and 100%, respectively. The rate of negative appendectomy in patients with CT was 7.25%, while it was 22.09% in patients without CT. If CT was performed in all patients in the preoperative period, the rate of negative appendectomy would have decreased by 15%. In two studies, in which patient selection was more reliable with the use of CT in the preoperative period, it was found that the negative appendectomy rate decreased from 19% to 5% and from 13% to 7%, respectively.<sup>[14,17]</sup>

MRI is the second diagnostic method in pregnant patients who cannot be concluded with ultrasound.<sup>[18]</sup> The probability of ultrasound not being able to visualize acute appendicitis in pregnant patients ranges from 34 to 71%.<sup>[19]</sup> In these patients, MRI is the gold standard method with 100% specificity and 89% sensitivity.<sup>[18]</sup> Criteria of appendicitis on MR imaging; diameter of appendix >6 mm, appendix wall thickness >2 mm, the lumen of appendix filled with fluid, edema, free fluid or abscess formation in the surrounding tissue.<sup>[18]</sup> In our 12 pregnant patients, radiological and pathological diagnoses were compatible with each other (true positive). Diagnostic laparoscopy was performed on 4 patients who could not be diagnosed with MRI. Although 3 patients were radiologically normal, pathologically compatible with appendicitis (false negative). In one patient, the diagnosis was normal. According to these results, our MRI sensitivity in our patients was 80%. Our negative appendectomy rate in our patients who underwent MRI radiological imaging was 6.3%.

Appendicitis is both the most common non-obstetric surgical emergency and pediatric emergency. It affects 2.1 of 1000 pregnant women and 23.3% of the 10-19

age group.<sup>[10,17]</sup> Progress in radiological imaging leads to a decrease in the negative appendectomy rate.<sup>[20]</sup> The negative appendectomy rate decreases with the use of CT and MRI rather than ultrasound.<sup>[21]</sup>

What is the ratio of error at the increasing rate with the advancement of both imaging techniques and surgeons' experience? We know that a definitive diagnosis of appendicitis is made by histopathologic examination. Diversity in clinical decision-making among surgeons, the presentation of patients with atypical clinical findings, and the experience of radiologists who evaluate radiological imaging, especially ultrasound, are the most important factors affecting diagnostic accuracy. If we evaluate to answer this question on our behalf on false positive and true negative patients, we performed unnecessary appendectomy in 21,2% of the patients. Because of this every patient diagnosed with appendicitis should not be operated on.

Radiological imaging is a very important method that leads us to a definitive diagnosis among differential diagnoses. Our hope is that the developments in radiological imaging, combined with clinical experience, will reduce or even reset the negative appendectomy rate.

### Ethics approval

All procedures performed in studies involving human participants were in accordance with the ethical standards of the institutional and/or national research committee and with the 1964 Helsinki Declaration and its later amendments or comparable ethical standards. The study was approved by the Bioethics Committee of the Medical University of Health Sciences University, İstanbul Kanuni Sultan Suleyman Training and Research Hospital, General Surgery Clinic, İstanbul/Turkey (No. 2021.01.234)

### Financial support and sponsorship

Nil.

### Conflicts of interest

There are no conflicts of interest.

### REFERENCES

1. Espejo OJA, Mejla MEM, Guerrero LHU. Acute appendicitis: Imaging findings and current approach to diagnostic images. *Rev Colomb Radiol* 2014;25:3877-88.
2. Hoxha I, Duraj B, Xharra S, Avdaj A, Begiri V, Grezda K, et al. Clinical decision-making for appendectomy in Kosovo: A conjoint analysis. *Int J Environ Res Public Health* 2022;19:14027.
3. Franca Neto AH, Amorim MM, Nobrega BN. Acute appendicitis in pregnancy: Literature review. *Rev Assoc Med Bras* 2015;61:170-7.
4. Brown MA. Imaging acute appendicitis. *Semin Ultrasound CT MR* 2008;5:293-307.
5. Ambe PC. Negative appendectomy. It is really preventable? *J Invest Surg* 2019;5:474-5.

6. Mostbeck G, Adam E, Nielsen M, Claudon M, Clevert D, Nicolau C, *et al.* How to diagnose acute appendicitis: Ultrasound first. *Insights Imaging* 2016;2:255-63.
7. Yu SH, Kim CB, Park JW, Kim MS, Radosevich DM. Ultrasonography in the diagnosis of appendicitis: Evaluation by meta-analysis. *Korean J Radiol* 2005;4:267-77.
8. Heverhagen JT, Pfestroff K, Heverhagen AE, Klose KJ, Kessler K, Sitter H. Diagnostic accuracy of magnetic resonance imaging: A prospective evaluation of patients with suspected appendicitis (diamond). *J Magn Reson Imaging* 2012;3:617-23.
9. Baird DLH, Simillis C, Kontovounisios C, Rasheed S, Tekkis PP. Acute appendicitis. *BMJ* 2017;357:j1703.
10. Snyder MJ, Guthrie M, Cagle S. Acute appendicitis: Efficient diagnosis and management. *Am Fam Physician* 2018;98:25-33.
11. Cahn J, Fan KS, Mak TLA, Loh SY, Ng SWY, Adapala R. Pre-operative imaging can reduce negative appendectomy rate in acute appendicitis. *Ulster Med J* 2020;89:25-8.
12. Moteki T, Horikoshi H. New CT criterion for acute appendicitis: Maximum depth of intraluminal appendiceal fluid. *Am J Radiol* 2007;188:1313-9.
13. Stephenson J, Al-Nowfal A, Khatiwada AS, Lim Z, Norwood M, Verma R. Can imaging have a beneficial effect on reducing negative appendectomy rates. *Clin Radiol* 2018;73(Suppl 1):e21.
14. Boonstra PA, van Veen RN, Stockmann, HB. Less negative appendectomies due to imaging in patients with suspected appendicitis. *Surg Endosc* 2015;8:2365-70.
15. D'Souza N, Marsden M, Bottomley S, Nagarajah N, Scutt F, Toh S. Cost-effectiveness of routine imaging of suspected appendicitis. *Ann R Coll Surg Engl* 2018;1:47-51.
16. Lahaye MJ, Lambregts DM, Mutsaers E, Essers BA, Breukink S, Cappendijk VC, *et al.* Mandatory imaging cuts costs and reduces the rate of unnecessary surgeries in the diagnostic work-up of patients suspected of having appendicitis. *Eur Radiol* 2015;5:1464-70.
17. Karakas SP, Guelfguat M, Leonidas JC, Springer S, Singh SP. Acute appendicitis in children: Comparison of clinical diagnosis with ultrasound and CT imaging. *Pediatr Radiol* 2000;2:94-8.
18. Spalluto LB, Woodfield CA, DeBenedictis CM, Lazarus E. MR imaging evaluation of abdominal pain during pregnancy: Appendicitis and other nonobstetric causes. *Radio-Graphics* 2012;2:317-34.
19. Segev L, Segev Y, Rayman S, Nissan A, Sadot E. The diagnostic performance of ultrasound for acute appendicitis in pregnant and young nonpregnant women: A case control study. *Int J Surg* 2016;34:81-5.
20. Kabir SA, Kabir SI, Sun R, Jafferhoy S, Karim A. How to diagnose an acutely inflamed appendix; a systematic review of the latest evidence. *Int J Surg* 2017;40:155-62.
21. Gelpke K, Hamminga JTH, van Bastelaar JJ, Vos B, Bodegom ME, Heineman E, *et al.* Reducing the negative appendectomy rate with the laparoscopic appendicitis score; multicenter prospective cohort and validation study. *Int J Surg* 2020;79:257-64.