

Evaluation Fetal Heart in the First and Second Trimester: Results and Limitations

TUK Dilek, A Oktay¹, EG Aygun¹, G Ünsal², Ö Pata³

Halic University School of Medicine, Department of Obstetrics and Gynecology, Istanbul, ¹Acibadem Bakirköy Hospital, Pediatric Cardiology Clinic, Istanbul, ²Acibadem Mehmet Ali Aydınlar University, Atakent Hospital, Obstetrics and Gynecology Clinic and IVF Unit, Istanbul, ³Acibadem Mehmet Ali Aydınlar University, School of Medicine, Department of Obstetrics and Gynecology, Istanbul, Turkey

ABSTRACT

Background: Cardiac heart defects affect nearly 6–12 per 1000 live births in the general population and are more frequent than common trisomies. **Aim:** To assess the efficacy and technical limitations of first-trimester fetal heart evaluation in the 11–14th-weeks' scan and comparison with the second-trimester anatomical exam by ultrasound. **Material and Method:** Between April 2015 and July 2020, medical records and ultrasound data of 3295 pregnancies who underwent first-trimester fetal anatomy exams by ultrasound were reviewed retrospectively. All ultrasound exams were performed by the same two operators (TUKD, OP) with transabdominal transducers. Fetal situs, four-chamber view, outflow tracts, and three-vessel trachea view are the cornerstones of first-trimester fetal heart examination. Conventional grayscale mode and high-definition power Doppler mode were utilized. The same operators re-examined all cases between the 18 and 23 weeks of gestation by ISUOG guidelines. **Results:** We performed a combined transvaginal and transabdominal approach for only 101 cases (3.06%). The mean maternal age was 31.28 ± 4.43 , the median gestational age at the first-trimester ultrasound exam was 12.4 weeks, and the median CRL was 61.87 mm (range was 45.1–84 mm). Even combined approach situs, cardiac axis, and four-chamber view could not be visualized optimally in 28 cases (0.7%). Outflow tracts were visualized separately in 80% (2636 in 3295) cases. Three vessel-trachea views were obtained in 85.4% (2814 in 3295) cases by high-definition Doppler mode. There were 47 fetuses with cardiac defects in 3295 pregnancies with the known pregnancy outcome. Ten cases had abnormal karyotype results. Thirty-two fetuses with cardiac anomalies (9.7 in 1000 pregnancies) were detected in the first-trimester examination, and the remaining 15 (4.55 in 1000 pregnancies) cases were diagnosed in the second-trimester examination. The prevalence of congenital cardiac anomalies was 14.25 in 1000 pregnancies. Fifteen cases were missed in the first-trimester exam. Also, ten fetuses which had abnormal cardiac findings in the first-trimester exam were not confirmed in the second-trimester exam. Sensitivity, specificity, positive, and negative predictive values were calculated as 65.3%, 99.7%, 66.8%, and 99.67%, respectively. **Conclusion:** Late first-trimester examination of the fetus is feasible and allows earlier detection of many structural abnormalities of the fetus, including congenital heart defects. Suspicious and isolated cardiac abnormal findings should be re-examined and confirmed in the

Received:
01-Nov-2022;
Revision:
06-Mar-2023;
Accepted:
03-May-2023;
Published:
14-Jul-2023

Address for correspondence: Prof. TUK Dilek,
Department of Obstetrics and Gynecology, Topkapı, Istanbul,
Turkey.
E-mail: umutdilek@gmail.com

This is an open access journal, and articles are distributed under the terms of the Creative Commons Attribution-NonCommercial-ShareAlike 4.0 License, which allows others to remix, tweak, and build upon the work non-commercially, as long as appropriate credit is given and the new creations are licensed under the identical terms.

For reprints contact: WKHLRPMedknow_reprints@wolterskluwer.com

How to cite this article: Dilek TUK, Oktay A, Aygun EG, Ünsal G, Pata Ö. Evaluation fetal heart in the first and second trimester: Results and limitations. Niger J Clin Pract 2023;26:787-94.

Access this article online

Quick Response Code:



Website: www.njcponline.com

DOI: 10.4103/njcp.njcp_757_22

second-trimester exam. Previous abdominal surgery, high BMI, and subtle cardiac defects can cause missed cardiac abnormalities.

KEYWORDS: *Cardiac anatomy, fetal heart, first-trimester exam, high-definition Doppler, second-trimester exam*

INTRODUCTION

Examining the fetus by ultrasound is integral to routine fetal health assessment. Significant fetal structural anomalies complicate 2–3% of all pregnancies.^[1,2] Cardiac heart defects affect nearly 6–12 per 1000 live births in the general population and are more frequent than autosomal trisomies. Fifty percent of significant cardiac anomalies require corrective and palliative surgery in the postnatal period.^[3] Early detection of cardiac anomalies provides early information, including etiology, prognosis, availability of prenatal and postnatal interventions about these problems, and the opportunity for early genetic diagnosis. Mid-trimester anatomical examination of the fetus has been the standard for detecting fetal cardiac anomalies since the early 90s. The prenatal detection rate of major CHD (Cardiac heart defects) was reported as 47.2%–77% at the second-trimester exam between 18 and 23 weeks.^[4] Delaying the anatomic exam to the second trimester may cause late detection of several significant structural anomalies. Reported prenatal detection of structural defects, including cardiac anomalies, varies^[5] and depends on the operator's experience, maternal body mass index, gestation age at the exam, ultrasound equipment and specific organs being examined, and anomalies that later onset.^[6,7] First-trimester examination of the fetal anatomy gained popularity in the last two decades following the use of ultrasound as an essential part of the first-trimester aneuploidy screening. Increased nuchal translucency (NT), abnormal ductus venous flow, and tricuspid regurgitation may help to screen and diagnose fetal cardiac anomalies with variable degrees of sensitivity and specificity.^[8–11] It is now estimated that a detailed and systematic examination of fetal anatomy in the first trimester could provide a nearly 50% detection rate of all major anomalies. Overall detection rates depend on risk stratification, such as low or high risk, gestational age at diagnosis, technical issues, specific organ system being evaluated, and operator experience.^[12] The overall detection rate was reported between 46.1 and 76.1% for the diagnosis of fetal anomalies in the first-trimester examination.

Despite the small size of the fetal heart in the first trimester, a routine exam could detect 48% of cardiac anomalies in the first-trimester exam.^[13] Determination of situs, four-chamber view, outflow tracts, and three-vessel trachea view are cornerstones of first-trimester cardiac examination by ultrasound.^[14,15] The detection rate was

increased with advancing gestational age, combined transvaginal and transabdominal approach, presence of multiple congenital anomalies, and in the high-risk group.^[16] However, the majority of pregnant women are not familiar with transvaginal ultrasound to examine the embryo and fetus in pregnancy due to the fear of the harmful effect of the transvaginal ultrasound probe. Before the 12th week of gestation, high transvaginal frequency provides better imaging performance.^[17] However, early examination, high maternal BMI, surgical scars over the lower abdominal wall, and uterine fibroids could adversely affect and decrease the detection rate of cardiac abnormalities.^[12,18] This study aims to assess the efficacy and technical limitations of first-trimester fetal heart evaluation in the 11–14th-week scan and report our follow-up data.

MATERIALS AND METHODS

This retrospective study was conducted in the Acibadem Mehmet Ali Aydinlar University Atakent Hospital and Acibadem Bakirkoy Hospital Prenatal Diagnosis Units between April 2015 and December 2019. It was approved by the local ethics committee of Acibadem Mehmet Ali Aydinlar University (Registration Number: 2020-06/8). The study group consisted of patients referred for the first-trimester aneuploidy screening and first-trimester anomaly survey. In addition, 3295 cases had follow-up data, including second-trimester examination and pregnancy follow-up data. Cases who have no second-trimester examination, in-utero demise, higher order multiple pregnancies, and loss from the pregnancy follow-up exams were excluded from the study. We performed the first-trimester exam by ultrasound between the 11th and 14th weeks of gestation (CRL 45 mm–84 mm). In addition, maternal characteristics were recorded as a first examination step (Medical history, body mass index, mean arterial pressure). All first and second-trimester exams were performed by two maternal-fetal medicine specialists (TUKD, OP) using General Electric (General Electric, Chicago, IL, USA) Voluson E8 Expert (Equipped with RMC-6 or C1-5 D Convex probe) and E10 (Equipped with C4-8 convex probe).

The RIC6-12 transvaginal probe was used in the selected cases for the transvaginal exam. All ultrasound examinations were performed supine and with an empty bladder. The average total examination time for the first-trimester examination was 40 minutes (including

NT, nasal bone, ductus venosus and tricuspid regurgitation, fetal anatomy, uterine artery Doppler). In cases of inappropriate fetal position during the 30-minute examination period, the examination was stopped and repeated following the 1-hour break. In the midsagittal position, the transducer was rotated 90-degree clockwise or counterclockwise to obtain a transverse section for the apical four-chamber view. The region of interest was magnified to fill 70% of the screen. The scan area was narrowed to 20–30 degrees for a better frame rate, and the tissue harmonic was adjusted to the middle.

Fetal situs, axis, four-chamber view, two equally filled atria, and ventricles were visualized by both grayscale and HD-flow Doppler exam [Figure 1a and 1b]. Grayscale and high-definition flow power Doppler assessed outflow tracts and three-vessel trachea view [Figure 2a and 2b]. Also, excellent vessel crossing and forward flow in both the aorta and ductus arteriosus were confirmed [Figure 3]. Pulse repetition frequency (PRF) was 2.4–3.2 kHz for high-definition flow power Doppler. To follow ALARA principles, ultrasound acoustic output was adjusted to yield a thermal index (TI) value below 0.5 in the study area. Fetal cardiac examination (in the full anatomy scan) was repeated between the 18 and 23 weeks of gestation by ISUOG guidelines.^[19] In case of cardiac anomaly suspicion or abnormal cardiac examination findings,

fetal echocardiography was done by an experienced pediatric cardiologist with expertise in fetal cardiology. Also, follow-up exams and postnatal echocardiography were performed for the ascertained cardiac anomaly. We suggested an invasive genetic diagnostic procedure after detailed genetic and prognostic counseling by a medical genetics specialist, pediatric cardiologist, and maternal-fetal medicine specialist. Termination of pregnancy was offered in case of co-existed multiple structural anomalies, cardiac anomalies incompatible with life, and cardiac anomalies which co-existed with aneuploidies and structural chromosomal aberrations.

Statistical analysis

We carried out our statistical analysis using MedCalc statistical analysis software version 12.3. The Kolmogorov–Smirnov test was used to assess the distribution of variables. Descriptive statistics, the sensitivity, specificity, and positive and negative predictive values were calculated for the first-trimester ultrasound to discriminate between normal and abnormal hearts. $P < 0.05$ was considered statistically significant.

RESULTS

The medical records of 3295 cases who underwent first-trimester aneuploidy screening and with inclusion criteria were reviewed. Ultrasound examinations were

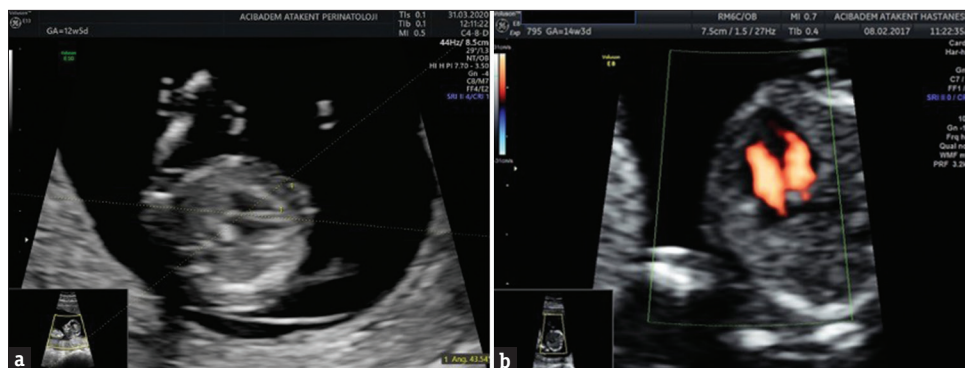


Figure 1: (a) Cardiac axis, 4-chamber view, (b) Two equal size and filled atria and ventricles were visualized by HD-flow Doppler exam.

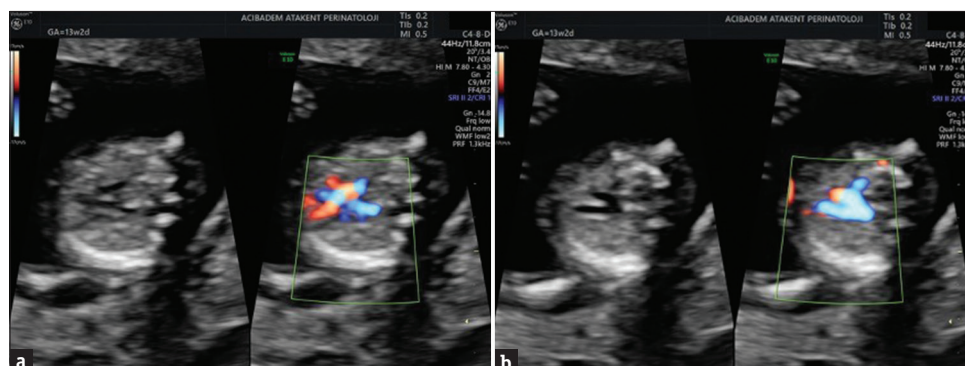


Figure 2: (a) Outflow tracts, (b) Three-vessel trachea views were assessed by HD-flow Doppler exam

Table 1: Clinical features of the fetuses with cardiac defects which were diagnosed in the first-trimester exam

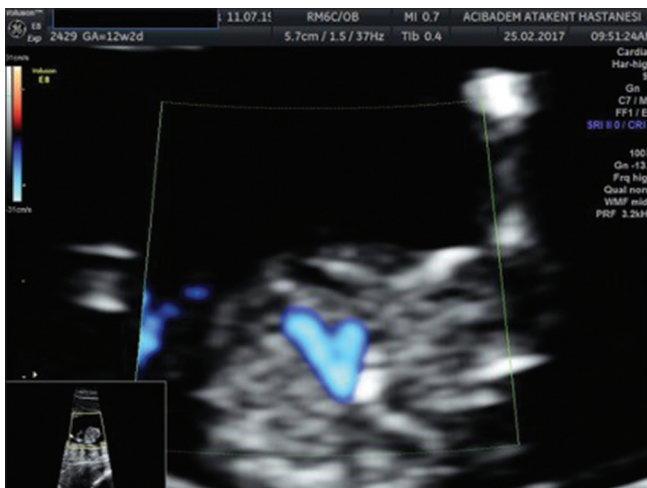Case	CRL (mm)	NT (mm)	First-Trimester Ultrasound Features	Karyotype	Second-Trimester Ultrasound Features	Outcome
1	70	1,2	Asymmetric growth restriction, VSD, posterior fossa cyst	Triploidy	None	TOP
2	62,8	2,7	Hypoplastic left heart, VSD, left axis deviation	None	Confirmed	Term delivery
3	54,1	3,1	AVSD	Trisomy 21	None	TOP
4	65	2,1	Hypoplastic left heart, VSD	None	None	TOP
5	46	4,7	Co-twin, AVSD, Maxillary gap, cleft lip, and plate	Normal karyotype (Other twin pair)	None	Selective feticide
6	53,21	2,53	Co-twin, DORV	Normal karyotype	None	Selective feticide
7	54	7,5	Co-twin, TGA and VSD, left axis deviation	Normal karyotype	Confirmed, corrected transposition	Preterm delivery
8	52,4	1,24	Hypoplastic right heart	None	None	TOP
9	57	3,5	AVSD	Trisomy 21	None	TOP
10	49	3,9	AVSD	Trisomy 21	None	TOP
11	55	3,6	Single umbilical artery, ASD, pyelectasis	t (17;25) unbalanced translocation	None	TOP
12	50	3,8	AVSD	None	None	TOP
13	52,5	6	VSD, hyperechogenic kidneys	Trisomy 9	None	TOP
14	60	2,53	AVSD, unilateral pes equinovarus	None	None	TOP
15	63,31	7,5	Hypoplastic left heart, VSD	None	None	TOP
16	60	5	Hypoplastic left heart, VSD	None	None	TOP
17	59	1,6	Nasal bone hypoplasia, VSD	Normal karyotype	Confirmed	In-utero ex
18	56	5,7	VSD	None	None	TOP
19	59,5	8,9	VSD	None	None	Postnatal ex
20	45	2,49	Omphalocele, VSD, holoprosencephaly	Regretted	None	TOP
21	47	2,65	Omphalocele, VSD	Trisomy 18	None	TOP
22	68	2,7	Hypoplastic left heart, hypertelorism, posterior fossa cyst	Triploidy	None	TOP
23	72,12	4,94	Tetralogy of Fallot	Normal Karyotype	Confirmed	Term Delivery
24	54,7	3,5	overriding aorta, VSD, small right ventricle, micrognathia	Regretted	None	TOP
25	68,92	1,21	Hypoplastic left heart	Regretted	None	TOP
26	79,9	2,5	VSD, TGA, left axis deviation	Regretted	Confirmed	Term delivery
27	76,2	1,7	VSD	Regretted	Confirmed	Term Delivery
28	62,9	5,86	AVSD	Regretted	None	TOP
29	64,8	1,21	AVSD	Regretted	DORV and AVSD	TOP
30	60,3	7,8	AVSD, Cystic Hygroma	Regretted	None	TOP
31	65,9	2,4	VSD	Regretted	Confirmed	Term Delivery
32	59	1,5	Single ventricle	Regretted	None	TOP

performed by transabdominal technique, a combined transabdominal and transvaginal approach required for only 101 cases (3.06%). The mean maternal age was 31.28 ± 4.43 , the median gestational age at first-trimester ultrasound was 12.4 weeks, and the median CRL crown-rump length was 61.87 mm (range was 45.1–84 mm). Median maternal BMI was 24.325 kg/m² (range: 18–51.76 kg/m²). 90% of cases are conceived spontaneously. The four-chamber view was acquired in 99.3% (3267 of 3295). Outflow tracts were visualized separately in 80% (2636 in 3295) cases. Three vessel-trachea views were obtained in 85.4% (2814 in 3295) cases by

high-definition Doppler mode. Even combined approach situs, cardiac axis, and four-chamber view could not be visualized optimally in 28 cases (0.7%). Two-thirds of pregnancies with suboptimal cardiac examination have high BMI. In this group, the median CRL was 61.8 mm. There were 47 fetuses with cardiac defects in 3295 pregnancies (1.42%) with the known pregnancy outcome. Ten cases had abnormal karyotype results. Thirty-two fetuses with cardiac anomalies (9.7 in 1000 pregnancies) were detected in the first-trimester examination [Table 1], and the remaining 15 (4.55 in 1000 pregnancies) cases were diagnosed in the second-trimester

Table 2: Clinical features of the fetuses with cardiac defects which were diagnosed in the second-trimester exam

Case	CRL(mm)	NT(mm)	First-Trimester Ultrasound Features	Karyotype	Second-Trimester Ultrasound Features	Outcome	Risk Factor
1	69,3	1,8	Could not determined	None	Hypoplastic left heart and aortic stenosis	TOP	High BMI, previous abdominal surgery
2	60	2,12	Left axis, normal four-chamber view, and outflow tracts	Trisomy 21	Nasal bone hypoplasia, AVSD (in the second-trimester exam)	TOP	None
3	77,2	2,1	Left axis, normal four-chamber view, and outflow tracts could not evaluated	None	TGA	Term delivery	Previous abdominal surgery
4	55,9	1,2	Left axis, normal four-chamber view, and outflow tracts	None	Muscular VSD, ARSA (second-trimester diagnosis)	Term delivery	None
5	67,4	1,6	Left axis, normal four-chamber view, and outflow tracts	None	Outlet VSD	Term delivery	None
6	66	1,4	Left axis, normal four-chamber view, and outflow tracts	None	Muscular VSD	Term delivery	None
7	68	1,5	Left axis, normal four-chamber view, and outflow tracts	None	Outlet VSD	Term delivery	None
8	65	1,5	Left axis, normal four-chamber view, and outflow tracts	None	Muscular VSD	Term delivery	None
9	77,1	1,94	Left axis, normal four-chamber view, and outflow tracts	None	Outlet VSD	Term delivery	High BMI, regular LMWH use
10	58,8	1,18	Left axis, normal four-chamber view, and outflow tracts	None	Outlet VSD	Term delivery	None
11	67,4	1,56	Left axis, normal four-chamber view, and outflow tracts	None	Muscular VSD	Term delivery	High BMI
12	73	1,8	Left axis, normal four-chamber view	None	Azygos vein continuation	Term delivery	None
13	66	1,77	Left axis, normal four-chamber view, and outflow tracts	None	Outlet VSD	Term delivery	None
14	66,7	1,71	Left axis, normal four-chamber view, and outflow tracts	None	Aortic coarctation	Term delivery	None
15	62,5	1,48	Left axis, normal four-chamber view, and outflow tracts	None	Aortic coarctation	Term delivery	None

**Figure 3:** The great vessel crossing and forward flow in the both aorta and ductus arteriosus was assessed

examination [Table 2]. Median NT values of fetuses with cardiac anomalies were 3.1 mm (range: 1.2 mm–8.9 mm), and median CRL was 60 mm (range: 46–79.9 mm). Nineteen of 32 had increased NT > 95

percentile (59.3%). The prognosis was good for fetuses with isolated cardiac defects. Six cases were delivered at term as live birth, and one (twin pair with corrected transposition of great arteries) was delivered as planned preterm delivery. In-utero death occurred in a case with VSD (Ventricular septal defect) and normal karyotype at 33 weeks of gestation. A neonate with a hypoplastic left heart and another with VSD plus fetal akinesia deformation syndrome died postnatally. Also, 23 cases diagnosed in the first-trimester exam underwent termination of pregnancy because of co-existed multiple anomalies or aneuploidies. Following the comprehensive anatomic exam and invasive genetic diagnosis of the other twin pairs, we performed selective feticide for the discordant cardiac anomalies of two twin pairs.

Fifteen cases were missed in the first-trimester exam. Details of the first- and second-trimester cardiac exam and risk factors for the unsatisfactory cardiac exam are shown in Tables 1 and 2. Only four cases had risk factors for the unsatisfactory cardiac exam in the

first-trimester exam, such as high BMI and previous abdominal surgery. Eleven missed cases had subtle cardiac ultrasound findings to diagnose cardiac defects in the first-trimester exam [Table 2]. The median CRL and NT cases diagnosed in the second trimester were 66.7 mm and 1.6 mm, respectively.

Three TGA cases and two aortic coarctation cases underwent corrective surgery in the early neonatal period. Neonatal mortality occurred in a case with TGA following the arterial switch operation. Also, another baby with a hypoplastic left heart was lost in the early neonatal period during the preoperative preparation for the first step of the Norwood procedure.

Ten fetuses with abnormal cardiac findings (Especially septal defects) in the first-trimester exam were not confirmed in the second-trimester exam. Therefore, sensitivity, specificity, positive and negative predictive values were calculated as 65.3%, 99.7%, 66.8%, and 99.67%, respectively.

DISCUSSION

First-trimester screening of common aneuploidies provided an excellent opportunity for early screening and evaluation of fetal structural abnormalities.^[18] Hyett *et al.*^[20] reported that most fetuses with increased NT had heart and significant vessel abnormalities. Even higher NT values in euploid fetuses are associated with a higher risk of CHD. Between 2.5 mm and 3.4 mm, the incidence was 6.0 of every 1000 pregnancies. NT > 3.5 mm, the incidence was 1 of 43 pregnancies.^[21] Nineteen of 32 had increased NT > 95 percentile (59.3%). Duta *et al.*^[22] reported that 40% of fetuses with CHD had increased NT.

Increased NT, absence of A wave in the ductus venosus, and regurgitation of the tricuspid valve were warning signs for possible congenital heart disease (CHD) even in euploid fetuses.^[23] Minnella *et al.*^[24] reported that fetal NT \geq 95th or \geq 99th percentile, tricuspid regurgitation or abnormal ductus venosus flow was observed in 36.5%, 21.3%, 28.9%, and 27.5% fetuses with a significant heart defect, respectively, and in 6.1%, 0.9%, 1.2%, and 1.8% of those without a heart defect. These signs require further evaluation of the fetus for the co-existed CHD. Since the late nineties, many studies have been conducted for the evaluation of fetal heart in both low-risk and high-risk groups. Between the 11th and 13th weeks of gestation, transvaginal or combined transvaginal and transabdominal techniques are preferred to examine the fetal heart.^[25] However, the transvaginal technique may be better before the 12th week of gestation.^[17]

The success rate of transabdominal examination increased from 45% at 11 weeks to 90% after the 13th week of

gestation. Huggon *et al.*^[26] obtained satisfactory images in the first-trimester cardiac exam in 84.1% (402/478) of fetuses by transabdominal technique. In this study, the median CRL was 60.3 mm. The transvaginal approach was only required in 7.3% of cases after the 13th week of gestation.^[27] Our transvaginal exam rate was similar between the 11th and 14th weeks of pregnancy. In our study, the transvaginal exam was only required in patients with high BMI, a history of previous lower abdominal surgery, and before the 12th week of gestation.

Operator experience, high-quality equipment, patient's conditions (higher BMI, history of previous abdominal surgery), and gestational age at exam could affect the diagnosis rate. The type of CHD could influence the rate of diagnosis. High-frequency transducers provide better imaging resolution for fetal heart evaluation.^[28] This study's median CRL and BMI were 61.87 mm and 24.3 kg/m², respectively. Higher BMI and lower CRL could adversely affect the success of the transabdominal approach.^[29] Even without color-flow mapping or high-definition Doppler flow, transvaginal examination overcomes this technical handicap in the higher BMI group. In a recent study, by transvaginal technique, visualization of a four-chamber view was achieved in 89.4% and outflow tracts in 82.4%. Otherwise, visualization of four-chamber and outflow tracts were 77.8% and 61.5%, respectively, with transabdominal transducers.^[29] Visualization of the fetal cardiac axis and four chambers were achieved in all cases in our study. Although the visualization of three-vessel and outflow tracts was 85.4% and 80%, respectively, these visualization rates were better than Fernandez's study because of the combined use of grayscale and high-flow definition Doppler techniques. We utilized high-definition Doppler mode to define outflow tracts successfully. Visualization rates for each view increased with fetal growth; we did not stratify examination time weekly. However, Ebrashy *et al.* reported^[30] that the success rate of obtaining fetal cardiac exam planes were 87.4%, 72.6%, 47%, and 27.4% for four-chamber view, pulmonary trunk, three-vessel view, and long axis aorta respectively at 11th week of gestation. Visualization rates increase, such as 99.3%, 97%, 97.3%, and 94.2%, respectively, at the 13th week of gestation. Because of this, they suggest the best time to perform a fetal heart examination during the first trimester is between 13 and 13 weeks plus six days.^[30] Similar visualization rates were reported by studies of Dolkart, Gembruch, and Haak in the 13th week and later.^[31-33] Lower visualization rates for the three-vessel view, and each outflow tract depends on relatively earlier examination time in our study. Nemescu *et al.*^[34] stated that the LVOT (left ventricular outflow tract) was visualized in 87.4% of cases, and the ability to visualize the LVOT was correlated with the sonographer's

experience and was inversely correlated with the transducer-heart distance. Although the three-vessel and trachea view was visualized in 78.2% of fetuses. The length of the heart examination and the sonographer's experience could influence the ability to visualize the three-vessel and trachea view. It was inversely correlated with the anterior placenta and an improper fetal position.

Determination of fetal cardiac situs and axis is possible in the late first trimester and early second trimester.^[35] Sinkovskaya *et al.*^[36] reported that 74.1% of fetuses with CHD in the first trimester had abnormal cardiac axis. While there was left axis deviation in 81.6% of fetuses with conotruncal lesions, NT was above the 95th percentile in 31.6% of these fetuses with cardiac axis deviation.

Minnella *et al.*^[20] reported that the diagnosis rate is higher for CHD, which affects four-chamber views such as hypoplastic heart and atrioventricular septal defect. Evaluation of the fetal heart in the first trimester could be challenging and influenced mainly by the smaller size of the fetus and the cardiac structures. Discordant findings and false-positive diagnoses of CHD on early cardiac exams were reported. Volpe *et al.*^[37] reported that 36 cases had abnormal findings on both examinations, and the remaining 32 had discordant findings, such as a false-positive and false-negative diagnosis. In this study, we could not confirm congenital heart anomalies of ten cases in the second-trimester exam. The majority of misdiagnoses were septal defects.

Duta *et al.*^[22] stated that the sensitivity of the first-trimester ultrasound to identify major CHD was 76.92%. We reported 65.3% sensitivity for identifying major cardiac defects. Nearly one-third of cardiac defects (15 of 47 cases) was diagnosed in the second-trimester exam. Some malformations may become evident later in pregnancy, such as coarctation of the aorta, small VSDs, partial pulmonary venous return abnormalities, and aortic arch anomalies with ARSA (aberrant right subclavian artery), aortic, and pulmonary stenosis. However, minor, isolated CHDs usually have little long-term consequences for the developing child.

The safety of the first-trimester cardiac examination is another concern. As a form of energy, sound waves have the potential to cause bioeffects by tissue heating and cavitation. Ultrasound machines must display the TI and mechanical index (MI) on the screen during the examination as a criterion of the likelihood of ultrasound-induced bioeffects. Lower energy output from the transducer could be possible for a safer and more satisfactory fetal heart examination. Sande *et al.*^[38] reported that reliable first-trimester Doppler data and

measurements could be obtained by keeping the TI value between 0.5 and 1. When a TI value is less than 0.5, lower acoustic output acquires satisfactory Doppler images and signals to measure flow indices.^[39]

In this retrospective study, data from the mixed population (low- and high-risk patients) is the main limitation. Also, postmortem examination data were unavailable in most abnormal cases who underwent termination of pregnancy to define all details of cardiac abnormality—standardized technique and availability of follow-up data until the delivery was robust features of this study.

CONCLUSION

Early first-trimester examination of the fetus is feasible and allows earlier detection of many structural abnormalities, including congenital heart defects. However, heart defects can be diagnosed in the first trimester; some may develop and become evident only in later gestational weeks. By the transabdominal technique, well-trained fetal medicine specialists or obstetricians can do fetal heart examinations between the 12th and 14th weeks of gestation. Previous abdominal surgery, high BMI, and subtle cardiac defects can cause overlooked ones. Isolated septal defects can be diagnosed at later gestational weeks or misdiagnosed in the first trimester because they should be confirmed or excluded in the mid-trimester exam.

Ethical committee number

Acibadem Mehmet Ali Aydinlar University School of Medicine Ethics Committee number: (Registration Number: 2020-06/8).

Financial support and sponsorship

Nil.

Conflicts of interest

There are no conflicts of interest.

REFERENCES

1. Crane JP, LeFevre ML, Winborn RC, Evans JK, Ewigman BG, Bain RP, *et al.* A randomized trial of prenatal ultrasonographic screening: Impact on the detection, management, and outcome of anomalous fetuses. The RADIUS Study Group. *Am J Obstet Gynecol* 1994;171:392-9.
2. Grandjean H, Larroque D, Levi S. The performance of routine ultrasonographic screening of pregnancies in the Eurofetus Study. *Am J Obstet Gynecol* 1999;181:446-54.
3. Yun SW. Congenital heart disease in the newborn requiring early intervention. *Korean J Pediatr* 2011;54:183-91.
4. Jørgensen DE, Vejstrup N, Jørgensen C, Maroun LL, Steensberg J, Hesselund A, *et al.* Prenatal detection of congenital heart disease in a low risk population undergoing first and second trimester screening. *Prenat Diagn* 2015;35:325-30.
5. Tegnander E, Williams W, Johansen OJ, Blaas HG, Eik-Nes SH. Prenatal detection of heart defects in a non-selected population of 30,149 fetuses—detection rates and outcome. *Ultrasound*

- Obstet Gynecol 2006;27:252-65.
6. Tegnander E, Eik-Nes SH. The examiner's ultrasound experience has a significant impact on the detection rate of congenital heart defects at the second-trimester fetal examination. *Ultrasound Obstet Gynecol* 2006;28:8-14.
 7. van Nisselrooij AEL, Teunissen AKK, Clur SA, Rozendaal L, Pajkrt E, Linskens IH, *et al.* Why are congenital heart defects being missed? *Ultrasound Obstet Gynecol* 2020;55:747-57.
 8. Clur SA, Ottenkamp J, Bilardo CM. The nuchal translucency and the fetal heart: A literature review. *Prenat Diagn* 2009;29:739-48.
 9. Chelemen T, Syngelaki A, Maiz N, Allan L, Nicolaides KH. Contribution of ductus venosus Doppler in first-trimester screening for major cardiac defects. *Fetal Diagn Ther* 2011;29:127-34.
 10. Pereira S, Ganapathy R, Syngelaki A, Maiz N, Nicolaides KH. Contribution of fetal tricuspid regurgitation in first-trimester screening for major cardiac defects. *Obstet Gynecol* 2011;117:1384-91.
 11. Volpe P, Ubaldo P, Volpe N, Campobasso G, De Robertis V, Tempesta A, *et al.* Fetal cardiac evaluation at 11-14 weeks by experienced obstetricians in a low-risk population. *Prenat Diagn* 2011;31:1054-61.
 12. Karim JN, Roberts NW, Salomon LJ, Papageorgiou AT. Systematic review of first-trimester ultrasound screening for detection of fetal structural anomalies and factors that affect screening performance. *Ultrasound Obstet Gynecol* 2017;50:429-41.
 13. Rossi AC, Prefumo F. Accuracy of ultrasonography at 11-14 weeks of gestation for detection of fetal structural anomalies: A systematic review. *Obstet Gynecol* 2013;122:1160-7.
 14. Salamon LJ, Alfirevic Z, Bilardo CM, Chalouhi GE, Ghi T, Kagan KO, *et al.* ISUOG practice guidelines: Performance of first trimester fetal ultrasound scan. *Ultrasound Obstet Gynecol* 2013;41:102-13.
 15. Chaoui R, Abuhamad A. *Fetal Echocardiography*. New York: Wolters Kluwer Press; 2015.
 16. Syngelaki A, Hammami A, Bower S, Zidere V, Akolekar R, Nicolaides KH. Kin first-trimester fetuses with increased nuchal translucency: Ultrasound diagnosis and postmortem morphology. *Ultrasound Obstet Gynecol* 2002;20:14-21.
 17. Vimpelli T, Huhtala H, Acharya G. Fetal echocardiography during routine first-trimester screening: A feasibility study in an unselected population. *Prenat Diagn* 2006; 26:475-82.
 18. Syngelaki A, Chelemen T, Dagklis T, Allan L, Nicolaides KH. Challenges in the diagnosis of fetal non-chromosomal abnormalities at 11-13 weeks. *Prenat Diagn* 2011; 31:90-102.
 19. Carvalho JS, Allan LD, Chaoui R, Copel JA, DeVore GR, Hecher K, *et al.* ISUOG practice guidelines (updated): sonographic screening examination of the fetal heart. *Ultrasound Obstet Gynecol* 2013; 41: 348-59.
 20. Hyett J, Moscoso G, Papapanagiotou G, Perdu M, Nicolaides KH. Abnormalities of the heart and great arteries in chromosomally normal fetuses with increased nuchal translucency thickness at 11-13 weeks of gestation. *Ultrasound Obstet Gynecol* 1996;7:245-50.
 21. Bahado-Singh RO, Wapner R, Thom E, Zachary J, Platt L, Mahoney MJ, *et al.* First Trimester Maternal Serum Biochemistry and Fetal Nuchal Translucency Screening Study Group. Elevated first-trimester nuchal translucency increases the risk of congenital heart defects. *Am J Obstet Gynecol* 2005; 192:1357-61.
 22. Duta S, Veduta A, Vayna AM, Panaitescu A, Nedelea F, Peltecu G. The outcome of structural heart defects diagnosed in the first trimester of pregnancy. *J Matern Fetal Neonatal Med* 2021; 34: 1389-94.
 23. Haak MC, Bartelings MM, Gittenberger-De Groot AC, Van Vugt JM. Cardiac malformations in first-trimester fetuses with increased nuchal translucency: ultrasound diagnosis and postmortem morphology. *Ultrasound Obstet Gynecol* 2002; 20:14-21.
 24. Minnella GP, Crupano FM, Syngelaki A, Zidere V, Akolekar R, Nicolaides KH. Diagnosis of major heart defects by routine first-trimester ultrasound examination: Association with increased nuchal translucency, tricuspid regurgitation and abnormal flow in ductus venosus. *Ultrasound Obstet Gynecol* 2020;55:637-44.
 25. Smrcek JM, Berg C, Geipel A, Fimmers R, Diedrich K, Gembruch U. Early fetal echocardiography: Heart biometry and visualization of cardiac structures between 10 and 15 weeks' gestation. *J Ultrasound Med* 2006;25:173-82.
 26. Huggon IC, Ghi T, Cook AC, Zosmer N, Allan LD, Nicolaides KH. Fetal cardiac abnormalities identified prior to 14 weeks' gestation. *Ultrasound Obstet Gynecol* 2002;20:22-9.
 27. Volpe P, Ubaldo P, Volpe N, Campobasso G, De Robertis V, Tempesta A, *et al.* Fetal cardiac evaluation at 11-14 weeks by experienced obstetricians in a low-risk population. *Prenat Diagn* 2011;31:1054-61.
 28. Persico N, Moratalla J, Lombardi CM, Zidere V, Allan L, Nicolaides KH. Fetal echocardiography at 11-13 weeks by transabdominal high-frequency ultrasound. *Ultrasound Obstet Gynecol* 2011;37:296-301.
 29. García Fernández S, Arenas Ramirez J, Otero Chouza MT, Rodríguez-Vijande Alonso B, Llanaza Coto AP. Early fetal ultrasound screening for major congenital heart defects without Doppler. *Eur J Obstet Gynecol Reprod Biol* 2019;233:93-7.
 30. Ebrashy A, Aboulghar M, Elhodiby M, El-Dessouky SH, Elsirgany S, Gaafar HM, *et al.* Fetal heart examination at the time of 13 weeks scan: A 5 years' prospective study. *J Perinat Med* 2019;47:871-8.
 31. Dolkart LA, Reimers FT. Transvaginal fetal echocardiography in early pregnancy: Normative data. *Am J Obstet Gynecol* 1991;165:688-91.
 32. Gembruch U, Shi C, Smrcek JM. Biometry of the fetal heart between 10 and 17 weeks of gestation. *Fetal Diagn Ther* 2000;15:20-31.
 33. Haak MC, Twisk JW, Van Vugt JM. How successful is fetal echocardiographic examination in the first trimester of pregnancy? *Ultrasound Obstet Gynecol* 2002;20:9-13.
 34. Nemescu D, Onofriescu M. Factors affecting the feasibility of routine first-trimester fetal echocardiography. *J Ultrasound Med* 2015;34:161-6.
 35. Sinkovskaya E, Horton S, Berkley EM, Cooper JK, Indika S, Abuhamad A. Defining the fetal cardiac axis between 11 + 0 and 14 + 6 weeks of gestation: Experience with 100 consecutive pregnancies. *Ultrasound Obstet Gynecol* 2010;36:676-81.
 36. Sinkovskaya ES, Chaoui R, Karl K, Andreeva E, Zhuchenko L, Abuhamad AZ. Fetal cardiac axis and congenital heart defects in early gestation. *Obstet Gynecol* 2015;125:453-60.
 37. Volpe P, De Robertis V, Campobasso G, Tempesta A, Volpe G, Rembouskos G. Diagnosis of congenital heart disease by early and second-trimester fetal echocardiography. *J Ultrasound Med* 2012;31:563-8.
 38. Sande RK, Matre K, Eide GE, Kiserud T. Ultrasound safety in early pregnancy: Reduced energy setting does not compromise obstetric Doppler measurements. *Ultrasound Obstet Gynecol* 2012;39:438-43.
 39. Nemescu D, Berescu A. Acoustic output measured by thermal and mechanical indices during fetal echocardiography at the time of the first trimester scan. *Ultrasound Med Biol* 2015;41:35-9.