

Case Report

Rupture of a Non Sinus of Valsalva Aneurysm during Pregnancy: Case Report and Review of Literatures

TT Huang, JG Shan¹, JH Lin

Departments of Obstetrics and Gynecology, ¹Cardiovascular Surgery, Ren Ji Hospital, School of Medicine, Shanghai Jiao Tong University, Shanghai, China

Received:

17-Jul-2022;

Revision:

25-Jan-2023;

Accepted:

01-Feb-2023;

Published:

27-Feb-2023

ABSTRACT

Ruptured Sinus of Valsalva aneurysms during pregnancy is rare and presents a threat both to the mother and the fetus. We report a case of ruptured nonsinus of Valsalva aneurysms in a 26-year-old woman diagnosed at 32⁺⁴ weeks of gestation. A successful elective lower-segment cesarean section was conducted under general anesthesia. A successful surgical correction of the ruptured aneurysm under cardiopulmonary bypass (CPB) was performed with patch repair after 13 days. A multidisciplinary approach with respect to the pregnant patient's diagnosis, indications, and timing of surgery is necessary in ensuring the best possible outcomes for both the mother and the child.

KEYWORDS: Case report, multidisciplinary approach, pregnancy, sinus of Valsalva aneurysms, surgical correction

INTRODUCTION

Sinus of Valsalva aneurysm (SVA) is a rare congenital heart disease. Once ruptured, it can quickly deteriorate to heart failure and death. Few cases of ruptured SVA in pregnancy are reported. In all cases, the goal is to minimize both maternal and fetal risk. Therefore, treatment of ruptured SVA for a pregnant patient remains a clinical challenge. Here, we report a case of ruptured nonsinus of Valsalva aneurysm in a 26-year-old woman diagnosed at 32⁺⁴ weeks of gestation in Shanghai, China.

CASE REPORT

In April 2020, a 26-year-old Chinese pregnant woman was admitted to our hospital for chest tightness and palpitation for 9 days at 32⁺⁴ weeks of gestation. Followed 3 days later the chest tightness and palpitations worsened and she could not lie down at night. On physical examination, vital signs were heart rate 119 beats/min, respiratory rate 22 breaths/min, blood pressure 131/74 mm Hg, and oxygen saturation by pulse oximetry 98% on room air. Palpation of the precordium revealed the presence of a prominent systolic and diastolic thrill. Auscultation of the heart was notable for the presence

of a loud, harsh grade 4/6 continuous murmur that was audible throughout the precordium. Mild edema of both lower limbs. Obstetric examination showed abdominal distension. The brain natriuretic peptide (BNP) was 878 pg/ml (normal value 0-100 pg/ml), liver function showed that alanine aminotransferase 242 U/L (normal value 0-75 U/L), aspartate aminotransferase 51 U/L (normal value 10-28 U/L), albumin 27 g/L (normal value 34-54 g/L). A 12-lead electrocardiogram showed sinus tachycardia at a rate of 119 beats/min with no evidence of right-heart strain. Echocardiography showed nonsinus of Valsalva aneurysm ruptured into the right atrium, left atrium, and right heart were enlarged, mild tricuspid regurgitation and a small amount of pericardial effusion [Figure 1]. Chest radiography showed cardiac enlargement and pulmonary plethora.

Continuous ECG and oxygen saturation monitoring were provided, the multidisciplinary team including

Address for correspondence: Prof. JH Lin, Department of Obstetrics and Gynecology, Ren Ji Hospital, School of Medicine, Shanghai Jiao Tong University, No. 160, Pujian Road, Pudong New District, Shanghai, China. E-mail: linjhuarj@126.com

This is an open access journal, and articles are distributed under the terms of the Creative Commons Attribution-NonCommercial-ShareAlike 4.0 License, which allows others to remix, tweak, and build upon the work non-commercially, as long as appropriate credit is given and the new creations are licensed under the identical terms.

For reprints contact: WKHLRPMedknow_reprints@wolterskluwer.com

How to cite this article: Huang TT, Shan JG, Lin JH. Rupture of a non sinus of Valsalva aneurysm during pregnancy: Case report and review of literatures. Niger J Clin Pract 2023;26:250-2.


Access this article online	
Quick Response Code: 	Website: www.njcponline.com
	DOI: 10.4103/njcp.njcp_468_22

Table 1: Literature examples with ruptured SVA during pregnancy

Authors Years	Year	Age	Gestational Age at found	Location	Surgical time	Pregnancy outcome
Salma Charfeddine, <i>et al.</i> ^[1]	2017	26	26 weeks	Right into RV	Postpartum	Csection
Gang Fang, <i>et al.</i> ^[2]	2017	27	37 weeks	right into RVOT	13 days Postpartum	Csection at 37+4 weeks
Gang Fang, <i>et al.</i> ^[2]	2017	22	36 weeks	right into RVOT	7 days Postpartum	Csection at 36+1 weeks
Xiangjuan Chen, <i>et al.</i> ^[3]	2016	26	18 weeks	right into RVOT	Fifty days after childbirth	Csection at full-term gestation
Gaurav Agrawal, <i>et al.</i> ^[4]	2015	25	26 weeks	right into RVOT	26 weeks	Csection near term
Talaulikar, <i>et al.</i> ^[5]	2012	26	34 weeks	right into RVOT	10 days Postpartum	Csection at 38 weeks
Josip Vincelj, <i>et al.</i> ^[6]	2005	34	7 days after delivery	right into RV	7 days after delivery	VD at full term
Mohan Pamulapati, <i>et al.</i> ^[7]	1991	26	4 th months	right into RA	4 th months	VD at full term
Nieca Goldberg, <i>et al.</i> ^[8]	1990	23	37 weeks	Left into RA	6 weeks after delivery	Csection at 37 weeks
T Cripps, <i>et al.</i> ^[9]	1987	22	37 weeks	right into RVOT	1 week after delivery	Csection at 37 weeks
Barnes. ^[10]	1968	27	Five months	right into RV	Two months Postpartum	VD at 7 months

RV=right ventricle; RVOT=right ventricular outflow tract; RA=right atrium; VD=vaginal delivery

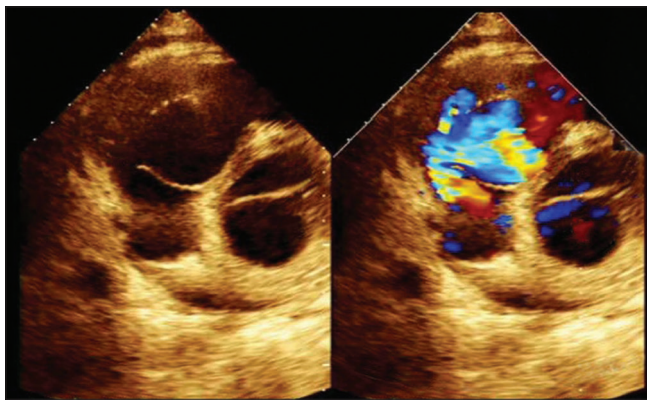


Figure 1: The results of the patient's echocardiographic examination (aortic sinus aneurysm broke into the right atrium)

cardiology, cardiovascular surgery, anesthesiology, obstetrics, and neonatology formulated treatment plans. After assessing the risk of surgery, low-flow oxygen inhalation, cardiotoxic and diuretics were provided. At the same time, dexamethasone was provided to promote fetal lung maturity. On the secondary day after admission, the patient received a cesarean section under general anesthesia. A healthy female infant weighing 2000g was delivered. The infant was transferred to the neonatal department for observation due to premature delivery. Uterine contraction is good and total bleeding was 200 ml during the operation. Cardiotoxic, diuretic, anti-infection, and liver-protective treatments are continued provided. Thirteen days after the cesarean section, repair of the ruptured sinus under cardiopulmonary bypass (CPB) was undertaken and an aneurysm was found. The noncoronary sinus of the Valsalva aneurysm with a size of 50*50 mm is located in the right atrium, and the rupture dimension is about 8 mm × 8 mm. She had no complications and was discharged from the hospital 8 days after the operation. Six months after surgery, there was no detectable evidence of residual cardiac shunt by echocardiography.

DISCUSSION

The Sinus of the Valsalva aneurysm is a very uncommon cardiac anomaly. Its incidence ranges from 0.1% to 3.5% of all congenital heart defects. So Pregnancy with a ruptured sinus of Valsalva aneurysm is a rare clinical disease. To the best of our knowledge, there are only ten case reports of ruptured sinus of Valsalva aneurysm found and treated during pregnancy [Table 1].^[1-10]

The most common symptoms are dyspnea, chest pain, and palpitations. Aneurysmal rupture can result in sudden death as a consequence of the acute onset of congestive heart failure, arrhythmia, cardiac tamponade, or ischemia. Transthoracic echocardiography is the preferred imaging method during pregnancy and can frequently establish the diagnosis and provide detailed information to the surgeon. When making imaging decisions during pregnancy, certain key points should be considered. Imaging procedures not associated with ionizing radiation are preferable and should be considered.

Management of RSVAs during pregnancy can be challenging. We think that the optimal time for surgical repair of ruptured SVA for pregnant women should be determined according to the specific condition of the individual patient. Early reports of CPB and valve replacement in pregnancy were associated with a 16%-33% fetal mortality rate. CPB can compromise uteroplacental perfusion and fetal development by potential adverse effects such as coagulation and blood component alterations, the release of vasoactive substances from leukocytes, complement activation, particulate and air embolism, non-pulsatile flow, hypothermia, and hypotension. Therefore, considering the safety of the fetus, it is best to avoid cardiac surgery in early pregnancy. If the patient's condition permits,

the heart surgery can be done after the 13th week of pregnancy. If a patient is critically ill or shows obvious symptoms associated with ruptured SVA such as heart failure, surgical intervention should be done immediately, then the pregnancy can be terminated. In the second trimester, the placenta and fetus form, the external teratogenic impact is small, and the uterus is relatively insensitive. Pregnancy can continue to full term after cardiac surgery. There have been relevant successful case reports in the world. In the third trimester, the uterine smooth muscle becomes more stressful, and surgical stimulation can easily cause premature delivery, a fetus can survive in the third trimester, so heart surgery combined with cesarean section can be selected. Patients were managed by a multidisciplinary team of obstetricians, cardiologists, and anesthesiologists. The operation is performed by the obstetrician first. If the patient is unstable and needs urgent heart surgery, considering that heparinization of the cardiopulmonary bypass may cause uncontrollable bleeding of uterine incision and placental dissection, uterine artery or internal iliac artery ligation can be done at the same time as cesarean section. If the patient's condition is stable, elective heart surgery after delivery should be considered to avoid postpartum hemorrhage. In our case, repair of the ruptured sinus was undertaken after 13 days postpartum to avoid postpartum hemorrhage that may be caused by systemic heparinization of cardiopulmonary bypass, and both the mother and child have a good outcome.

CONCLUSION

The rupture of the nonsinus of Valsalva aneurysm in a pregnant woman is unusual and presents a complex management situation. It is jointly managed by a multidisciplinary team including cardiovascular surgeons, obstetricians, anesthesiologists, cardiologists, and pediatricians. Choosing the correct time of cardiac surgery plays a decisive role in the safety of mothers and children.

Declaration of patient consent

The authors certify that they have obtained all appropriate patient consent forms. In the form the patient(s) has/have given his/her/their consent for his/her/their images and other clinical information to be reported in the journal. The patients understand that their names and initials will not be published and due efforts will be made to conceal their identity, but anonymity cannot be guaranteed.

Financial support and sponsorship

Nil.

Conflicts of interest

There are no conflicts of interest.

REFERENCES

1. Charfeddine S, Abid D, Triki F, Abid L, Kammoun S, Frikha I. Unusual case of ruptured sinus of Valsalva aneurysm in a pregnant woman. *Pan Afr Med J* 2017;27:271.
2. Fang G, Li M, Li J, Mei W. Anesthetic management of cesarean delivery in parturients with ruptured sinus of Valsalva aneurysm CARE-compliant 2 case reports and literature review. *Medicine (Baltimore)* 2017;96:e6833.
3. Chen X, Yang W, Zhang W, Zhu H. Normal pregnancy and birth despite ruptured sinus of Valsalva aneurysm: Another case for the record. *Tex Heart Inst J* 2016;43:158-60.
4. Agrawal G, Agarwal M, Chintala K. Transcatheter closure of ruptured sinus of Valsalva aneurysm in a pregnant woman. *J Cardiol Cases* 2015;12:183-7.
5. Talaulikar V, Verenkar S, Kamat A. Successful outcome of a rare case of ruptured sinus of Valsalva aneurysm in pregnancy. *J Obstet Gynaecol India* 2012;62:4-5.
6. Vincelj J, Starcevic B, Sokol I, Sutlic Z. Rupture of a right sinus of Valsalva aneurysm into the right ventricle during vaginal delivery: A case report. *Echocardiography* 2005;22:844-6.
7. Pamulapati M, Teague S, Stelzer P, Thadani U. Successful surgical repair of a ruptured aneurysm of the sinus of Valsalva in early pregnancy. *Ann Intern Med* 1991;115:880-2.
8. Goldberg N, Zisbrod Z, Kipperman R, Krasnow N, Gordon D, Shapir Y, *et al.* Congenital aneurysm of the left coronary sinus and left main coronary artery with fistulous communication to the right atrium in pregnancy. *J Am Soc Echocardiogr* 1990;3:125-30.
9. Cripps T, Pumphrey CW, Parker DJ. Rupture of the sinus of Valsalva during pregnancy. *Br Heart J* 1987;57:490-1.
10. Barnes RJ. Rupture of sinus of Valsalva. *Br Med J* 1968;1:683-4.