

## Case Report

# Coloboma of the Retina, Choroid and Iris Co-Existing with Cardiac & Skeletal Anomalies in a Male Nigerian: A Case of Noonan Syndrome

YO Babalola

Department of  
Ophthalmology, University  
of Ibadan/University College  
Hospital, Ibadan, Nigeria

**Received:**  
23-Sep-2021;  
**Revision:**  
04-Apr-2022;  
**Accepted:**  
10-Jun-2022;  
**Published:**  
16-Aug-2022

### ABSTRACT

A 19-year-old male undergraduate presented to the eye clinic with a history of poor vision in the left eye since childhood. The best-corrected visual acuity was 6/6 in the right eye and hand movement in the left eye respectively. Examination of the anterior segment of the right eye was essentially normal, whereas the anterior segment examination of the left eye revealed a small globe, microcornea, and an iris coloboma inferiorly at the 6 o'clock position. Binocular indirect ophthalmoscopy of the right eye revealed a pink disc, normal vessels and macula, lattice degeneration with retinal holes, and a flat retina. The left eye had a pink disc, normal macula and vessels with an inferior arc-shaped excavation with exposure of the sclera, which involved both the disc and macula and was in keeping with a retinochoroidal coloboma. Systemic examination revealed low-set ears with a left atrophic pinna, mild kyphoscoliosis, pectus excavatum, and an atrophic left lower limb with anomalies of the toes and talipes equinovarus. A pan-systolic murmur was present on cardiovascular examination.

**KEYWORDS:** *Cardiac anomaly, Noonan syndrome, ocular coloboma, skeletal abnormalities*

## INTRODUCTION

Ocular colobomata are malformations in ocular structures, which usually occur due to defective embryogenesis.<sup>[1]</sup> Colobomata typically occur in the inferonasal or inferior quadrant and may involve ocular structures like the iris, choroid, retina, and the optic nerve.<sup>[2]</sup> The occurrence of microphthalmia and anophthalmia has also been well-documented in colobomatous eyes.<sup>[1,3]</sup> These colobomata may occur in isolation or in association with different anomalies of the cardiac, skeletal, craniofacial, and urogenital systems, which are pathognomonic to previously defined syndromes. They may be inherited or genetic abnormalities as seen in Noonan syndrome, CHARGE syndrome, Baraister–Winter syndrome, Patau syndrome and Cat eye syndrome amongst others.<sup>[3,4]</sup>

Noonan syndrome (NS) is an autosomal dominant disorder with phenotypic variations. It is present in about 1:1,000 to 1:2,500 live births.<sup>[5]</sup> It is thought to be similar to Turner's syndrome but differs as the normal complement of human chromosomes is present in NS.

Multi-systemic affection includes cardiac anomalies, facial dysmorphism, skeletal and urogenital anomalies, and intellectual disability in some cases.<sup>[6]</sup> The first-ever report of ocular coloboma in Noonan syndrome was in a 21-year-old female with a right optic disc coloboma and a left inferior retinochoroidal coloboma.<sup>[7]</sup> An international study of diverse populations documented a 3-year-old male Nigerian with Noonan syndrome.<sup>[6]</sup> To the best of our knowledge, this is the second case of NS reported in a Nigerian patient.

## CASE REPORT

A 19-year-old male undergraduate presented at the retinal clinic with a history of poor vision in the left eye since childhood and a year history of difficulty seeing far associated with blurring of vision in the right eye.

**Address for correspondence:** Dr. YO Babalola,  
Department of Ophthalmology, University College Hospital,  
Ibadan, Nigeria.  
E-mail: [yewandeb@gmail.com](mailto:yewandeb@gmail.com)

This is an open access journal, and articles are distributed under the terms of the Creative Commons Attribution-NonCommercial-ShareAlike 4.0 License, which allows others to remix, tweak, and build upon the work non-commercially, as long as appropriate credit is given and the new creations are licensed under the identical terms.

**For reprints contact:** [WKHLRPMedknow\\_reprints@wolterskluwer.com](mailto:WKHLRPMedknow_reprints@wolterskluwer.com)

**How to cite this article:** Babalola YO. Coloboma of the retina, choroid and iris co-existing with cardiac & Skeletal anomalies in a male Nigerian: A case of noonan syndrome. *Niger J Clin Pract* 2022;25:1377-81.

### Access this article online

#### Quick Response Code:



**Website:** [www.njcponline.com](http://www.njcponline.com)

**DOI:** 10.4103/njcp.njcp\_1834\_21

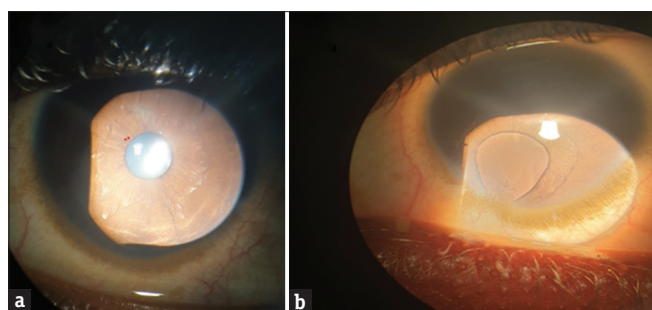
There was no antecedent history of trauma, flashes, floaters, excessive glare, haloes, or bumping into objects. A history of acute ocular symptoms like redness, foreign body sensation, and tearing was absent. He had never used spectacles. Past medical history was not significant.

The father gave a history of slightly delayed developmental milestones compared to the younger siblings. The pregnancy, birth, and neonatal history were essentially uneventful. He is the first of three children.

He consulted various hospitals in his early years due to limb deformities and spinal abnormalities, but not much was done then. The father gave a history of noticing a white spot in the left eye, which he also felt was smaller compared to the right eye. There was no history of hearing impairment, and the patient could communicate efficiently with good responses when asked questions during the consultation and clinical examination.

The patient gave a history of occasional episodes of regurgitation of food and heartburn. There was no history of problems with balance or other auditory symptoms. There was no history of consanguinity in the parents. The two younger siblings are healthy, and features present in our patient are absent in them.

Ocular examination revealed a best-corrected visual acuity of 6/6 in the right eye and hand movement with accurate light projection in the left eye. Best-corrected visual acuity in the right eye with refraction was 6/5 with a correction of plano/ - 1.50DC  $\times$  165°, whereas there was no improvement in the left. The right eyelids and anterior segment were essentially normal. The left eye appeared smaller than the right with pseudoptosis, a clear cornea which appeared smaller in diameter compared to the left, slight shallowing of the anterior chamber inferiorly with a key-shaped pupil due to an iris coloboma at 6 o'clock, and a clear lens *in situ* [Figure 1]. Intraocular pressure by Goldmann applanation tonometry was 12 and 10 mm Hg in the right and left eyes, respectively.



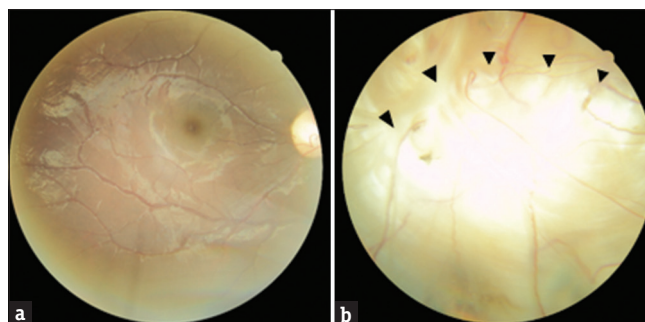
**Figure 1:** (a) shows the normal anterior segment of the right eye, whereas (b) shows the left iris coloboma peaked at 6 o'clock appearing as a key-hole-shaped pupil

Binocular indirect ophthalmoscopy of the right eye revealed a pink disc with a cup disc ratio of 0.3, normal vessels, and macula with lattice degeneration with holes in the superotemporal quadrant; the left fundus had an inferior retinochoroidal coloboma involving the lower portion of the disc and the whole of the macula [Figure 2]. There was no subretinal fluid around the lesion nor lifting of the intercalary membrane. The superior retina was flat, and there were no treatable peripheral retinal lesions. An ocular diagnosis of right lattice degeneration with holes and a left inferior retinochoroidal coloboma was made. He subsequently had a barrage laser for the lattice degeneration in the right eye.

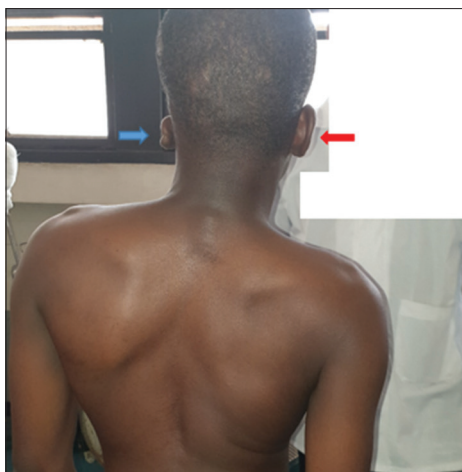The patient was noticed to have a limp with an abnormal gait as he walked into the consulting room which prompted a detailed clinical ocular and systemic examination and a subsequent extensive literature search as these features pointed to a syndromic etiology.

General examination showed a young man with short stature and a limp with an occipitofrontal circumference of 51.5 cm. He had bilateral low-set ears more pronounced in the left ear, which also had an abnormally shaped pinna. Facial features included a high frontal hairline, relatively sparse hair, a prominent forehead and glabella, broad nose, high-arched eyebrows, deep philtrum, prominent nasolabial folds, and a pointed chin [Figures 3 and 4]. Dental anomalies were absent, and he had no history of dental complaints in the past. His neck was short but not webbed. Pectus excavatum was also present [Figure 4].

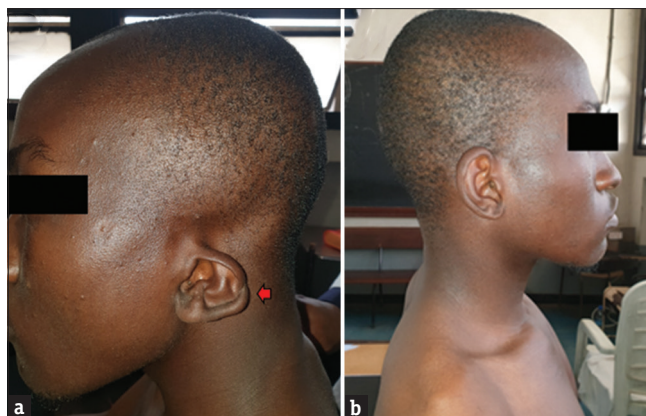The right lower limb was shortened, contracted at the knee joint, and atrophic with mild talipes equinovarus and abnormalities of the toes in keeping with camptodactyl as they were bent towards the sole of the foot. The left lower limb was normal except for the first digit which was slightly rotated temporally, whereas the third digit was hypertrophic and rotated posteriorly



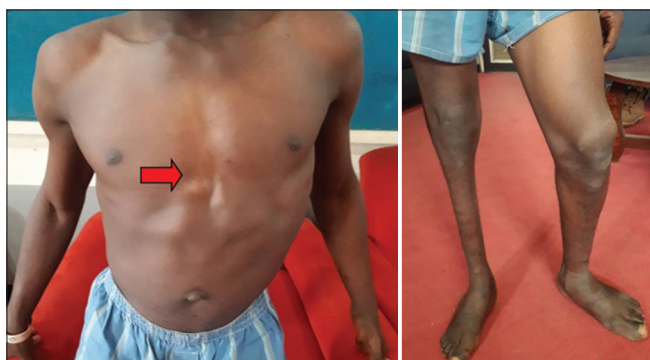**Figure 2:** (a) is the fundus photograph of the normal disc, macula, and flat retina in the right eye, whereas (b) is the fundus photograph of the left eye with a retinochoroidal coloboma involving the disc and macula. The black arrowheads indicate the upper border of the coloboma



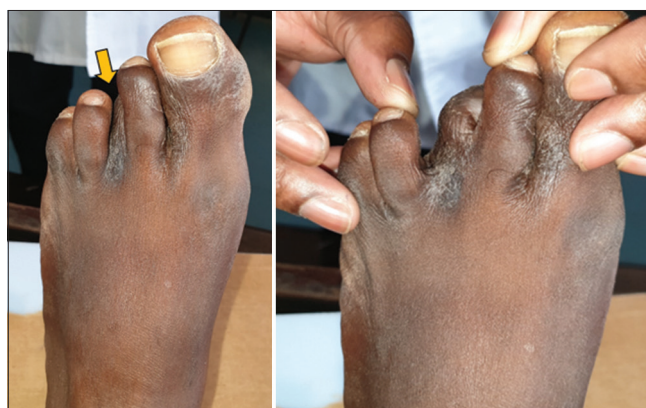**Figure 3:** Highlights the low-set ears with abnormal pinna on the left, a short neck, and a low posterior hairline



**Figure 4:** A shows a high-arched eyebrow, low set abnormal left pinna (red arrow) with thick helix and high anterior hairline and (b) shows high anterior hairline, low set normal pinna, short neck, and pointed chin



**Figure 5:** (a) shows the chest slightly rotated to the left, and the red arrow highlights pectus excavatum, and (b) shows the hypoplastic right lower limb and the normal left lower limb



**Figure 6:** Shows abnormally rotated second and third digit of the left foot indicated by the yellow arrow with areas of excoriations on the skin of the adjoining digits

beneath the second digit. The skin overlying the crevices of the first three toes was noticed to be hyperpigmented and scaly. His elbows and knees were also noticed to be slightly flexed [Figure 5].

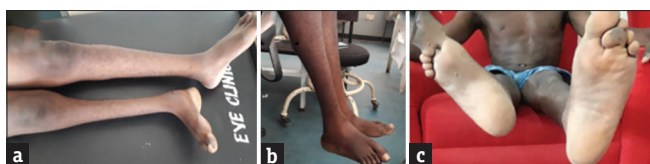Examination of the central nervous system was essentially normal; there was no cranial nerve deficit, there was normal power and tone in the left limb, and reduced muscle tone in the right lower limb. The respiratory rate was 22/min with vesicular breath sounds in both lung fields. On examination of the cardiovascular system, the pulse rate was 84 beats per min, regular, and of good volume, whereas the blood pressure was 130/80 mmHg. The first and second heart sounds were present with a pan-systolic murmur, but no thrill was felt. An electrocardiogram was ordered, which revealed an incomplete right bundle branch block, whereas subsequent echocardiography confirmed the presence of a ventricular septal defect. He was referred to the cardiology unit for subsequent review and management [Figures 6 and 7].

The abdomen was flat and moved with respiration with nil areas of tenderness nor palpable organomegaly.

Examination of the external genitalia revealed normal phallus and pubic hair patterns with both testes descending bilaterally in the scrotal sacs.

The importance of a magnetic resonance imaging of the brain and abdomino-pelvic ultrasound to rule out abnormalities in the brain and deformities in the urogenital system, respectively, was explained to the patient and his father but these investigations had not been carried out as at the last clinic review. The need for a review by the Otorhinolaryngology unit was also discussed with the patient and his father. The patient was of the opinion that he had no systemic issues and was not worried about the other anomalies except for the poor vision in the left eye.

Considering the clinical features, both ocular and systemic features, a diagnosis of presumed Noonan syndrome to rule out Baraister–Winter syndrome was made. Genetic testing nor digital facial analysis technology/ facial recognition technology was available for definitive genetic diagnosis; hence, the diagnosis



**Figure 7:** The hypoplastic right limb and left lower limb in (a and c), and right tallipes equinovarus and camptodactyl in the left foot are visible in (c)

was based on the clinical features noticed on clinical evaluation. He was referred to the cardiology unit for expert review and management in view of the ventricular septal defect. The patient was subsequently lost to follow-up.

## DISCUSSION

This patient presented to the eye clinic with complaints of poor vision in the left eye since childhood, and an ophthalmic examination subsequently revealed a left small globe with iris and retinochoroidal colobomas involving the disc. The significant finding in the right eye was lattice degeneration with holes in the superotemporal quadrant for which he subsequently had a right barrage laser. A detailed systemic examination and an extensive literature search were prompted by his abnormal gait as he walked into the consulting room and the unusual facial features. These in addition to the iris and retinochoroidal colobomas tended towards a syndromic entity associated with ocular colobomas. These prompted a detailed literature search as to the underlying diagnosis of this patient.

Various ophthalmologic manifestations of Noonan Syndrome have been described and these include epicanthic folds, prominent corneal nerves, stromal dystrophies, cataracts, optic nerve head drusen, hypoplasia, colobomas, and myelinated nerve fibres.<sup>[8]</sup>

Though uncommon, isolated nonsyndromic cases of iris, optic disc, and retinochoroidal colobomata have been documented in Nigeria.<sup>[9–11]</sup> A case of Noonan syndrome from Nigeria was included in a worldwide study of 161 patients, which phenotypically characterized non-European patients with NS based on clinical diagnosis and digital facial technology.<sup>[6]</sup> This index patient to the best of our knowledge may be the second documented case of Noonan syndrome in Nigeria.

Some patients have been erroneously diagnosed with isolated ocular colobomata, but systemic abnormalities were picked up on echocardiography, renal ultrasonography, audiology, and magnetic resonance imaging of the brain. Most of these abnormalities, however, did not require urgent intervention. If encountering a patient with an apparently isolated uveal coloboma, it is suggested that a protocol including

physical examination, baseline audiology assessment, kidney ultrasound, and spine X-ray be followed.<sup>[12]</sup>

Our patient was found to have abnormalities in the skeletal and cardiac systems. He also had characteristic facial facies like low-set ears, pointed chin, prominent philtrum, sparse hair, and low posterior hairline, features in keeping with NS.

NS is a genetic disease, and the commonest association is PTPN11 on chromosome 12q24.1, though fourteen other genes linked to this condition have been documented.<sup>[13]</sup> Genetic analysis for diagnosis was not possible; hence, the diagnosis of NS, in this case, was strictly a clinical diagnosis due to the paucity of facilities for genetic testing and facial digital recognition technology for diagnosis in our peculiar African populace.<sup>[6,14]</sup>

Clinically, the cornea of the left eye in our patient seemed to have a smaller diameter and the globe appeared to be smaller in comparison to the right though it has been documented that a normal globe without microphthalmos may have a small cornea.<sup>[15]</sup> Keratometry and measurement of the axial lengths of both eyes would have been beneficial in confirming this. It is known that about 24% of patients have these colobomas in both anterior and posterior segments as seen in our patient who had left iris and retinochoroidal coloboma.<sup>[16]</sup>

A pan-systolic murmur picked up on systemic examination necessitated an electrocardiogram and echocardiography, which confirmed the presence of a ventricular septal defect (VSD). Cardiac anomalies are a major component of NS as they occur in 50%–80% of patients. Common cardiac defects include pulmonary stenosis (20%–50%), hypertrophic cardiomyopathy (20%–30%), atrial and ventricular septal defects, branch pulmonary artery stenosis, tetralogy of Fallot, and rarely coarctation of the aorta.<sup>[17]</sup>

In a study done of diverse populations with NS, 7% of the patients of African origin had a VSD. The other findings in the African population included chest deformity in 59%, scoliosis in 37%, low set ears in 82%, and low posterior hairline in 64% of the patients, whereas 64% had learning or intellectual disabilities.<sup>[6]</sup> Our patient had a number of the features described in this African population like pectus excavatum, low set ears, and a low posterior hairline but no intellectual or learning disability as he was a university undergraduate. The absence of intellectual disabilities in the index patient is not surprising as 56% of the participants in a particular cohort studied had normal intellect.<sup>[18]</sup>

Facial features in NS may change over the years with adults having a more triangular facial outline, high

anterior hairline, prominent labial nasal folds, and thick hooded eyelids compared to children with NS.

The index patient had a triangular facial contour and high anterior hairline, respectively. However, these changes may make genotypic and phenotypic correlations of the disease challenging.<sup>[18,19]</sup>

Other diagnostic clinical features of NS in our patient included high-arched brows, low-set ears with thickened helix on the left, skeletal anomalies of tallipes equinovarus, toe abnormalities, and joint contracture in the right knee joint, which have all been documented in different clinical reviews and studies.<sup>[5,6,19]</sup>

Taking into consideration the fact that ocular colobomata are associated with various syndromes, which have similar clinical features as our patient, these syndromes had to be ruled out. Baraitser–Winter syndrome was a close differential that was ruled out as presentation is early in life with the majority of these patients having a severe intellectual disability.<sup>[3,20]</sup> The facial features of our patients like the pointed chin and triangular-shaped face were more in keeping with NS. Turner syndrome which may present with similar features was ruled out as our index patient was a male.

The gold standard of diagnosis is genetic testing and facial recognition technology. A detailed clinical evaluation and detailed history with a high index of suspicion are essential in making a diagnosis of Noonan syndrome. Genetic counseling should be carried out for family members as about 30%–75% of patients have an affected parent.

## CONCLUSION

The presence of ocular colobomata should sensitize the ophthalmologist and physician to the possibility of associated genetic and inherited syndromes. A detailed history and meticulous clinical evaluation must be done to rule out systemic associations of these syndromes before a diagnosis of isolated ocular colobomata is made. This is of clinical significance as a number of these systemic manifestations of ocular coloboma-associated syndromes are usually not life-threatening and may only be picked up with relevant indicatory investigations.

## Declaration of patient consent

The authors certify that they have obtained all appropriate patient consent forms. In the form the patient (s) has/have given his/her/their consent for his/her/their images and other clinical information to be reported in the journal. The patients understand that their names and initials will not be published and due efforts will be made to conceal their identity, but anonymity cannot be guaranteed.

## Financial support and sponsorship

Nil.

## Conflicts of interest

There are no conflicts of interest.

## REFERENCES

1. Onwochei BC, Simon JW, Bateman JB, Couture KC, Mir E. Ocular colobomata. *Surv Ophthalmol* 2000;45:175-94.
2. Bavbek T, Ogüt MS, Kazokoglu H. Congenital lens coloboma and associated pathologies. *Doc Ophthalmol* 1993;83:313-22.
3. Lingam G, Sen AC, Lingam V, Bhende M, Padhi TR, Xinyi S. Ocular coloboma—A comprehensive review for the clinician. *Eye* 2021;35:2086-109.
4. Gregory-Evans CY, Williams MJ, Halford S, Gregory-Evans K. Ocular coloboma: A reassessment in the age of molecular neuroscience. *J Med Genet* 2004;41:881-91.
5. Mendez HM, Opitz JM. Noonan syndrome: A review. *Am J Med Genet* 1985;21:493-506.
6. Kruszka P, Porras AR, Addissie YA, Moresco A, Medrano S, Mok GTK, *et al.* Noonan syndrome in diverse populations. *Am J Med Genet A* 2017;173:2323-34.
7. Kleanthous L, D’Cruz D, Graham E, Efthimiou J. Colobomata associated with Noonan’s syndrome. *Postgrad Med J* 1987;63:559-61.
8. Lee NB, Kelly L, Sharland M. Ocular manifestations of Noonan syndrome. *Eye* 1992;6:328-34.
9. Mosuro A, Baiyerolu A. A report of a case of bilateral iris coloboma in a 9 year old boy. *Internet J Ophthalmol Vis Sci* 2008;7:1-4.
10. Babalola YO, Olawoye OO, Idam PO. Optic disc coloboma in two Nigerian siblings: Case report and review of literature. *Niger J Clin Pract* 2017;20:1505-9.
11. Babalola YO, Oluleye TS. Retinochoroidal coloboma in a female Nigerian. *Niger J Ophthalmol* 2020;28:42-5.
12. Huynh N, Blain D, Glaser T, Doss EL, Zein WM, Lang DM, *et al.* Systemic diagnostic testing in patients with apparently isolated uveal coloboma. *Am J Ophthalmol* 2013;156:1159-68. e4.
13. Tartaglia M, Mehler EL, Goldberg R, Zampino G, Brunner HG, Kremer H, *et al.* Mutations in PTPN11, encoding the protein tyrosine phosphatase SHP-2, cause Noonan syndrome. *Nat Genet* 2001;29:465-8.
14. Adeyemo AA, Amodu OK, Ekure EE, Omotade OO. Medical genetics and genomic medicine in Nigeria. *Mol Genet Genomic Med* 2018;6:314-21.
15. Bateman JB, Maumenee IH. Colobomatous macropthalmia with microcornea. *Ophthalmic Paediatr Genet* 1984;4:59-66.
16. Nakamura KM, Diehl NN, Mohny BG. Incidence, ocular findings, and systemic associations of ocular coloboma: A population-based study. *Arch Ophthalmol* 2011;129:69-74.
17. Noonan JA. Noonan syndrome and related disorders. *Prog Pediatr Cardiol* 2005;20:177-85.
18. Shaw AC, Kalidas K, Crosby AH, Jeffery S, Patton MA. The natural history of Noonan syndrome: A long-term follow-up study. *Arch Dis Child* 2007;92:128-32.
19. Sharland M, Burch M, McKenna WM, Paton MA. A clinical study of Noonan syndrome. *Arch Dis Child* 1992;67:178-83.
20. Yates TM, Turner CL, Firth HV, Berg J, Pilz DT. Baraitser-Winter cerebrofrontofacial syndrome. *Lin Genet* 2017;92:3-9.