

## Original Article

# Recurrent Tumours of Ameloblastoma: Clinicopathologic Features and Diagnostic Outcome

MC Nwoga

Department of Oral Pathology and Oral Medicine, Faculty of Dentistry, College of Medicine, University of Nigeria, Enugu, Nigeria

**Received:**  
31-Jan-2022;  
**Revision:**  
03-Jun-2022;  
**Accepted:**  
22-Jun-2022;  
**Published:**  
22-Sep-2022

ABSTRACT

**Background:** Ameloblastoma is a benign epithelial odontogenic tumor with a tendency for recurrence. The recurrent tumors behave unpredictably with atypical microscopic changes and likelihood of malignant transformation. **Aims:** To study the clinicopathologic features and diagnostic outcome of recurrent tumors of ameloblastoma in Enugu. This is a six-year (2012-2017) retrospective study of 17 consecutive patients with recurrent tumors of ameloblastoma in a Teaching Hospital in Nigeria. **Materials and Methods:** The relevant clinicopathologic information, histology slides, and blocks were retrieved and reviewed. Descriptive analysis was used to determine the frequency, tables for categorical variables, and a Chi-square test was used to determine the statistical significance. **Result:** Recurrent tumors constituted 33.3% (17/51) of all confirmed diagnoses of ameloblastoma. The diagnostic outcome of the recurrent tumors was conventional ameloblastoma 58.8% (10), unicystic ameloblastoma 5.9% (1), and ameloblastic carcinoma 35.3% (6). There was bilateral mandibular extension in 60.0% (9), pain 58.8% (10), ulceration 29.4% (5), and matted lymph nodes 5.9% (1). Tumors with positive fluid aspirates 82.4% (14) yielded dark-brown fluids in 90.0% (9) of recurrent ameloblastomas and in 66.7% (2) of ameloblastic carcinomas. Atypical peripheral hyperplasia, nuclear hyperchromatism, and increased vascularization were commonly observed in benign recurrences. The frequency of recurrence is significantly associated with the biological behavior of ameloblastoma  $P = 0.03$ . **Conclusion:** Recurrent tumors of ameloblastoma presented atypical features and malignant transformation.

**KEYWORDS:** Ameloblastoma, bilateral, Nigeria, recurrences, tumor aspirates

## INTRODUCTION

Ameloblastoma is a benign intraosseous and epithelial odontogenic tumor with a tendency for recurrence.<sup>[1]</sup> Recurrences of 33.3% and 7.1% have been associated with conservative management (curettage, enucleation with curettage), and radical surgery respectively.<sup>[2,3]</sup> The recurrent tumors could behave unpredictably and review of these lesions identified microscopic changes,<sup>[1]</sup> and malignant transformation of 1.69%.<sup>[4]</sup> While frequent recurrences increased the likelihood of malignant transformation,<sup>[3,5,6]</sup> not all high recurring cases became malignant.<sup>[7]</sup> Additional factors contributing to malignant transformation include aggressive behavior,<sup>[8]</sup> high growth rate,<sup>[9]</sup> and

association with the mutated gene (the BRAF protein) implicated in other malignancies.<sup>[10,11]</sup>

Pain after an asymptomatic period and atypical histologic features have been described in recurrent ameloblastoma.<sup>[1,12]</sup> The multicystic histopathologic type, primary tumors greater than 6 cm, and soft tissue extension in ameloblastoma were significantly correlated with early recurrence.<sup>[4,13]</sup> A median recurrence interval as low as 34.0 months,<sup>[4]</sup> and

**Address for correspondence:** Dr. MC Nwoga,  
Department of Oral Pathology and Oral Medicine, Faculty of  
Dentistry, University of Nigeria, Enugu, Nigeria.  
E-mail: mark.nwoga@unn.edu.ng

This is an open access journal, and articles are distributed under the terms of the Creative Commons Attribution-NonCommercial-ShareAlike 4.0 License, which allows others to remix, tweak, and build upon the work non-commercially, as long as appropriate credit is given and the new creations are licensed under the identical terms.

**For reprints contact:** WKHLRPMedknow\_reprints@wolterskluwer.com

**How to cite this article:** Nwoga MC. Recurrent tumours of ameloblastoma: Clinicopathologic features and diagnostic outcome. Niger J Clin Pract 2022;25:1529-34.

Access this article online	
Quick Response Code: 	Website: <a href="http://www.njcponline.com">www.njcponline.com</a>
	DOI: 10.4103/njcp.njcp_82_22

recurrences of 80.0% within five years of surgery<sup>[14,15]</sup> were not uncommon.

The clinical behavior and histologic changes in recurrent tumors of ameloblastoma have received less attention in literature in contrast to the surgical management. It is hypothesized that if recurrent tumors of ameloblastoma exhibit atypical clinicopathologic features then the diagnostic outcome could be potentially malignant. There is therefore a need for more studies on the clinical features, histologic changes, and prevalence of malignant transformation in recurrent tumors of ameloblastoma. There have not been such studies in Nigeria to the best of the author's knowledge. This study will evaluate the clinicopathologic features of recurrent tumors and their diagnostic outcome in Enugu, Nigeria.

## MATERIALS AND METHODS

This is a five-year (April 2012 to March 2017) retrospective study of recurrences of intraosseous ameloblastoma in a tertiary hospital in Enugu, Nigeria. The case records of patients treated for intraosseous ameloblastoma and those who presented with recurrent tumors were retrieved from the archives of the medical records department. The biodata, relevant clinicopathologic information, and the histopathology reports of recurrent cases were extracted. The associated histologic slides and paraffin blocks were retrieved from the Oral Pathology departmental archives. All the slides of recurrent cases were reviewed for confirmation of the reported diagnosis.

The information obtained from the records of recurrent tumors of ameloblastoma was:

a) Gender, b) Occupation, c) Age at presentation, d) Duration of recurrent swelling, e) Interval between surgery and recurrence, f) Anatomic site and extent of tumor spread, g) History of pain, h) Presence of ulceration, i) Type and colour of tumor fluid aspirates, j) Histopathologic features and diagnosis, k) Type of surgical treatment received, l) Frequency of recurrence of each case, and m) Regional lymph node involvement.

This study followed the Declaration of Helsinki on medical protocol and ethics, and received the institutional approval of the Research Ethics Committee of the College of Medicine of the University of Nigeria, with the Protocol Number: 012/03/16.

## Statistics

The data were analyzed with Statistical Package for Social Sciences, version 23 (Chicago: SPSS Inc.). The frequencies and percentages were calculated for the descriptive variables. The association of categorical

variables using Chi-square tests was determined. The test of significance was set at  $P < 0.05$ .

## RESULTS

A total of 51 patients who received surgical treatment for primary ameloblastoma presented with 33.3% (17) of recurrent tumors. Seven (41.2%) patients, of the recurrent cases were referred from secondary-level hospitals. The male:female ratio of 1.4:1 and a mean age of  $35.6 \pm 11.3$  years were observed. The mean tumor duration at presentation was  $33.4 \pm 46.16$  months, (range: 3-156 months).

## Frequency of recurrences and prevalence of tumor aspirates

Single recurrences were observed in 70.6% (12/17) of the case series while multiple recurrences were noted in 29.4% (5/17). The mean recurrence interval (months) was  $63.0 \pm 78.8$  months (range 1-264) with a median interval of 24 months. Single recurrence, dark-brown aspirate, and benign diagnosis were the observed predominant features and diagnostic outcome, Table 1. The distribution of recurrent tumors by anatomical site showed anterior mandible as mostly affected with bilateral tumor extensions, Table 2. A single case of posterior mandibular swelling was observed, Figure 1. Pain and ulceration were notable features in recurrent tumors, while matted lymph nodes were uncommon, Table 3.

Table 4 shows types of aspirates in ameloblastoma and ameloblastic carcinoma. Tumor fluid was aspirated in 82.4% (14/17) of all recurrent tumors. Dark-brown aspirates were predominant in recurrent ameloblastoma and ameloblastic carcinoma, Table 4. The majority of dark brown aspirates, 90.9% (10/11) were observed at first recurrence. The single case of unicystic ameloblastoma (luminal) yielded a straw-colored aspirate. The frequency of recurrence has no significant relationship with the type of aspirate, ( $P = 0.103$ ).

In this series, tumors with negative aspirates 17.6% (3/17) were observed only in men, and in ameloblastic carcinoma cases, this observation was not significant  $P = 0.09$ . Of the three cases of ameloblastic carcinoma with negative aspirates, each case was detected at different recurrence frequencies, the 2<sup>nd</sup>, 3<sup>rd</sup>, and 4<sup>th</sup> recurrences, respectively.

Three cases presented positive fluid aspirates in ameloblastic carcinoma cases. The one case of ameloblastic carcinoma with straw-coloured aspirate presented with matted submandibular lymph nodes, while the two cases with dark brown aspirates showed an absence of lymph node involvement.

**Table 1: Clinical Features and Diagnostic Outcome of Recurrent Tumors of Ameloblastoma**

Gender/ Age	Duration (years)	Frequency	Recur Interval (years)	Site	Ulceration	Pain	Aspirate colour	Histologic Diagnosis
*M/60	0.5	1	22	†Ant ‡Mand	Nil	Yes	Dark-brown	Ameloblastoma
M/56	12	1	2	Ant Mand	Yes	Yes	Dark-brown	Ameloblastoma
§F/40	0.4	1	1	Ant Mand	Nil	Nil	Dark-brown	Ameloblastoma
F/35	4.3	1	2	Ant Mand	Nil	Nil	Dark-brown	Ameloblastoma
F/31	3.3	1	1	Ant Mand	Yes	Nil	Dark-brown	Ameloblastoma
F/34	0.3	1	14	‡Post Mand	Nil	Yes	Straw	Luminal Unicystic Ameloblastoma
F/24	1.3	1	2.5	Post mand	Yes	Yes	Dark-brown	Ameloblastoma
M/43	1	1	16	Ant-Post Mand	Nil	Nil	Dark-brown	Ameloblastic Carcinoma
M/39	0.6	1	2	Ant Mand	Nil	Yes	Dark-brown	Ameloblastic Carcinoma
F/23	2	1	1	Left †Max	Nil	Yes	Purulent	Ameloblastoma
M/24	2	1	0.1	Ant Mand	Nil	Yes	Dark-brown	Ameloblastoma
M/24	3	1	**N/A	Ant mand	Nil	Nil	Dark-brown	Ameloblastoma
M/39	1	2	4	Post Mand	Nnil	Nil	Nil	Ameloblastic Carcinoma
F/22	3	2	3	Ant-Post Mand	Yes	Yes	Straw	Ameloblastic Carcinoma
M/35	0.3	2	10	Ant-Post Mand	Nil	Nil	Dark-brown	Ameloblastoma
M/47	2	3	2	Ant Max	Yes	Yes	Nil	Ameloblastic Carcinoma
M/30	0.3	4	1.5	Post Mand	Nil	Yes	Nil	Ameloblastic Carcinoma

\*Male. †Anterior. ‡Mandible § female, ‖ posterior, † Maxilla, \*\*Not available

**Table 2: Anatomic Distribution of Recurrent Tumors of Ameloblastoma, n=17**

Anatomic Site	Recurrence Frequencies % (n)
Maxilla	11.8 (2)
Mandible	88.2 (15)
Posterior mandible only	6.7 (1)
Anterior mandibular involvement	93.3 (14)
Bilateral mandibular extension across midline: (Left to right/Right to left)	60.0 (9)
Ipsilateral extension: Anterior to body/angle	33.3 (5)

Table 5 showed that the association of histological diagnosis to aspirate type and color was not statistically significant,  $P = 0.068$ .

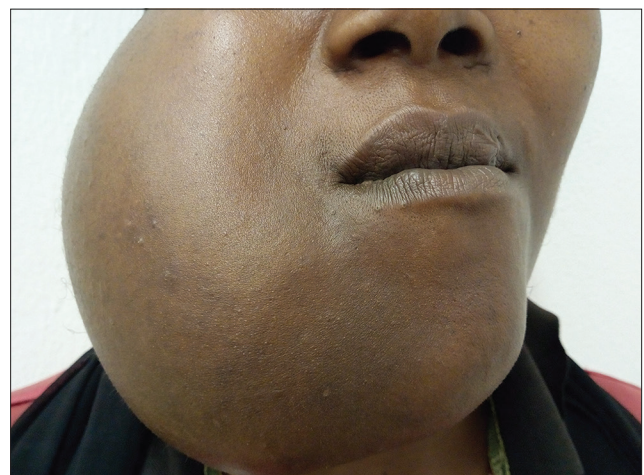### Surgical management and recurrence intervals

Radical surgical resection of the primary tumors was done for 10 patients from this Centre. The type of surgical treatment received by the seven patients from secondary hospitals was not indicated in their referral notes.

Thirteen (76.5%) patients had recurrences within four years of their last surgical treatment. The longest recurrence intervals were observed in four cases with 10, 14, 16, and 22 years.

### Diagnostic outcome and histologic features

The cytonuclear features consistent with benign tumors contributed to diagnoses of recurrent ameloblastoma in 58.8% (10/17) of cases. Table 6 shows histologic features associated with ameloblastomatous epithelium with variable degrees of peripheral epithelial

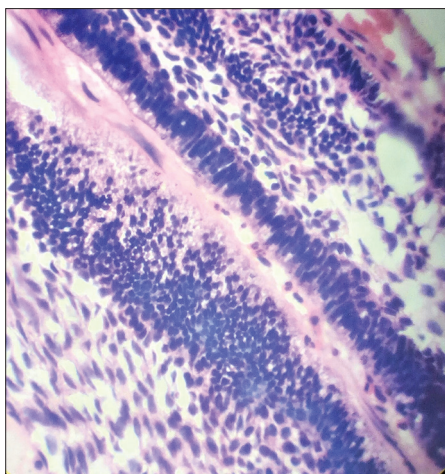


**Figure 1:** Clinical image showing a patient with a recurrent ameloblastic tumor

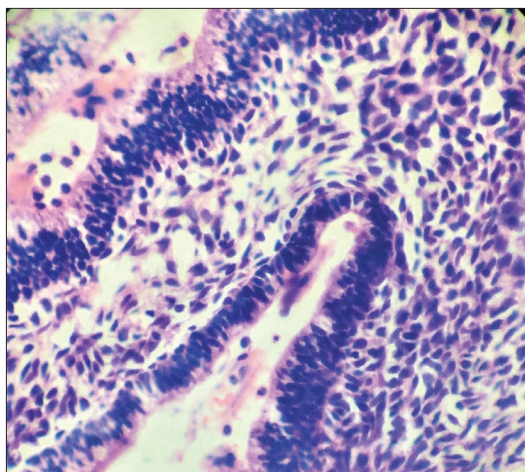
hyperplasia [Figures 2 and 3], hypercellular spindle central cells, numerous vascular channels, and haemorrhages [Figure 4] within the epithelial islands.

Other recurrent tumors showed features consistent with ameloblastic carcinoma in 35.3% (6/17). These features included atypical cells, hyperplastic and hyperchromatic peripheral and central epithelial cells, nuclear pleomorphism, increased and abnormal mitotic figures, focal necrosis, and loss of cellular adhesion. Of the six cases with a diagnostic outcome of ameloblastic carcinoma, three were diagnosed after a single recurrence 25.0% (3/12), while the other three were diagnosed after multiple recurrences: in 33.7% (1/3) of second recurrences, and in the only cases of third and fourth recurrences.

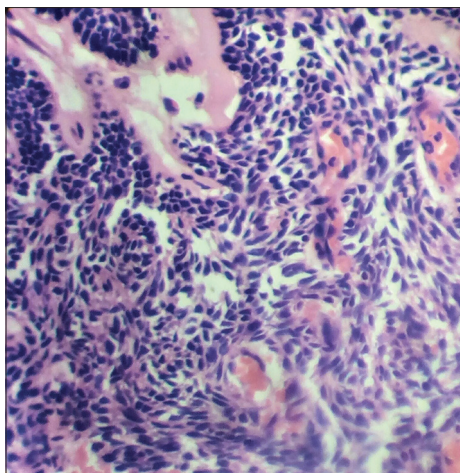




**Figure 2:** Recurrent ameloblastoma with dysplastic epithelial proliferation. The typical single columnar palisaded cells with reversed nuclear polarity are observed on the right while dysplastic hyperplastic peripheral epithelia are seen on the left. H & E x40



**Figure 3:** Dysplastic peripheral epithelial hyperplasia of tumor Islands H & E X40



**Figure 4:** Photomicrograph of recurrent ameloblastoma showing tumor area with intraepithelial vascularization. H & E x40

**Table 3: Frequencies of Recurrence, Ulceration, Pain, and Fluid Aspirate, n=17**

Clinicopathologic Features	Percentage/Value
<b>Recurrences</b>	
First Recurrence	70.6 (12)
Second Recurrence	17.6 (3)
Third Recurrence	5.9 (1)
Fourth Recurrence	5.9 (1)
Recurrences within Four Years	76.5 (13)
Presence of Ulceration	29.4 (5)
Presence of Pain	58.8 (10)
<b>Presence of Lymph Nodes</b>	
Palpable and Free	23.5 (4)
Matted	5.9 (1)
<b>Aspirate Type</b>	
Negative Tumor Aspirate Yield	17.6 (3)
Positive Tumor Aspirate Yield	82.4 (14)
<b>Straw</b>	
Dark-Brown	64.7 (11)
Purulent	5.9 (1)
<b>Histologic Type</b>	
Solid	58.8 (10)
Unicystic	5.9 (1)
Ameloblastoma Carcinoma	35.3 (6)
<b>Tumor Type</b>	
Benign	64.7 (11)
Malignant	35.3 (6)

**Table 4: Aspirate Types in Ameloblastoma and Ameloblastic Carcinoma, n=14**

Aspirate Type	Frequency % (n)
<b>In ameloblastoma</b>	
Dark-brown aspirate	90.0% (9)
Purulent aspirate	10.0% (1)
<b>In unicystic ameloblastoma</b>	
Straw-colored aspirate	100.0% (1)
<b>In ameloblastic carcinoma</b>	
Dark-brown aspirate	66.7% (2)
Straw-colored aspirate	33.3% (1)

**Table 5: Association of Histological Diagnosis to Type of Aspirate**

Histologic Diagnosis	Aspirate Color			Total	P
	Straw	Dark Brown	Purulent		
Solid	0	9 (90%)	1 (10%)	10	0.068
Unicystic	1 (100%)	0	0	1	
Ameloblastic Carcinoma	1 (33.3%)	2 (66.67%)	0	3	

## DISCUSSION

Malignant potential and malignant transformation of ameloblastoma following frequent recurrence have been reported.<sup>[3,5,6]</sup> In this study, some first and second recurrences were benign while others were malignant.

**Table 6: Frequency of Atypical Features in Recurrent Ameloblastoma (n=11)**

Variable	Frequency % (n)
Central Cells of Tumor Islands:	
Hypercellular and basaloid	36.4 (4)
Hypercellular and Spindle	18.2 (2)
Exhibited vesicular nuclei	9.1 (1)
Nuclear hyperchromatism	27.3 (3)
Peripheral Cells of Tumor Islands:	
Hyperplasia	54.5 (6)
Nuclear pleomorphism	45.5 (5)
Vesicular nuclei	9.1 (1)
Hyperchromatism	54.5 (6)
Hemorrhage within tumor islands	45.5 (5)
Moderate to extensive hemorrhage, with stromal engorged vascular channels	63.6 (7)

However, the third and fourth recurrences were malignant.

Frequent recurrence alone may not result in malignant transformation as observed in a case of ameloblastoma with five surgical interventions and three recurrences over a 29-year period.<sup>[7]</sup> This case was first diagnosed as unicystic ameloblastoma while the recurrences were follicular ameloblastoma and finally recurrent cystic ameloblastoma. Could the absence of malignant transformation be attributed to the primary diagnosis of unicystic ameloblastoma? It is recognized that the luminal unicystic ameloblastoma exhibits low biological and clinical aggression.<sup>[1]</sup> This agrees with the single recurrent case of luminal unicystic ameloblastoma in this series which remained benign. On the contrary, all the six cases of malignant transformations in this series were from conventional ameloblastoma.

The aggressive clinical behavior of recurrences in this series was indicated by frequent bilateral tumor spread within a short duration, pain, ulceration, and dark-brown tumor fluid aspirates. The malignant potential in a recurrence is based on local invasiveness, aggressive behavior,<sup>[8]</sup> high growth rate,<sup>[9]</sup> regional lymph node metastasis, distant metastasis as metastasizing ameloblastoma,<sup>[1]</sup> and frequent association with the BRAF gene mutation.<sup>[10]</sup> Metabolic alterations related to BRAF-V600E mutations in ameloblastoma have been suggested to contribute to tumor behavior.<sup>[16]</sup> BRAF gene mutation is similarly observed in established malignancies such as melanoma, thyroid, and colorectal carcinomas.<sup>[11]</sup>

The frequency of pain (58.8%) in the recurrent tumors studied contrasts with the 29% reported in an analysis of 136 primary cases.<sup>[17]</sup> Other authors also reported

pain after an asymptomatic period in recurrent ameloblastoma.<sup>[12]</sup> We suggest that the higher frequency of pain observed in recurrent tumors could be due to rapid growth against post-surgical distorted anatomical boundaries, compression of nerve bundles, and infection.

Only four cases with prolonged tumor-free intervals of 10, 14, 16, and 22 years, accounted for the long mean tumor-free interval of 63 months in this study. Recurrence in ameloblastoma tends to occur within a few years. The median recurrence interval of 24 months obtained in this series is in contrast to the 34 months reported in another study,<sup>[4]</sup> while the 76.5% of tumors recurring within four years of surgical treatment in this study is comparable to the 80.0% tumor recurrence reported within five years.<sup>[14,15]</sup>

The positive aspiration of tumor fluids was expected since intraosseous ameloblastoma is a cystic tumor.<sup>[11]</sup> The possible types of tumor fluids aspirable from cavities of intraosseous ameloblastoma have recently been categorized as straw, serosanguinous, dark-brown, and purulent.<sup>[18]</sup> Aspiration of hemorrhagic contents in recurrent ameloblastoma as reported by Hamdy *et al.*<sup>[19]</sup> and in vascularized ameloblastoma,<sup>[20]</sup> are rare and uncommon findings. However, the predominance of dark-brown fluid aspirate in recurrences in this series is a novel finding and could suggest a relationship with tumor behavior. It is also unknown to the authors if the type of fluid aspirate obtained in the primary tumor remained the same in the recurrent tumor. Dark-brown aspirates in primary ameloblastoma and in recurrent tumors of ameloblastoma could indicate a higher recurrence potential.

The purulent aspirate obtained in one case of multicystic ameloblastoma was probably secondary to tumor infection distorting a pre-existing tumor fluid. The negative fluid aspirates observed in three cases of ameloblastic carcinoma may suggest obliteration of cystic cavities by solid or semisolid materials from tumor proliferation. Such a proliferation could indicate an aggressive ameloblastic tumor. Negative aspiration though not specific to ameloblastic carcinoma, could also be found in any solid tumor or rapidly proliferating ameloblastoma.

## START

In some recurrent tumors with a benign outcome, atypical peripheral epithelial hyperplasia with nuclear hyperchromatism, prominent intraepithelial engorged vascular channels and hemorrhages were observed. These features are uncommon findings in primary ameloblastoma.<sup>[1]</sup> Agrawal *et al.*<sup>[12]</sup> reported similar atypical histologic features in recurrent ameloblastoma,

consisting of mitotic figures and numerous engorged capillaries. The atypical epithelial and vascular features constitute dysplastic changes and aggressive potential for malignant transformation. The bilateral tumor extensions, occasionally accompanied with pain and ulceration, are notable clinical differences between recurrent tumors and primary ameloblastoma.

Therapy for pain, histologic diagnosis and prompt surgical intervention are appropriate responses. Early radical surgical resections with tumor-free margins are recommended. However, these also alter the natural anatomical barriers of the jaws and adjoining tissues, eventually facilitating extension of recurrent tumors.<sup>[21]</sup> The mode of treatment of ameloblastoma is therefore significantly correlated with early recurrence.<sup>[4,13]</sup> Recurrences occur decades after radical surgeries,<sup>[7]</sup> therefore prolonged follow-up is recommended.

In conclusion, the biological behavior and a benign outcome of recurrent tumors are unpredictable. Aggressive behavior, high growth rate, pain, atypical histologic features, and malignant transformation are occasional features. Dark-brown fluid aspirates frequently observed in recurrent tumors could be an early indicator of aggressive tumor behavior. Recurrent tumors of ameloblastoma could be considered potentially malignant.

This study is limited by the small number of recurrent cases. The paucity of literature on clinicopathology of recurrent tumors limited comparisons and corroborations.

### Financial support and sponsorship

Nil.

### Conflicts of interest

There are no conflicts of interest.

### REFERENCES

- Takata T, Slootweg PJ. Odontogenic and maxillofacial bone tumours. In: El-Naggar AK, Chan JKC, Grandis JR, Takata T, Slootweg PJ, editors. WHO Classification of Head and Neck Tumors. 4<sup>th</sup> ed. Lyon: IARC Press; 2017. p. 203-60.
- Kim S, Jee Y, Lee D, Kim HH. Conservative surgical treatment for ameloblastoma: A report of three cases. *J Korean Assoc Oral Maxillofac Surg* 2018;44:242-7.
- Nakamura N, Higuchi Y, Mitsuyasu T, Sandra F, Ohishi M. Comparison of long-term results between different approaches to ameloblastoma. *Oral Surg Oral Med Oral Pathol Oral Radiol Endod* 2002;93:13-20.
- Rong Y, Zheqi L, Sandhya G, Canbang P, Tong J, Wei C. Recurrence and cancerization of ameloblastoma: Multivariate analysis of 87 recurrent craniofacial ameloblastoma to assess risk factors associated with early recurrence and secondary ameloblastic carcinoma. *Chin J Cancer Res* 2017;29:189-95.
- Hertog D, Bloemena E, Aartman IHA, Van der Waal I. Histopathology of ameloblastoma of the jaws: Some critical observations based on a 40 years single institution experience. *Med Oral Patol Oral Cir Bucal* 2012;17:E76-82.
- Zwahlen RA, Vogt P, Fischer FS, Grätz KW. Myocardial metastasis of a maxillary malignant ameloblastoma. *J Oral Maxillofac Surg* 2003;61:731-34.
- Faras F, Abo-Alhassan F, Israël Y, Hersant B, Meningaud JP. Multi-recurrent invasive ameloblastoma: A surgical challenge. *Int J Surg Case Rep* 2017;30:43-5.
- McClary AC, West RB, McClary AC, Pollack JR, Fischbein NJ, Holsinger CF, *et al.* Ameloblastoma: A clinical review and trends in management. *Eur Arch Otorhinolaryngol* 2016;273:1649-61.
- Odukoya O, Effiom O. Clinicopathological study of 100 Nigerian cases of ameloblastoma. *Niger Postgr Med J* 2008;15:1-5.
- Kurppa KJ, Catón J, Morgan PR, Ristimäki A, Ruhin B, Kellokoski J. High frequency of BRAF V600E mutations in ameloblastoma. *J Pathol* 2014;232:492-8.
- Holderfield M, Deuker MM, McCormick F, McMahon M. Targeting RAF kinases for cancer therapy: BRAF-mutated melanoma and beyond. *Nat Rev Cancer* 2014;14:455-67.
- Agrawal M, Weihsin H, Garg B, Sood R, Singh M. Atypical proliferative ameloblastoma with a rare histopathological feature and review of literature. *Oral Maxillo-fac Pathol J* 2015;6:582-5.
- Hong J, Yun PY, Chung IH, Myoung H, Suh JD, Seo BM, *et al.* Long-term follow up on recurrence of 305 ameloblastoma cases. *Int J Oral Maxillofac Surg* 2007;36:283-8.
- Olaitan AA, Arole G, Adekeye EO. Recurrent Ameloblastoma of the jaws: A follow-up study. *Int J Oral Maxillofac Surgery* 1998;27:456-60.
- Zhang J, Gu Z, Jiang L, Zhao J, Tian M, Zhou J, *et al.* Ameloblastoma in children and adolescents. *Br J Oral Maxillofac Surg* 2010;48:549-54.
- Duarte-Andrade FF, Silva AMB, Vitória JG, Canuto GAB, Costa SFS, Diniz MG, *et al.* The importance of BRAF-V600E mutation to ameloblastoma metabolism. *J Oral Pathol Med* 2019;48:307-14.
- Cadavid AMH, Araujo JP, Coutinho-Camillo CM, Bologna S, Lemos CA, Lourenco SV. Ameloblastomas: Current aspects of the new WHO classification in an analysis of 136 cases. *Surg Exp Pathol* 2019;2:17.
- Nwoga MC. Ameloblastoma in children and adolescents: A seven-year study in Enugu, Nigeria. *J Paediatr Dent Res Pract* 2021;2:23-8.
- Hamdy O, Raafat S, Saleh GA, Awany S, Shebl AM, Hegazy MA. Recurrent mandibular ameloblastoma in soft tissue and rib graft 17 years after initial presentation. *J Egypt Natl Canc Inst* 2020;32:1.
- Childers ELB, Taddasse-Heath L, Bonnick A, Naab T. Vascularized ameloblastoma: A case report and clinicopathologic review of 18 cases from the literature. *Oral Surg Oral Med Oral Pathol Oral Radiol* 2020;129:e264-8.
- Sakuranaka H, Sekine A, Miyamoto I, Yamakawa Y, Hirata A, Hagiwara E, *et al.* Pulmonary malignant ameloblastoma without local recurrence 31 years after primary resection: A case report and literature review. *Intern Med* 2020;59:1423-6.