

## Original Article

# Histopathologic Spectrum of Paediatric Eye and Ocular Adnexal Tumours: A 10-Year Review from a Referral Centre in Nigeria

DE Suleiman, Y Iliyasu<sup>1</sup>, SA Ahmed<sup>1</sup>, AA Liman<sup>1</sup>

Department of  
Histopathology, Abubakar  
Tafawa Balewa University  
Teaching Hospital,  
Bauchi (Formerly of  
Department of Pathology,  
Ahmadu Bello University  
Teaching Hospital, Zaria),  
<sup>1</sup>Department of Pathology,  
Faculty of Basic Clinical  
Sciences, College of Health  
Sciences, Ahmadu Bello  
University, Zaria, Nigeria

### Received:

27-Jul-2019;

### Revision:

16-Oct-2019;

### Accepted:

22-Jan-2020;

### Published:

04-May-2020.

## INTRODUCTION

The heterogeneity of tumours of the eye and ocular adnexa have been well documented; their great variety being attributable to the fact that the eye and its adnexae are embryologically derived from all three foetal germ cell layers: the endoderm, mesoderm and ectoderm.<sup>[1,2]</sup> To add to this intrinsic variety, malignant tumours from contiguous anatomic sites such as the nasal cavity and paranasal sinuses, parotid glands, and adjoining skin of the forehead and eyelids may also infiltrate the orbital space.<sup>[3]</sup>

To emphasize the uniqueness of diseases of children, it is often stated in medical literature that ‘children are not little adults!’ They have unique sets of characteristics that demand that the diseases affecting them be handled

with proper cognisance of these peculiarities. This maxim is equally true for tumours of the eye and ocular adnexa in the paediatric age group. The tumours in this age group are not necessarily miniaturised versions of adult tumours; certain tumours of this region are quite particular to the paediatric age with few, if any, occurrences in adults.

Tumours of or around the eye are of enormous social importance since they constitute a serious threat to vision particularly in children where it presents enormous

**Address for correspondence:** Dr. DE Suleiman,  
Department of Histopathology, Abubakar Tafawa  
Balewa University Teaching Hospital, Bauchi, Nigeria.  
E-mail: [daudee84@yahoo.com](mailto:daudee84@yahoo.com)

This is an open access journal, and articles are distributed under the terms of the Creative Commons Attribution-NonCommercial-ShareAlike 4.0 License, which allows others to remix, tweak, and build upon the work non-commercially, as long as appropriate credit is given and the new creations are licensed under the identical terms.

**For reprints contact:** [reprints@medknow.com](mailto:reprints@medknow.com)

**How to cite this article:** Suleiman DE, Iliyasu Y, Ahmed SA, Liman AA. Histopathologic spectrum of paediatric eye and ocular adnexal tumours: A 10-year review from a referral centre in Nigeria. Niger J Clin Pract 2020;23:654-9.

### ABSTRACT

**Background:** Tumours of the eye and adnexa demonstrate great histologic variety and constitute a serious threat to vision especially in children. **Aims:** The study aims to review the epidemiologic and pathologic characteristics of tumours of the eye and ocular adnexa in the paediatric age group (0-14 years). **Methods:** All the cases entered into the departmental records as tumours of the eye and ocular adnexa over a 10-year period in the age group 0-14 years were extracted. The patients' request cards with all relevant Haematoxylin & Eosin (H & E)-stained histology slides were retrieved. All the slides were reviewed and the cases were classified in accordance with the 4<sup>th</sup> edition of the WHO Classification of Tumours of the Eye (2018). The collected data were subjected to descriptive statistical tabulation and analysis. **Results:** A total of 104 tumours of the eye and ocular adnexae were diagnosed in the paediatric age group, accounting for 40.5% of all eye and ocular adnexal tumours diagnosed over the study period. The male to female ratio was 1.7:1 and malignant tumours greatly outnumbered benign tumours by a ratio of 5.5:1. Majority (76%) of the tumours occurred in the retina with retinoblastoma representing all the tumours diagnosed in this location. Rhabdomyosarcoma was the most common paediatric orbital tumour accounting for over half (53.8%) of all tumours in the orbit. Tumours of the conjunctiva and the eyelid were infrequent with benign soft tissue tumours (vascular, neural and lipomatous tumours) being the major tumours at these sites. **Conclusion:** Retinoblastoma is the single most common tumour in this age group.

**KEYWORDS:** Eye, pediatrics, retinoblastoma, tumour

### Access this article online

#### Quick Response Code:



**Website:** [www.njcponline.com](http://www.njcponline.com)

**DOI:** 10.4103/njcp.njcp\_389\_19

implications for their development.<sup>[2]</sup> The loss of an eye is particularly devastating in the young and can result in diverse psychosocial reactions in the child.<sup>[4,5]</sup> These reactions range from simple embarrassment to bullying and taunting from schoolmates or even depression. The use of an artificial eye also has psychological and economic implications for the child.<sup>[4]</sup> A previous study in Nigeria revealed that ocular tumours are the third most common cause of unilateral blindness in childhood behind ocular trauma and cataracts. The study also revealed that together with ocular trauma and infections, it constituted a major cause of severe visual impairment and blindness.<sup>[6]</sup> Various studies all over the world have identified orbito-ocular tumours as one of the commonest indications for surgical eye removal leading to monocular blindness, being second only to ocular trauma or third behind both trauma and infections in this regard.<sup>[5,7-9]</sup>

Worldwide, the age distribution of ocular tumours, is believed to be bimodal with peaks occurring during early childhood and adulthood. The first peak is largely due to retinoblastoma whereas uveal melanoma and conjunctival squamous cell carcinoma largely account for the second peak in Caucasians and black Africans respectively.<sup>[10,11]</sup>

There are varying reports on the prevalence of tumours of the eye and its adnexa in children and this is further complicated by the fact that most case series generally lack information on age distribution as they are usually more concerned with the percentage distribution of the specific histologic types of eye and orbital tumours.<sup>[12]</sup> However, benign eye and adnexal tumours in Nigeria have been reported to be commoner in adults as compared to children as demonstrated by studies from Kano,<sup>[13]</sup> and Benin.<sup>[14]</sup> Malignant tumours of the eye and adnexa, on the other hand, are particularly more frequent in children where most of these are retinoblastomas especially in the age range 0-5 years.<sup>[2,15-17]</sup>

Retinoblastoma has been well documented to be the most common malignant ocular tumour of childhood as exemplified by various studies from Nigeria,<sup>[2,16,18-20]</sup> Africa,<sup>[21,22]</sup> Asia,<sup>[23-25]</sup> and parts of Europe and North America.<sup>[26]</sup> In fact, some authors have described retinoblastoma as affecting all racial groups without sex predilection.<sup>[27]</sup> Analysis of a multicentre data from the Netherlands, Japan and United States reveal that retinoblastoma incidence had not changed in the 10-20 years preceding the time of the study.<sup>[27]</sup> The objective of this study is to review the histologic spectrum of tumours of the eye and ocular adnexa in the paediatric age group as obtained in a referral tertiary health centre in Northern Nigeria.

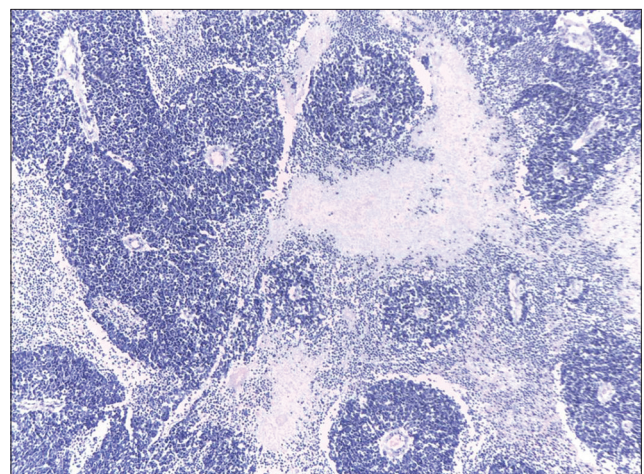
## METHODS

This retrospective study was carried out in the Department of Pathology, Ahmadu Bello University Teaching Hospital (ABUTH), Zaria. All specimens of the eye and ocular adnexa submitted to the department from patients aged 0-14 years from January 2005 to December 2014 were included in this study. The patients' request cards with all relevant Haematoxylin & Eosin (H & E)-stained histology slides were retrieved. Fresh sections were made from stored tissue blocks in the event of missing or broken slides. All the slides were reviewed and the cases were classified in accordance with the 4<sup>th</sup> edition of the WHO Classification of Tumours of the Eye (2018).<sup>[28]</sup> The collected data were subjected to descriptive statistical tabulation and analysis. Ethical clearance for the study was obtained from the Ethics and Scientific committee of ABUTH, Zaria.

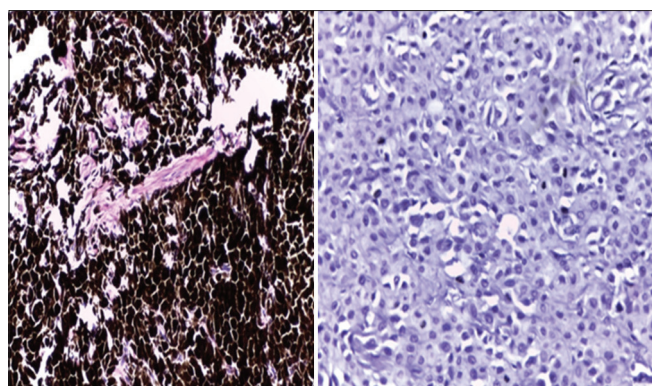
## RESULTS

A total of 104 tumours were diagnosed in the paediatric age group, accounting for 40.5% of the total tumours of the eye and ocular adnexa over the study period. There were 64 males and 40 females with a male to female ratio of 1.6:1. Malignant tumours greatly outnumbered benign tumours with a ratio of 5.5:1.

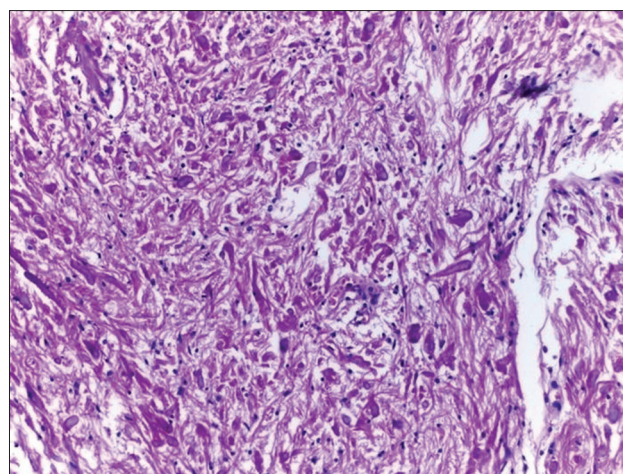
About three quarters (76%) of the tumours occurred in the retina with retinoblastoma representing all the 79 tumours diagnosed in this anatomic site as shown in Table 1. The average age of occurrence of retinoblastoma was 3.4 years (age range: 3 months to 8 years). There was a male preponderance with a male-female ratio of 1.7:1. About 53% of retinoblastomas in this study were poorly differentiated, while 14% were well differentiated. One case showed complete coagulative tumour necrosis and dystrophic calcification with only fossilised ghosts



**Figure 1:** Retinoblastoma with flexner-Wintersteiner rosettes [H & E; x100]



**Figure 2:** Cellular blue naevus of the uvea showing a heavily pigmented tumour (left) and the same tumour following bleaching of pigmented tumour with hydrochloric acid (right)



**Figure 3:** Pilocytic astrocytoma of the optic nerve showing numerous Rosenthal fibres. [H & E; x200]

**Table 1: Relative frequencies of eye and ocular adnexal tumours at various anatomic sites in the paediatric age group (0-14 years)**

Tumour	0-4	5-9	10-14	Total (%)
<b>Retina</b>				
Retinoblastoma	66	13	-	79 (76.0)
<b>Orbit</b>				
Rhabdomyosarcoma	-	5	2	7 (6.7)
Inflammatory pseudotumour	-	3	2	5 (4.8)
Alveolar soft part sarcoma	1	-	-	1 (1.0)
<b>Eyelid</b>				
Neurofibroma	-	-	3	3 (2.8)
Capillary haemangioma	2	-	1	3 (2.8)
<b>Conjunctiva</b>				
MPNST	1	-	-	1 (1.0)
Capillary haemangioma	-	-	1	1 (1.0)
Fibrolipoma	-	-	1	1 (1.0)
<b>Optic Nerve</b>				
Optic glioma	-	-	2	2 (1.9)
<b>Uvea</b>				
Cellular Blue naevus	-	1	-	1 (1.0)
<b>Total</b>	<b>70</b>	<b>20</b>	<b>12</b>	<b>104 (100.0)</b>

of tumour cells noted. Figure 1 shows a micrograph of a well differentiated retinoblastoma. About a third (34%) of the tumours had extraocular extension while optic nerve involvement was noted in 20 (25.3%) of the tumours.

The second most common site of occurrence of tumours was the orbit, accounting for 12.5% of all cases. Rhabdomyosarcoma was the most common paediatric orbital tumour accounting for over half (53.8%) of all tumours in the orbit and 6.7% of all tumours in the study. The mean age of occurrence was 9 years (age range: 6-13 years) with male-female ratio of 1.3:1. Majority (71.4%) of the rhabdomyosarcomas were of the embryonal type, with the remainder being alveolar rhabdomyosarcoma. The remaining orbital tumours in this age group were inflammatory pseudotumours and

a single case of alveolar soft part sarcoma. Curiously there was no single case of orbital Burkitt lymphoma diagnosed during the period of the study.

Tumours of the conjunctiva and the eyelids were relatively infrequent in the paediatric age group with a combined frequency of 11.4% of all paediatric eye and ocular adnexal tumours in this study. Benign soft tissue tumours (vascular, nerve sheath and lipomatous tumours) were the major tumours at these sites; however a single case of malignant peripheral nerve sheath tumour of the conjunctiva which represents the only malignancy of the conjunctiva in children in this study was noted. No single epithelial neoplasm was observed in the conjunctiva and eyelids in this age group. The remaining tumours occurred in the optic nerve and uvea and included 2 cases of optic nerve glioma and a case of cellular blue naevus of the uvea. Figures 2 and 3 show micrographs of optic nerve pilocytic astrocytoma and cellular blue naevus of the uvea respectively.

## DISCUSSION

This study reveals that, in general, tumours of the eye and ocular adnexa in the paediatric age group are about 5 times more likely to be malignant than benign. There is no doubt that this preponderance of malignant tumours over benign tumours reflects the overwhelmingly high numbers of cases of retinoblastoma in this age group. An interesting observation in this study was the fact that no single case of Burkitt lymphoma was diagnosed in the orbit. This is in sharp contrast to some very early studies in the country where Burkitt lymphoma even constituted the most frequently diagnosed neoplasm of the eye and ocular adnexa.<sup>[29-31]</sup> Similarly, an earlier study by Mohammed *et al.* in Zaria revealed that Burkitt lymphoma was the 3<sup>rd</sup> commonest orbito-ocular malignancy after Retinoblastoma and squamous cell

carcinoma over a 10-year review period (1993-2002).<sup>[15]</sup> It is also worth noting that most recent studies in the country also revealed a paucity of Burkitt lymphoma in this anatomical site.<sup>[18,20]</sup> This trend of an apparently decreasing frequency of occurrence of Burkitt lymphoma in the eye and ocular adnexa would require more in-depth investigation/studies to elucidate the reasons for this. In fact, Akang in a clinicopathological study of childhood cancers in Ibadan, noted a dramatic upsurge in the relative frequencies of retinoblastoma, leukaemia and intracranial tumours accompanied with a decline in the relative frequencies of Burkitt lymphoma and bone neoplasms over two periods of study (1960-1972 and 1973-1990) and suggested that further studies needed to be carried out to determine whether his findings reflected actual changes in the distribution of childhood cancer in the local population.<sup>[32]</sup> To this end, it is possible that this observation may actually reflect a more generalised change in the pattern of paediatric cancers. Various studies around the world have documented that rhabdomyosarcoma is the most common orbital cancer in children (exclusive of orbital extensions of retinoblastoma).<sup>[33-40]</sup> The mean age of occurrence of paediatric orbital rhabdomyosarcoma in this study was 9 years, slightly higher than the 6-8 years' range reported in various studies.<sup>[33,35,36,38]</sup> This slight difference may be due to variations in the inclusion criteria used in the various studies to define the paediatric age group. Embryonal rhabdomyosarcoma was the most predominant rhabdomyosarcoma subtype in this age group with only a single case of alveolar rhabdomyosarcoma noted. This is consistent with most current available information in the medical literature.<sup>[33,38-40]</sup> Another curiosity in this study is the absence of any case of benign vascular tumours in the paediatric age group over the study period. This is in stark contrast to various studies that have reported that vascular tumours, particularly capillary haemangioma and lymphangiomas, are either the most common or second most common primary orbital neoplasms in children.<sup>[34,35,37,41]</sup> However, Templeton in a 1971 study of orbital tumours in Ugandan children described as 'puzzling' the stark paucity of haemangiomas in his study, as only one case of haemangioma was noted out of 60 cases of children with proptosis.<sup>[42]</sup> Whether these observations represent distinct epidemiological variations of vascular tumours among various populations remains purely speculative at this time.

Conjunctival tumours in children in this study were mostly benign, non-epithelial tumours and consist mostly of vascular, nerve sheath and lipomatous lesions with no single epithelial neoplasm diagnosed in this age group. This finding is generally consistent

with reports in literature that show that epithelial lesions are relatively rare in children. However, those aforementioned studies also reveal a predominance of melanocytic tumours (mostly naevi), in the conjunctiva of children.<sup>[43,44]</sup> This is not the case in this study as we did not find a single conjunctival melanocytic tumour. The racial differences of the populations in their study (Caucasians, Latin America) may explain this finding as conjunctival and uveal melanocytic lesions has been reported to be distinctly uncommon in black Africans as compared to Caucasians.<sup>[12,45-48]</sup> Eyelid tumours were relatively uncommon and were completely benign, non-epithelial tumours- neurofibroma and haemangioma. This finding is not unexpected giving that epithelial tumours of the eyelid are rather rare in children and the few that have been reported in the literature were limited to a few case reports of basal cell carcinoma and squamous cell carcinoma, some of which arose in the setting of xeroderma pigmentosum.<sup>[49,50]</sup>

Tumours of the optic nerve in children in this study constituted 1.9% of all tumours in this age group and consist of 2 cases of optic nerve glioma. This is consistent with reports that these tumours are generally uncommon where they have been reported to account for 4% of orbital masses in children.<sup>[51]</sup> Majority of optic nerve gliomas (preferably referred to as optic pathway gliomas) in children are histologically juvenile pilocytic astrocytoma (WHO grade I).<sup>[52]</sup> Our two cases include one case each of pilocytic astrocytoma (WHO grade I) and diffuse fibrillary astrocytoma (WHO grade II). Additionally, more than half of the cases of paediatric optic pathway gliomas are reported in association with Neurofibromatosis type 1 (NF1) and has been identified as the most common central nervous system neoplasm in NF1 patients.<sup>[52,53]</sup> One of our cases also had multiple cutaneous nodules at presentation and was being evaluated for NF-1. There was a single case of tumour of the uveal tract in this study. This presented as a pigmented intraocular tumour in a 5-year-old girl and histologically confirmed to be a cellular blue naevus. The rarity of melanocytic uveal tumours (both benign and malignant) have been well documented in the literature.<sup>[29,46,54]</sup>

### Limitations of the study

This is a hospital-based study, and as such, some of the findings may not necessarily reflect occurrences in the population.

### CONCLUSION

Paediatric eye and ocular adnexal tumours demonstrate a wide variety of histologic types, however, retinoblastoma remain the single most important tumour in this age

group. In addition, orbital Burkitt lymphoma, hitherto reported as being one of the most common tumours at this site, appear to be dwindling rapidly. Ocular surface squamous neoplasia, though very common in adults, are rather rare in the paediatric age group.

### Financial support and sponsorship

Nil.

### Conflicts of interest

There are no conflicts of interest.

### REFERENCES

- Kapurdov A, Kapurdova M. Clinical, Morphological and epidemiological data on eye tumours. *J Sci* 2010;8:34-9.
- Igbe AP, Akhiwu WO, Eze GI. Childhood orbito-ocular tumours in Benin City, Nigeria-A 25 year histopathological review. *Ebony Med J* 2011;10:123-7.
- Deshpande R, Deodhar LP. Ocular and orbital tumours and tumour-like lesions - A clinico-pathological study of 64 cases. *J Postgrad Med* 1977;23:84-8.
- Ayanniyi A. Emotional, Psychosocial and Economic Aspects of Anophthalmos and Artificial Eye Use [Internet]. *Internet J Ophthalmol Vis Sci* 2008 [cited 2019 Jan 25]. Available from: <http://ispub.com/IJOVS/7/1/8540>.
- Etebu E, Adio A. Indications for removal of the eye at a tertiary hospital in south-southern Nigeria. *East African J Ophthalmol* 2008;14:19-22.
- Adegbegbe BO, Taiwo OA. Prevalence and pattern of childhood blindness in a resource limited teaching hospital in Nigeria. *East African J Ophthalmol* 2007;7:43-7.
- Ibanga A, Asana U, Nkanga D, Duke R, Etim B, Oworu O. Indications for eye removal in southern Nigeria. *Int Ophthalmol* 2013;33:355-60.
- Adeoye A, Onakpoya O. Indication for eye removal in Ile-Ife, Nigeria. *Afr J Med Med Sci* 2007;36:371-5.
- Setlur V, Parikh J, Rao N. Changing causes of enucleation over the past 60 years. *Graefes Arch Clin Exp Ophthalmol* 2010;248:593-7.
- Ud-Din N, Mushtaq S, Mamoon N, Khan A, Malik I. Morphological Spectrum of Ophthalmic Tumors in Northern Pakistan. *UPMA* 2001;51:19-22.
- Ademola-Popoola D, Owoeye J, Afolayan E, Adepoju F. Spectrum of orbito ocular tumors in Ilorin, Nigeria. *UICC World Cancer Congress*. Washington DC: Medimond S.r.l; 2006. p. 149-52.
- Parkin DM, Ferlay J, Hamdi-Chérif M, Sitas F, Thomas JO, Wabinga H, *et al.*, editors. *Cancer in Africa: Epidemiology and Prevention*. Lyon: International Agency for Research on Cancer. IARC Scientific Publication No. 153. 2003. Available from: <http://publications.iarc.fr/308>. [Last accessed on 2016 Mar 10].
- Umar AB, Ochicha O, Iliyasu Y. A pathologic review of ophthalmic tumors in Kano, Northern Nigeria. *Niger J Basic Clin Sci* 2012;9:23-6.
- Charles NC, James EV. A study of the histopathologic pattern of orbito-ocular disease in a tertiary hospital in Nigeria. *Sahel Med J* 2014;17:60-4.
- Mohammed A, Ahmed SA, Ahmedu NE, Maisamari JS. Orbito-ocular malignant tumours in Zaria, Nigeria: A 10-Year review. *Ann Afr Med* 2006;5:129-31.
- Abiose A, Jaiye A, Agarwal S. Childhood malignancies of the eye and orbit in Northern Nigeria. *Cancer* 1985;55:2889-93.
- Nnoli M, Abdulkareem F, Banjo AA, Anunobi C, Daramola A, Nnoli C. The commonest orbito-ocular tumours of children in Lagos State, Nigeria. *Pioneer Med J* 2011;1:1-8.
- Abah ER, Garba F, Rafindadi AL, Adamu A, Chinda D, Samaila MO. A clinico-pathological study of orbito-ocular tumors at Ahmadu Bello University Teaching Hospital, Shika-Zaria, Nigeria: A 5-year review. *Clin Cancer Investig J* 2012;1:145-7.
- Mahmoud AO, Buari MB, Adekoya BS. Pattern of orbito ocular growths in Ilorin, Nigeria. *Trop J Heal Sci* 2007;14:23-7.
- Askira B, Nggada H. Orbito-ocular malignancies in Maiduguri, North Eastern Nigeria: A histopathologic review. *Internet J Ophthalmol Vis Sci* 2006;5:1-4.
- Templeton A. Tumours of the eye and adnexa in Africans of Uganda. *Cancer* 1967;20:1689-98.
- Onwasigwe E. Orbito-ocular tumours in Nigerian Children. *J Coll Med* 2002;7:101-3.
- Sunderraj P. Malignant tumours of the eye and adnexa. *Indian J Ophthalmol* 1991;39:6-8.
- Yuliawati P, Piliantari-Meigawati NL. Eye tumour patients at tumour division eye clinic Sanglah General Hospital Bali-Indonesia. *Bali Med J* 2013;2:64-8.
- Roh KK, Lee JH, Youn DH. Clinical analysis of tumours of the eye and its adnexa. *Kor J Ophthalmol* 1988;2:27-31.
- Yun J, Li Y, Xu CT, Pann BR. Epidemiology and Rb1 gene of retinoblastoma. *Int J Ophthalmol* 2011;4:103-9.
- McLean IW, Burnier MN, Zimmerman LE, Jakobiec FA. *Tumours of the Eye and Ocular Adnexa*. In *Atlas of Tumour pathology, 3<sup>rd</sup> series, fascicle 12*. Washington, DC, Armed Forces Institute of Pathology, 1994.
- Grossniklaus HE, Eberhart CG, Kivela TT, editors. *WHO Classification of Tumours of the Eye*. 4<sup>th</sup> ed. Lyon: International Agency for Research on Cancer; 2018.
- Olurin O, Williams A. Orbito-ocular tumours in Nigeria. *Cancer* 1971;30:580-7.
- Ochicha O, Ekanem I. Tumours of the eye and ocular adnexa in south-eastern Nigeria: A histopathological study. *Sahel Med J* 1999;2:21-4.
- Olasimbo O. Histopathological study of orbito-ocular tumours in Lagos [dissertation]. Ijanikin, Lagos: National Postgraduate Medical College of Nigeria; 1992.
- Akang E. Tumours of childhood in Ibadan, Nigeria (1973–1990). *Pediatr Pathol Lab Med* 1996;16:791-800.
- Rao AA, Naheedy JH, Chen JY, Robbins SL, Ramkumar HL. A clinical update and radiologic review of pediatric orbital and ocular tumors. *J Oncol* 2013;2013:1-23.
- Alkatan HM, Al Marek F, Elkhamary S. Demographics of pediatric orbital lesions: A tertiary eye center experience in Saudi Arabia. *J Epidemiol Glob Health* 2019;9:3-10.
- Domingo RE, Manganip LE, Castro RM. Tumors of the eye and ocular adnexa at the Philippine Eye Research Institute: A 10-year review. *Clin Ophthalmol* 2015;9:1239-47.
- Castillo BV, Kaufman L. Paediatric tumours of the eye and orbit. *Pediatr Clin North Am* 2003;50:149-72.
- Shields JA, Shields CL, Scartozzi R. Survey of 1264 patients with orbital tumors and simulating lesions: The 2002 Montgomery Lecture, part 1. *Ophthalmology* 2004;111:997-1008.
- Meel R. Pediatric orbital tumors-An overview. *Clin Exp Vis Eye Res J* 2018;1:1-6.
- Chung EM, Smirniotopoulos JG, Specht CS, Schroeder JW, Cube R. Pediatric orbit tumors and tumorlike lesions: Nonosseous lesions of the extraocular orbit. *Radiographics* 2008;27:1777-9.
- Fowler BT, Wilson MW. Orbital Rhabdomyosarcoma. *Eye Wiki- American Academy of Ophthalmology* 2018. Available

- from [https://eyewiki.aao.org/orbital\\_rhabdomyosarcoma](https://eyewiki.aao.org/orbital_rhabdomyosarcoma). [Last accessed on 2018 May 22].
41. Modi PJ, Shah NA, Bhalodia JN, Gonsai RN. Orbital tumours in children: A descriptive study at tertiary care centre. *Natl J Med Res* 2013;3:362-6.
  42. Templeton A. Orbital tumours in African children. *Br J Ophthalmol* 1971;55:254-61.
  43. Zimmermann-Paiz MA, de la Riva JC. Conjunctival tumors in children: Histopathologic diagnosis in 165 cases. *Arq Bras Oftalmol* 2015;78:337-9.
  44. Shields CL, Shields JA. Conjunctival tumors in children. *Curr Opin Ophthalmol* 2007;18:351-60.
  45. Miller B, Abrahams C, Cole GC, Proctor NS. Ocular malignant melanoma in South African blacks. *Br J Ophthalmol* 1981;720-2.
  46. Eagle R. The pathology of ocular cancer. *Eye* 2013;27:128-36.
  47. Alkatan H, Alzahem T. Histopathology of the Ocular Surface. *Histopathology- An Update*. Intech Open; 2016. p. 67-88.
  48. Shields CL, Demirci H, Karatza E, Shields JA. Clinical survey of 1643 melanocytic and nonmelanocytic conjunctival tumors. *Ophthalmology* 2004;111:1747-54.
  49. Suarez MJ, Rivera-Michlig R, Dubovy S, Rodriguez FJ. Clinicopathological features of ophthalmic neoplasms arising in the setting of xeroderma pigmentosum. *Ocul Oncol Pathol* 2016;2:112-21.
  50. Al-Buloushi A, Filho JP, Cassie A, Arthurs B, Burnier MN Jr. Basal cell carcinoma of the eyelid in children: A report of three cases. *Eye* 2005;19:1313-4.
  51. Lena G, Pech-Gourg G, Scavarda D, Klein O, Paz-Paredes A. Gliome du nerf optique chez l'enfant. *Neurochirurgie* 2010;56:249-56.
  52. Chung EM, Jason W. From the archives of the afip pediatric orbit tumors and tumorlike lesions: Neuroepithelial lesions of the ocular globe and optic nerve. *Radio* 2007;27:1159-87.
  53. Binning MJ, Liu JK, Kestle JR, Brockmeyer DL, Walker ML. Optic pathway gliomas: A review. *Neurosurg Focus* 2007;23:143-59.
  54. Klintworth GK. The eye and ocular adnexa. In: Mills SE, Carter D, Greenson J, Al E, editors. *Stenberg's Diagnostic Surgical Pathology*. 4<sup>th</sup> ed. Philadelphia: Lippincott. Williams and Wilkins; 2004. p. 1073-108.