

## Original Article

# Correlation between Buccal and Alveolar Bone Widths at the Central Incisors According to Cone-beam-computed Tomography

DD Üner, BS İzol<sup>1</sup>, Z Görüş<sup>2</sup>

Departments of  
Periodontology and  
<sup>2</sup>Prosthodontics, Faculty of  
Dentistry, Harran University,  
Şanlıurfa, <sup>1</sup>Department of  
Periodontology, Faculty of  
Dentistry, Dicle University,  
Diyarbakır, Turkey

ABSTRACT

**Objective:** The aim of this study is to assess whether there is a correlation between buccal bone thickness and mean alveolar bone thickness around the central teeth using CBCT images. **Materials and Methods:** Three points were selected at 3, 6 and 9 mm from the cemento-enamel junction, respectively, perpendicular to the long axis of the measuring points made to determine the width of the alveolar bone ridge. The arithmetic mean of the length measurements was taken as the average alveolar bone thickness. To determine the average buccal alveolar bone thickness, the buccal bone length was measured perpendicular to the long axis of the tooth from these 3 points, and the average of the measurements was taken from these 3 points. **Results:** The mean coronal, mid-root, and apical third root widths of the maxillary, left central incisors were  $7.72 \pm 0.60$ ,  $8.64 \pm 0.93$ , and  $9.23 \pm 1.45$  mm, respectively and the mean widths of the buccal alveolar bone at the coronal, mid-root, and apical third root positions of the left central incisor were  $1.18 \pm 0.39$ ,  $1.15 \pm 0.44$ , and  $1.06 \pm 0.50$  mm, respectively. The Spearman correlation coefficients were 0.194 and 0.191 for the left and right central incisors, respectively. **Conclusions:** There was no statistically significant difference between the alveolar bone thickness averages of the left and right central incisors, but the alveolar bone thickness was found to be thicker in males than females. Although the mean of alveolar and buccal bone thicknesses was positively correlated the statistical analysis demonstrated the correlation between the mean of alveolar and buccal bone thicknesses is not significant.

**KEYWORDS:** Alveolar ridge, buccal bone, computed tomography, immediate implant, maxillary central incisor

**Date of Acceptance:**  
03-Jul-2018

## INTRODUCTION

Adequate alveolar bone volume and appropriate alveolar ridge architecture are essential for ideal functional and esthetic prosthetic reconstruction after implant therapy.<sup>[1]</sup> According to the Branemark protocol, 3–4 months of healing is required to allow induration of the extraction socket. When prosthetic treatment is required, patients usually wait for up to 1 year before replacement of a lost tooth.<sup>[2]</sup> Immediate dental implantation, introduced in the 1970s, allows implantation immediately after extraction.<sup>[3]</sup> The treatment time is long, as it is well known that after tooth extraction, physiological processes cause dimensional changes in the alveolar ridge (e.g., resorption).<sup>[4]</sup> Proper

planning is crucial if implantation is to be successful. The height, width, morphology, and density of alveolar bone surrounding the area to be implanted must be measured to determine the size of the implant and the placement angle.<sup>[5-7]</sup> Severe reductions in the buccolingual and apical coronal extents of the alveolar region are evident after tooth extraction.<sup>[8,9]</sup> The changes are usually clinically significant and may render it difficult to place a conventional bridge or implant-supported crown.

**Address for correspondence:** Dr. DD Üner,  
Department of Periodontology, Faculty of Dentistry,  
Harran University, Şanlıurfa, Turkey.  
E-mail: [dvrmdnznr@gmail.com](mailto:dvrmdnznr@gmail.com)

This is an open access journal, and articles are distributed under the terms of the Creative Commons Attribution-NonCommercial-ShareAlike 4.0 License, which allows others to remix, tweak, and build upon the work non-commercially, as long as appropriate credit is given and the new creations are licensed under the identical terms.

**For reprints contact:** [reprints@medknow.com](mailto:reprints@medknow.com)

**How to cite this article:** Üner DD, İzol BS, Görüş Z. Correlation between buccal and alveolar bone widths at the central incisors according to cone-beam-computed tomography. *Niger J Clin Pract* 2019;22:79-84.

Access this article online	
Quick Response Code:	Website: <a href="http://www.njcponline.com">www.njcponline.com</a>
	DOI: 10.4103/njcp.njcp_320_18

Successful osseointegration of a dental implant requires a sufficient amount of healthy bone in the recipient region.<sup>[10]</sup> It has been established that it can be difficult to create implant-supported prostheses after tooth extraction in the esthetic zone.<sup>[11,12]</sup> Moreover, the buccal bony plate is usually thin, especially in that zone. Clinicians are always concerned about implant appearance.<sup>[13,14]</sup> Adequate buccal bone in the anterior maxillary region is essential for correct implant positioning;<sup>[15,16]</sup> the buccal plate of the upper jaw is resorbed to a greater extent than is the palatal plate, causing the center of the ridge to shift in the palatal direction.<sup>[17]</sup>

Many two- and three-dimensional methods have been developed to determine alveolar bone height and width.<sup>[18]</sup> Bone evaluation using only panoramic and intraoral periapical radiographs may be inadequate, as only two-dimensional data are available.<sup>[19]</sup> Buccolingual ridge width can be measured by cone-beam-computed tomography (CBCT), ridge mapping, trans-tomography, and direct caliper measurements following surgical exposure of the bone.<sup>[20-24]</sup> The alveolar ridge widths obtained by ridge mapping, CBCT, and direct surgical exposure do not differ significantly.<sup>[23,25-27]</sup> However, ridge mapping is attractive because it is precise, inexpensive, yields immediate results and does not require the use of radiation.<sup>[26]</sup>

The buccal bone thickness is essential to the immediate implant placement, and previous studies have shown precise information about the amount of alveolar bone thickness without using CBCT. Therefore, we evaluated the relationship between the alveolar ridge and buccal bone thickness using CBCT.

## MATERIALS AND METHODS

### Study population

This study conformed to all relevant tenets of the 1964 Helsinki Declaration and was approved by the Ethics Committee of the Dicle University Faculty of Dentistry. The research was conducted between December 2014 and February 2016 at the Dicle University Faculty of Dentistry. Eighty patients admitted to the departments of Oral Diagnosis and Radiology; Oral, Dental and Orthopaedic Surgery; Periodontology, Orthodontics; Prosthetic Dentistry, Pedodontics; Dental Diseases; and Endodontics for any reason underwent three-dimensional CBCT (I-CAT®, Model 17-19; Irma Medicine Sciences International, Hatfield, PA, USA). CBCT images were obtained at 120 kV for 8–9 s at 5 mA (voxel size 0.3 mm). The ages of the 80 males and 80 females ranged from 21 to 53 years (mean age  $36.86 \pm 7.78$  years). The anterior maxilla and the central incisors were clear on the CBCT images. Patients with

crowns, fillings, or bruises; who had undergone root canal treatment; who exhibited periodontal bone loss or dental pathology; and those with irregular, anterior maxillary teeth were excluded.

### Study design

All measurements were made by a periodontologist using Vision software. To determine the width of the alveolar ridge, measurements were taken at 3, 6, and 9 mm distance from the cemento-enamel junction, perpendicular to the long axis of the tooth; the three regions were termed the crestal, mid-root, and apical regions, respectively, of both the right and left central teeth [Figure 1]. The average alveolar ridge thickness for each tooth was the mean of the three values. Next, buccal alveolar bone thickness (measured perpendicular to the long axis of the tooth) was measured at the three regions [Figure 2]. The average buccal bone thickness was the mean of the three values.

### Statistical analysis

Descriptive statistics are presented as means with standard errors or standard deviations, and averages. The normality of the data was explored using the Shapiro–Wilk test, and data homogeneity was evaluated employing Levene's test. Thickness data were compared between the genders using the independent *t*-test. Spearman correlation coefficients (*rho* values) were calculated to assess the relationship between mean alveolar ridge and buccal bone thicknesses. In all analyses, *P* values of 0.05 and 0.01 were considered to reflect statistical significance.

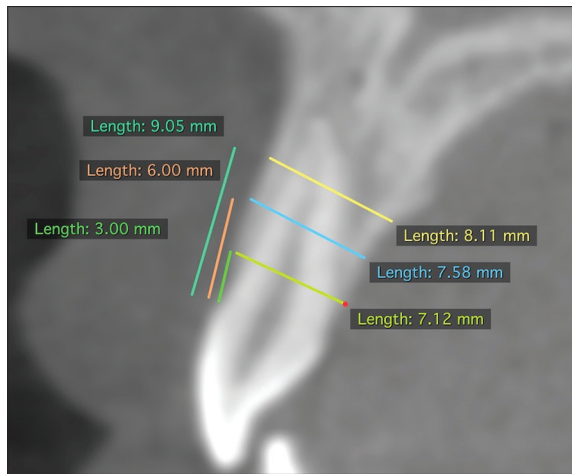
## RESULTS

In total, 160 CBCT scans were analyzed (320 teeth). The mean coronal, mid-root, and apical third root widths of the maxillary left central incisors were  $7.72 \pm 0.60$ ,  $8.64 \pm 0.93$ , and  $9.23 \pm 1.45$  mm, respectively; the figures for the maxillary right central incisors were  $7.76 \pm 0.60$ ,  $8.67 \pm 0.83$ , and  $8.98 \pm 1.89$  mm, respectively [Graph 1]. In females, the mean coronal, mid-root, and apical third root, left incisor, alveolar bone widths were  $7.55 \pm 0.52$ ,  $8.27 \pm 0.89$ , and  $8.73 \pm 1.5$  mm; the figures for males


**Table 1: Mean buccal bone widths of the left and right anterior maxillary incisors**

	<i>n</i>	Minimum	Maximum	Mean	Std. deviation
LBC	160	0.30	2.23	1.1864	0.39866
LBM	160	0.10	2.21	1.1510	0.44357
LBA	160	0.20	2.34	1.0656	0.50199
RBC	160	0.56	2.00	1.1338	0.30395
RBM	160	0.21	2.40	1.0859	0.43327
RBA	160	0.10	2.93	1.0660	0.53709

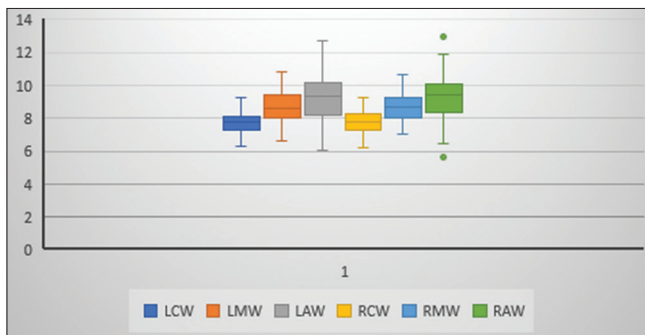
LBC=Left Bucco-Coronal; LBM=Left Bucco-Medial; LBA=Left Bucco-Apical; RBC=Right Bucco-Coronal; RBM=Right Bucco-Medial; RBA=Right Bucco-Apical



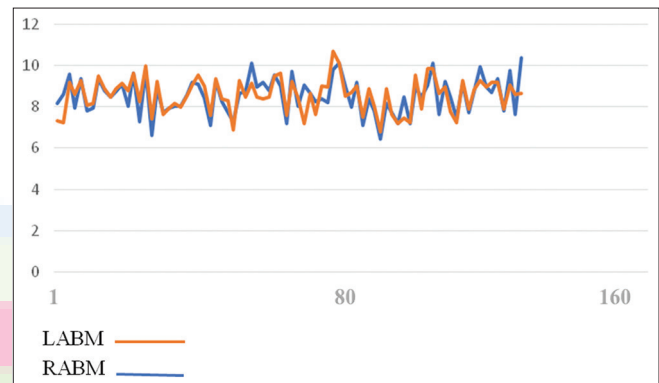
**Figure 1:** Measurement of alveolar bone thickness from three different regions



**Figure 2:** Measurement of buccal bone thickness from three different regions



**Graph 1:** Mean of alveolar bone width at three points. LCW=Left coronal width; LMW=Left medial width; LAW=Left apical width; RCW=Right coronal width; RMW=Right medial width; RAW=Right apical width



**Graph 2:** Mean alveolar bone width. LABM=Mean left alveolar bone width; RABM=Mean right alveolar bone width

were  $7.88 \pm 0.63$ ,  $9.02 \pm 0.83$ , and  $9.73 \pm 1.23$  mm, respectively. In females, in the right maxillary incisor region, the mean alveolar bone widths at the coronal, mid-root, and apical third root were  $7.63 \pm 0.60$ ,  $8.31 \pm 0.69$ , and  $8.81 \pm 1.29$  mm, respectively; the figures for males were  $7.89 \pm 0.59$ ,  $9.03 \pm 0.81$ , and  $9.61 \pm 1.39$  mm, respectively. The between-gender differences were statistically significant for all regions except the coronal region of the right central incisor. The alveolar ridge width was greater in males than in females in all regions measured.

The mean widths of the buccal alveolar bone at the coronal, mid-root, and apical third root positions of the left central incisor were  $1.18 \pm 0.39$ ,  $1.15 \pm 0.44$ , and  $1.06 \pm 0.50$  mm, respectively; the figures for the right central incisor were  $1.13 \pm 0.30$ ,  $1.08 \pm 0.43$ , and  $1.06 \pm 0.53$  mm, respectively [Table 1]. The average thicknesses were the arithmetic means of these values:  $1.13 \pm 0.33$  and  $1.09 \pm 0.33$  mm for the left and right central incisors, respectively.

We sought to predict buccal bone width before immediate implantation. Thus, we calculated the

arithmetic means of data from the coronal, mid-root, and apical third root alveolar bone measurements and used these to determine the correlation between alveolar ridge and buccal bone widths [Figure 1]. The mean widths of the alveolar ridges were  $8.53 \pm 0.87$  and  $8.56 \pm 0.82$  mm for the left and right maxillary incisors, respectively; these figures did not differ significantly. In females, the left central incisor mean facio-palatal dimension was  $8.18 \pm 0.84$  mm, and the mean alveolar bone ridge width of the right central incisor was  $8.27 \pm 0.73$  mm; for males, the figures were  $8.88 \pm 0.76$  and  $8.85 \pm 0.82$  mm, respectively [Graph 2]. The mean (left and right) incisor, alveolar ridge widths of males and females differed significantly (*t*-test  $P < 0.05$ ;  $P = 0.0001$  on the right, and  $P = 0.0002$  on the left); the alveolar bone ridge was thicker in males than in females. However, age did not affect either buccal bone width or alveolar ridge width. The relationship between alveolar ridge width and buccal bone width was not significant for the left and right central incisor (left central incisor's  $\rho = 0.194$ ,  $P = 0.085$ ; right central incisor's  $\rho = 0.191$ ,  $P = 0.090$ ).

## DISCUSSION

Our aim was to predict alveolar, bone, buccal plate thickness before immediate implantation and to compare that value with the alveolar, bone, ridge thickness revealed by CBCT. Immediate implant placement is associated with high cumulative implant survival (96.16–100%).<sup>[28-30]</sup> It is essential to know the alveolar bone dimensions prior to surgery.<sup>[18]</sup> The proportion of alveolar bone resorption after tooth extraction is approximately 45%.<sup>[8]</sup> Furthermore, a meta-analysis showed that the alveolar bone dimensions near implant sites fell by about 0.5–1.0 mm both vertically and horizontally 4–12 months after surgery.<sup>[31]</sup> The extent of vertical resorption of buccal bone was related to the initial buccal, crest bone thickness.<sup>[32]</sup>

A major concern when planning implantation is correct estimation of bone thickness, as the mucosal contours can mask the alveolar ridge.<sup>[21]</sup> Therefore, CBCT, ridge mapping, and direct measurement of bone thickness during surgery have been developed.<sup>[21,23,24,33,34]</sup> All measurements agree.<sup>[24,25,34]</sup> When ridge mapping using calipers under local anesthesia, the pointed caliper tips penetrate the buccal and lingual soft tissues to measure the buccolingual width of the underlying bone.<sup>[35]</sup> This is simple, and the patient is not exposed to radiation.<sup>[34]</sup> We sought to determine the correlations between alveolar and buccal bone thicknesses using CBCT. As it is clear that both CBCT and ridge mapping can be used to determine alveolar bone thickness, the existence of a correlation between alveolar and buccal bone thickness would mean that CBCT would not be required for assessment of buccal bone thickness. Several studies measured buccal and alveolar ridge thicknesses around natural teeth.<sup>[23,36-42]</sup> The coronal, mid-root, and apical, central, incisor, alveolar, mean bone widths were 0.73–0.83, 0.69–0.80, and 0.6–0.90 mm, respectively.<sup>[13,33,36,39,43]</sup> Here, the coronal, buccal, alveolar bone thicknesses were 1.18 and 1.13 mm for the left and right central incisors, respectively. The mid-root alveolar bone widths were 1.15 and 1.08 mm for the left and right central incisors, respectively. The apical alveolar bone widths were 1.06 mm for both the left and right central incisors. The results of other studies differed from ours in that the central, incisor, alveolar bone width were thicker in our study, perhaps because the measuring points perpendicular to the long axis of the tooth varied among studies. The right and left maxillary incisor, buccal bone thicknesses of males and females did not differ.

Several studies evaluated alveolar ridge thicknesses using CBCT. Zhang *et al.* found that the mean alveolar ridge thickness, and those at the coronal, mid-root,

and apical third of the alveolar bone width of the maxillary, right central incisors, were 9.55,  $8.07 \pm 0.93$ ,  $8.67 \pm 1.62$ , and  $11.91 \pm 2.38$  mm, respectively.<sup>[44]</sup> The alveolar ridge thickness was greater in males,<sup>[44,45]</sup> who impart more biting force using stronger masticatory muscles than females.<sup>[46-48]</sup> Here, the mean alveolar bone thickness was 9.05 mm, and males had thicker bone than females. The mean alveolar bone thickness in males (left incisor 8.88 mm, right incisor 8.85 mm) was significantly greater than in females (left incisor 8.18 mm, right incisor 8.27 mm) (*t*-test,  $P < 0.001$ ).

We found no prior study evaluating the relationship between alveolar and buccal bone thicknesses. Here, the correlation between the mean buccal bone and alveolar ridge thicknesses was not significant for the left and the right, central incisor. The Spearman correlation coefficients were 0.194 and 0.191 for the left and right central incisors, respectively.

To identify the correlation between buccal bone and alveolar bone thickness, a power analysis test was performed. The result of power analysis was detected for the left and right sides as 0.4104399 and 0.3997926, respectively. According to this result, we can report that there is a weak correlation between buccal and alveolar bone thickness.

## CONCLUSION

The mean thicknesses of the alveolar ridge near the left and right central incisors did not differ significantly, but the bone was thicker in males than females. The mean alveolar and buccal bone thicknesses were positively correlated, and the statistical analysis demonstrated that the correlation of between the mean alveolar and buccal bone thicknesses is not significant. As our sample size was relatively small, further studies are recommended.

## Financial support and sponsorship

Nil.

## Conflicts of interest

There are no conflicts of interest.

## REFERENCES

- Schneider R. Prosthetic concerns about atrophic alveolar ridges. *Postgrad Dent* 1999;6:3-7.
- Branemark PI, Adell R, Breine U, Hansson BO, Lindström J, Ohlsson A, *et al.* Intra-osseous anchorage of dental prostheses. I. Experimental studies. *Scand J Plast Reconstr Surg* 1969;3:81-100.
- Schulte W, Kleineikenscheidt H, Lindner K, Schareyka R. The Tübingen immediate implant in clinical studies. *Deutsche zahnärztliche Zeitschrift*. 1978;33:348-59.
- Araujo MG, Sukekava F, Wennstrom JL, Lindhe J. Ridge alterations following implant placement in fresh extraction sockets: An experimental study in the dog. *J Clin Periodontol* 2005;32:645-52.

5. de Oliveira RC, Leles CR, Normanha LM, Lindh C, Ribeiro-Rotta RF. Assessments of trabecular bone density at implant sites on CT images. *Oral Surg Oral Med Oral Pathol Oral Radiol Endod* 2008;105:231-8.
6. Roze J, Babu S, Saffarzadeh A, Gayet-Delacroix M, Hoornaert A, Layrolle P, *et al.* Correlating implant stability to bone structure. *Clin Oral Implants Res* 2009;20:1140-5.
7. Eufinger H, König S, Eufinger A, Machtens E. Significance of the height and width of the alveolar ridge in implantology in the edentulous maxilla. Analysis of 95 cadaver jaws and 24 consecutive patients. *Mund Kiefer Gesichtschir* 1999;3(Suppl 1):S14-8.
8. Lekovic V, Camargo PM, Klokkevold PR, Weinlaender M, Kenney EB, Dimitrijevic B, *et al.* Preservation of alveolar bone in extraction sockets using bioabsorbable membranes. *J Periodontol* 1998;69:1044-9.
9. Schropp L, Wenzel A, Kostopoulos L, Karring T. Bone healing and soft tissue contour changes following single-tooth extraction: A clinical and radiographic 12-month prospective study. *Int J Periodontics Restorative Dent* 2003;23:313-23.
10. Irinakis T. Rationale for socket preservation after extraction of a single-rooted tooth when planning for future implant placement. *J Can Dent Assoc* 2006;72:917-22.
11. Sadan A, Blatz MB, Salinas TJ, Block MS. Single-implant restorations: A contemporary approach for achieving a predictable outcome. *J Oral Maxillofac Surg* 2004;62(9 Suppl 2):73-81.
12. Gamborena I, Blatz MB. Transferring the emergence profile of single-tooth implant restorations. *Quintessence Dent Technol* 2004;27:119-32.
13. Januario AL, Duarte WR, Barriviera M, Mesti JC, Araújo MG, Lindhe J, *et al.* Dimension of the facial bone wall in the anterior maxilla: A cone-beam computed tomography study. *Clin Oral Implants Res* 2011;22:1168-71.
14. Katranji A, Misch K, Wang HL. Cortical bone thickness in dentate and edentulous human cadavers. *J Periodontol* 2007;78:874-8.
15. Evans CD, Chen ST. Esthetic outcomes of immediate implant placements. *Clin Oral Implants Res* 2008;19:73-80.
16. Engelke W, Beltrán V, Fuentes R, Decco O. Endoscopically assisted root splitting (EARS): Method and first results. *Int J Odontostomatol* 2012;6:313-6.
17. Pietrokovski J, Massler M. Alveolar ridge resorption following tooth extraction. *J Prosthet Dent* 1967;17:21-7.
18. Worthington P, Rubenstein J, Hatcher DC. The role of cone-beam computed tomography in the planning and placement of implants. *J Am Dent Assoc* 2010;141(Suppl 3):19s-24s.
19. Danforth RA, Dus I, Mah J. 3-D volume imaging for dentistry: A new dimension. *J Calif Dent Assoc* 2003;31:817-23.
20. Van Assche N, van Steenberghe D, Guerrero ME, Hirsch E, Schutyser F, Quirynen M, *et al.* Accuracy of implant placement based on pre-surgical planning of three-dimensional cone-beam images: A pilot study. *J Clin Periodontol* 2007;34:816-21.
21. Wilson DJ. Ridge mapping for determination of alveolar ridge width. *Int J Oral Maxillofac Implants*. Spring 1989;4:41-3.
22. Bousquet F, Bousquet P, Vazquez L. Transtomography for implant placement guidance in non-invasive surgical procedures. *Dentomaxillofac Radiol* 2007;36:229-33.
23. Chen LC, Lundgren T, Hallstrom H, Chereh F. Comparison of different methods of assessing alveolar ridge dimensions prior to dental implant placement. *J Periodontol* 2008;79:401-5.
24. Mootha A, Malaiappan S, Varghese SS, Jayakumar ND, Karthikeyan G. Comparison of various techniques for measuring alveolar ridge dimensions prior to implant placement-A pilot study. *J Pharm Res* 2015;9:593-6.
25. Chugh A, Bhisnoi P, Kalra D, Maggu S, Singh V. Comparative evaluation of three different methods for evaluating alveolar ridge dimension prior to implant placement: An *in vivo* study. *J Dent Implants* 2013;3:101-10.
26. Castro-Ruiz CT, Noriega J, Guerrero ME. Validity of ridge mapping and cone beam computed tomography in dental implant therapy. *J Indian Soc Periodontol* 2015;19:290-3.
27. Eachempati P, Vynne OJ, Annishka A, Fickry FSS, Naurah MA, Idiculla JJ, *et al.* A Comparative Cross-Sectional study of pre-implant site assessment using ridge mapping and orthopantomography (OPG) with cone beam computed tomography (CBCT). *Res J Pharm Biol Chem Sci* 2016;7:1185-92.
28. Botticelli D, Renzi A, Lindhe J, Berglundh T. Implants in fresh extraction sockets: A prospective 5-year follow-up clinical study. *Clin Oral Implants Res* 2008;19:1226-32.
29. Soydan SS, Cubuk S, Oguz Y, Uckan S. Are success and survival rates of early implant placement higher than immediate implant placement? *Int J Oral Maxillofac Surg* 2013;42:511-5.
30. Lang NP, Pun L, Lau KY, Li KY, Wong MC. A systematic review on survival and success rates of implants placed immediately into fresh extraction sockets after at least 1 year. *Clin Oral Implants Res* 2012;23(Suppl 5):39-66.
31. Lee CT, Chiu TS, Chuang SK, Tarnow D, Stoupe J. Alterations of the bone dimension following immediate implant placement into extraction socket: Systematic review and meta-analysis. *J Clin Periodontol* 2014;41:914-26.
32. Chen ST, Darby IB, Reynolds EC. A prospective clinical study of non-submerged immediate implants: Clinical outcomes and esthetic results. *Clin Oral Implants Res* 2007;18:552-62.
33. AlTarawneh S, AlHadidi A, Hamdan AA, Shaqman M, Habib E. Assessment of Bone dimensions in the anterior maxilla: A cone beam computed tomography study. *J Prosthodont* 2018;27:321-8.
34. Dave BH SS, Mehta S, Shah P, Prajapati T, Asnani M. A comparative study of three different methods for evaluating width of alveolar ridge prior to implant placement: An *in vivo* study. *Int J Oral Care Res* 2017;5:53-60.
35. ten Bruggenkate CM, de Rijke TB, Kraaijenhagen HA, Oosterbeek HS. Ridge mapping. *Implant Dent* 1994;3:179-82.
36. Vera C, De Kok IJ, Reinhold D, Limpiphitanakorn P, Yap AK, Tyndall D, *et al.* Evaluation of buccal alveolar bone dimension of maxillary anterior and premolar teeth: A cone beam computed tomography investigation. *Int J Oral Maxillofac Implants* 2012;27:1514-9.
37. El Nahass H, Naiem SN. Analysis of the dimensions of the labial bone wall in the anterior maxilla: A cone-beam computed tomography study. *Clin Oral Implants Res* 2015;26:e57-61.
38. Ghassemian M, Nowzari H, Lajolo C, Verdugo F, Pirroni T, D'Addona A, *et al.* The thickness of facial alveolar bone overlying healthy maxillary anterior teeth. *J Periodontol* 2012;83:187-97.
39. Zekry A, Wang R, Chau AC, Lang NP. Facial alveolar bone wall width-a cone-beam computed tomography study in Asians. *Clin Oral Implants Res* 2014;25:194-206.
40. Braut V, Bornstein MM, Belsler U, Buser D. Thickness of the anterior maxillary facial bone wall-a retrospective radiographic study using cone beam computed tomography. *Int J Periodontics Restorative Dent* 2011;31:125-31.
41. Fuentes R, Flores T, Navarro P, Salamanca C, Beltrán V, Borie E, *et al.* Assessment of buccal bone thickness of aesthetic maxillary region: A cone-beam computed tomography study. *J Periodontol* 2015;45:162-8.

42. Nowzari H, Molayem S, Chiu CH, Rich SK. Cone beam computed tomographic measurement of maxillary central incisors to determine prevalence of facial alveolar bone width  $\geq 2$  mm. *Clin Implant Dent Relat Res* 2012;14:595-602.
43. Wang HM, Shen JW, Yu MF, Chen XY, Jiang QH, He FM, *et al.* Analysis of facial bone wall dimensions and sagittal root position in the maxillary esthetic zone: A retrospective study using cone beam computed tomography. *Int J Oral Maxillofac Implants* 2014;29:1123-9.
44. Zhang W, Skrypczak A, Weltman R. Anterior maxilla alveolar ridge dimension and morphology measurement by cone beam computerized tomography (CBCT) for immediate implant treatment planning. *BMC Oral Health* 2015;15:65.
45. Braut V, Bornstein MM, Lauber R, Buser D. Bone dimensions in the posterior mandible: A retrospective radiographic study using cone beam computed tomography. Part 1--analysis of dentate sites. *Int J Periodontics Restorative Dent* 2012;32:175-84.
46. Braun S, Hnat WP, Freudenthaler JW, Marcotte MR, Hönigle K, Johnson BE, *et al.* A study of maximum bite force during growth and development. *Angle Orthod* 1996;66:261-4.
47. Usui T, Uematsu S, Kanegae H, Morimoto T, Kurihara S. Change in maximum occlusal force in association with maxillofacial growth. *Orthod Craniofac Res* 2007;10:226-34.
48. Al-Amery SM, Nambiar P, Jamaludin M, John J, Ngeow WC. Cone beam-computed tomography assessment of the maxillary incisive canal and foramen: Considerations of anatomical variations when placing immediate implants. *PLoS One* 2015;10:e0117251.

