

## Original Article

# Diagnostic Value of Transvaginal Four-Dimensional Hysterosalpingo-Contrast Sonography Combined with Recanalization in Patients with Tubal Infertility

YB Gao\*, JH Yan\*, YD Yang<sup>1</sup>, J Sun, JY Dong, GH Cui

Departments of Ultrasound and <sup>1</sup>Obstetrics and Gynecology, Binzhou Medical University Hospital, Binzhou, China

\*Both authors contributed equally to this work.

**Date of Acceptance:**  
19-Oct-2018

## INTRODUCTION

Infertility is a growing problem of global proportions and can affect both men and women.<sup>[1,2]</sup> Of particular concern are factors related to the environment and population, as well as issues relating to food safety and the rising incidence of pathological conditions affecting the reproductive system.<sup>[2,3]</sup> The World Health Organization (WHO) recently recognized infertility as a disease of the reproductive system defined by the failure to achieve a clinical pregnancy after 12 months or more of regular unprotected sexual intercourse.<sup>[4,5]</sup> Approximately 30% of female infertility is associated with pathology of the fallopian tubes.<sup>[6]</sup> Consequently, the accurate evaluation of tubal patency is of significant benefit in deciding an appropriate course of clinical management.

## ABSTRACT

**Background:** A retrospective study was designed to evaluate the diagnostic value of transvaginal four-dimensional hysterosalpingo-contrast sonography (TVS 4D-HyCoSy) combined with recanalization versus laparoscopy for patients with tubal infertility. **Materials and Methods:** A total of 195 patients undergoing TVS 4D-HyCoSy were analyzed retrospectively. Of these, 72 patients underwent laparoscopy, which was the gold standard. The endpoints were coincidence rate (defined as a parameter consistent with results arising from TVS 4D-HyCoSy and laparoscopic examination using dye), sensitivity, specificity, positive predictive value, negative predictive value, and Youden index for TVS 4D-HyCoSy. **Results:** A total of 385 fallopian tubes were assessed by TVS 4D-HyCoSy, of which 147 (38.2%) were tubal patency, 178 (46.2%) as partial tubal obstruction, and 60 (15.6%) as complete tubal obstruction. Of 195 patients, 72 patients with 144 fallopian tubes underwent laparoscopy and a total coincidence rate of 90.97% compared with TVS 4D-HyCoSy. The sensitivity, specificity, positive predictive value, negative predictive value, and Youden index for 4D-HyCoSy versus laparoscopy were 97.7%, 86.7%, 98.4%, 81.3%, and 0.84, respectively. **Conclusions:** TVS 4D-HyCoSy represents a highly useful method for diagnosing tubal patency. However, further large-scale studies are warranted to investigate our findings in patients with tubal infertility.

**KEYWORDS:** Four-dimensional, laparoscopy SonoVue, recanalization, tubal infertility


Common methods used to evaluate tubal patency include tubal hydrotubation, hysterosalpingography (HSG), transvaginal two-dimensional and three-dimensional hysterosalpingo-contrast sonography, hysteroscopy, and laparoscopy. Tubal hydrotubation has strong subjectivity and a high rate of misdiagnosis.<sup>[2]</sup> HSG is generally more reliable<sup>[7]</sup> but cannot be applied to patients who are allergic to iodine, and high levels of resistance may be encountered due to temporary spasms.<sup>[8]</sup> On the other hand,

**Address for correspondence:** Dr. GH Cui, Department of Ultrasound, Binzhou Medical University Hospital, 661 Yellow River Road, Binzhou - 256603, China. E-mail: tgsciczr2016@163.com

This is an open access journal, and articles are distributed under the terms of the Creative Commons Attribution-NonCommercial-ShareAlike 4.0 License, which allows others to remix, tweak, and build upon the work non-commercially, as long as appropriate credit is given and the new creations are licensed under the identical terms.

**For reprints contact:** reprints@medknow.com

**How to cite this article:** Gao YB, Yan JH, Yang YD, Sun J, Dong JY, Cui GH. Diagnostic value of transvaginal four-dimensional hysterosalpingo-contrast sonography combined with recanalization in patients with tubal infertility. *Niger J Clin Pract* 2019;22:46-50.

| Access this article online  |   |
|---|---|
| Quick Response Code:  | Website: <a href="http://www.njcponline.com">www.njcponline.com</a> |
|  | DOI: 10.4103/njcp.njcp_376_17                                       |

transvaginal two-dimensional hysterosalpingo-contrast sonography (TVS 2D-HyCoSy) and transvaginal three-dimensional hysterosalpingo-contrast sonography (TVS 3D-HyCoSy) are widely considered to be noninvasive, safe, accurate, and reproducible.<sup>[9]</sup> However, it is not possible to use TVS 2D-HyCoSy to observe the entire fallopian tube in one plane, and the efficacy of this methodology relies heavily upon the proficiency of the doctor performing the technique.<sup>[10]</sup> Although 3D-HyCoSy can achieve the entire fallopian tube,<sup>[9]</sup> it only provides a limited amount of information.<sup>[10]</sup> In contrast, four-dimensional (4D)-HyCoSy can avoid the above shortcomings<sup>[11,12]</sup> and can be used among infertile women.<sup>[13]</sup>

In the present study, we retrospectively analyzed 195 infertile female patients undergoing transvaginal four-dimensional HyCoSy (TVS 4D-HyCoSy), and evaluated the diagnostic value of TVS 4D-HyCoSy combined with recanalization in providing evidence-based medical evidence and the clinical application of this new methodology for patients with tubal infertility.

## MATERIALS AND METHODS

### Study design

This retrospective study was conducted in Binzhou Medical University Hospital between October 2014 and November 2016. The study was approved by the Institutional Review Board of Binzhou Medical University Hospital and all participants gave written informed consent before the study began. We had access to information which could identify individual participants during or after data collection.

### Subjects

In total, 195 female patients were included in our study, some with primary infertility and some with secondary infertility. All the patients attended infertility clinics and underwent TVS 4D-HyCoSy. Patients were included if they had been diagnosed with tubal infertility, and excluded if they were suffering from acute or chronic inflammation of the reproductive system, infertility associated with the ovary or uterus, or if the involvement of a male factor was suspected. All patients had undergone TVS 4D-HyCoSy examinations 3~7 days after menstruation during sexual abstinence. Within 3 months of examination, 72 cases underwent dye hydrotubation-based laparoscopy.

### Equipment and reagents

Patients were examined with a VolusonE8 color Doppler (GE Healthcare, Zipf, Austria) ultrasonic diagnostic system equipped with image coding

technology and an RIC5-9-D volume probe (5–9 MHz) with a mechanical index of 0.12~0.18. We also used a laparoscope system (Olympus, Tokyo, Japan).

The primary reagents included SonoVue (Bracco International BV, Amsterdam, The Netherlands), a bespoke mixture, and methylene blue. A microbubble suspension was prepared in advance by injecting 5 ml of saline into the SonoVue preparation. Prior to salpingography, 2 ml of microbubble suspension was extracted and mixed with 18 ml of saline. Our bespoke mixture was composed of 80000 U gentamicin, 2.5 mg dexamethasone, 50 mg lidocaine, 0.25 mg atropine, and 10 ml saline. Methylene blue was used as a dye for hydrotubation during laparoscopy.

### Study interventions

Atropine (0.5 mg) was injected intramuscularly half an hour prior to examination, and patients were encouraged to empty their bladder. Next, we observed the uterus and bilateral ovaries by transvaginal ultrasound in the lithotomy position to check for the presence of lesions, and determine their location, mobility, and for the involvement of pelvic fluid. Following perineum disinfection, a speculum was used to expose and fix the cervix, and a disposable catheter was placed into the uterine cavity for double-cavity uterine tubal angiography. After 1.5 ~ 2.0 ml of saline was injected into the uterine water sac, the internal orifice of the blocked cervix was pulled down. Then, 5 ml of the bespoke mixture was injected through the catheter to estimate intrauterine pressure and investigate the presence of intrauterine adhesions or occupying lesions. A 3D model with a sector angle of 179° and a volume angle of 120° was deployed for a prescan. The 4D-HyCoSy state was commenced after the area of interest showed in the volume box. We recorded a range of factors, including the flow of contrast agent inside the uterus and both fallopian tubes, as well as the dispersion of microbubbles around the ovary and in the pelvic cavity. 3D scanning and 2D ultrasonography were carried out immediately after 4D scanning to observe the distribution of the contrast agent around the ovary, uterus, and pelvic cavity. Finally, the excretion of contrast agent in patients was accelerated and the catheter was removed. Following a period of rest, patients without discomfort were allowed to leave as long as they were accompanied by family members. Subsequently, the stored volume images were replayed frame-by-frame for analysis and reconstruction purposes.

Seventy-two patients with bilateral or unilateral (proximal) tubal obstruction were subjected to laparoscopy by dye hydrotubation over a period of 3 months to assess the coincidence rate. Following

endotracheal intubation and general anesthesia, we first inserted a laparoscope to evaluate the pelvic cavity. Then, 5–10 ml of methylene blue solution was pushed forward through a balloon initially placed at the cervix to observe tubal patency. Our observation results were divided into three categories.<sup>[14]</sup>

TVS 4D-HyCoSy and laparoscopy were carried out and evaluated by two experienced doctors.

### Evaluation criteria for tubal patency using TVS 4D-HyCoSy

The evaluation method for tubal patency using TVS 4D-HyCoSy involved three criteria: tubal patency, partial tubal obstruction, and complete tubal obstruction. Detailed evaluation methodology is provided in Table 1.

#### Endpoints

The endpoints were coincidence rate (defined as a parameter consistent with results arising from 4D-HyCoSy and laparoscopic examination using dye), sensitivity, specificity, positive predictive value, negative predictive value, and Youden index for 4D-HyCoSy.

#### Adverse effects

We used the scale of Stacey<sup>[15]</sup> for pain measurement during examination in the present study. In detail, the scale were follows as: (a) 0, no reaction or discomfort; (b) 1, slight pain, less than or the same as menstrual pain; (c) 2, moderate pain, exceeding menstrual cramps but no vasovagal reaction; (d) 3, slight vasovagal reaction not requiring observation in a hospital; (e) 4, severe vasovagal reaction or pain requiring observation in a hospital; and (f) 5, vasovagal reaction or pain requiring resuscitation.

#### Statistical analysis

All statistical analyses were conducted using SPSS version 18.0 software for Windows (SPSS Inc, Chicago, IL). All data are presented as means, standard deviations, and percentages. The Kappa coefficient test was utilized for pairing count data. A *P* value of <0.05 was considered as being statistically significant.

## RESULTS

### Sample characteristics

In total, 195 infertile patients, aged 20–42 years (mean = 29.5 ± 4.5 years) were analyzed during the present study. The duration of infertility was 0.5–15 years, with a mean duration of 3.5 ± 3.2 years. Of these cases, 58 were diagnosed with primary infertility (20–37 years of age with a mean of 27.7 ± 4.2 years), whereas 137 cases were diagnosed with secondary infertility (21–42 years of age with a mean of 30.7 ± 4.2 years).

### Endpoints

From 195 infertile patients, unilateral fallopian tubes were resected in five and 385 tubes were inspected by TVS 4D-HyCoSy in total. Of 385 tubes, 147 (38.2%) were unobstructed tubes, 178 (46.2%) as partially passable tubes, and 60 (15.6%) as completely obstructed tubes. Of 60 tubes, 53 tubes were obstructed at the proximal end whereas 7 tubes were obstructed at the mid-distal end. Table 2 and Figure 1 depict the results of our tubal patency examination, as carried out by TVS 4D-HyCoSy.

Of 195 patients, 72 patients with 144 fallopian tubes underwent laparoscopy and a total coincidence rate of 90.97% compared with TVS 4D-HyCoSy [Table 3]. Our data showed high consistency in the tubal patency of 72 patients, as observed by both TVS 4D-HyCoSy and dye hydrotubation-based laparoscopy ( $k = 0.844$ ,  $P < 0.001$ ). When laparoscopic tubal examination was regarded as the standard technique, our data showed that the sensitivity, specificity, positive predictive value, negative predictive value, and Youden index for 4D-HyCoSy versus laparoscopy were 97.7%, 86.7%, 98.4%, 81.3%, and 0.84, respectively.

#### Adverse effects

Of 195 patients, 23 cases (11.79%) had no obvious pain, 137 cases (70.25%) felt mild pain, which was slighter than or equal to dysmenorrhea, 31 cases (15.90%) felt

**Table 1: Evaluation criteria for tubal patency using TVS 4D-HyCoSy**

| Tubal patency situation    | Method or evaluation criteria  |
|----------------------------|--|
| Tubal patency              | No resistance and reflux during the injection of contrast agent; smooth uterine cavity; naturally contorted fallopian tubes with uniform diameter; contrast agent moving to the fimbriae and then flowing radial or flaky into the pelvic cavity; strong circular contrast agent-induced echo belt observed around the ovary; uniform dispersion of contrast agent in the rectouterine pouch and intestinal clearance  |
| Partial tubal obstruction  | Resistance and a small amount of reflux during the injection of contrast agent; slow flow of contrast agent in the uterine cavity; interrupted development in the fallopian tubes which were narrowed or presented with local nodules; apparent tortuous tubal course or angulation; a small amount of contrast agent overflowing from the fimbriae; strong semicircular contrast agent-induced echo belt observed around the ovary; small distribution of contrast agent in the rectouterine pouch and intestinal clearance |
| Complete tubal obstruction | Significant resistance during the injection of contrast agent with almost complete reflux following injection; plump uterine cavity; no development or only partial development of the fallopian tubes; lack of contrast agent overflowing from the fimbriae; lack of a strong contrast agent-induced echo belt surrounding the ovary with no contrast agent-induced echo in the pelvic cavity   |

TVS 4D-HyCoSy=Transvaginal four-dimensional hysterosalpingo-contrast sonography

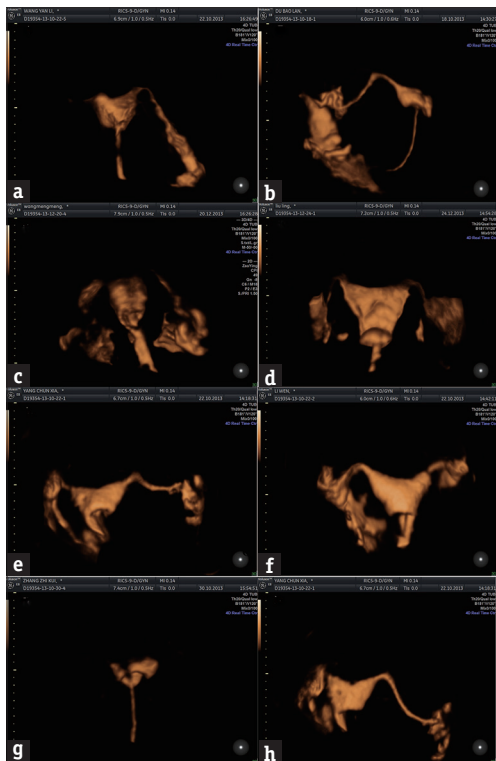
moderate pain, the degree of which was higher compared with dysmenorrhea, but with no vasovagal response, and 4 cases (0.02%) felt severe pain with vasovagal responses, or remained in the ward under observation for severe pain. None of the patients experienced serious complications.

## DISCUSSION

The present retrospective study evaluated the diagnostic value of TVS 4D-HyCoSy combined with recanalization in patients with tubal infertility. The results showed that TVS 4D-HyCoSy represented a total coincidence rate of 90.97% compared with laparoscopy. The sensitivity, specificity, positive predictive value, negative predictive value, and Youden index for TVS 4D-HyCoSy versus laparoscopy were 97.7%, 86.7%, 98.4%, 81.3%, and 0.84, respectively.

In the present study, SonoVue was injected transvaginally into the uterine cavity to expand the originally closed uterine cavity and fallopian tubes prior to TVS 4D-HyCoSy ultrasonic imaging. TVS 4D-HyCoSy can provide a real-time and intuitive image of the whole process as the catheter moves from the uterine cavity and into the fallopian tubes. This method can provide doctors with dynamic 3D images of the shape of uterine cavity and fallopian tubes, the degree of tubal patency, the obstruction site, and the relative dispersion of contrast agent into the pelvic cavity. The best acquisition and viewing angles can also be selected by rotating the viewing plane according to specific circumstances during real-time scanning to acquire the very best images of the fallopian tubes. To acquire more comprehensive diagnostic information, 2D and 3D scanning can also be carried out immediately after 4D-HyCoSy. Thus, we can make further observations of the entire tubal course and assess whether contrast agents overflow into the pelvic cavity. This avoids making incorrect judgements caused by the fimbrial obstruction of the ipsilateral fallopian tubes and whether contrast agent is dispersed in the contralateral tube. Consequently, the time required to acquire and reconstruct images is reduced because of the application of real-time 4D imaging methodology and volume probes. Further observation and analysis can then be performed after the examination by playing back stored images, and therefore the relative dependence upon operator technology is reduced.

In the present study, 23 patients showed significant resistance to the initial injection of contrast agent, indicating the presence of tubal obstruction. This resistance was suddenly reduced when the operator



**Figure 1:** Representative examples of tubal patency examination by TVS 4D-HyCoSy: (a) left fallopian tube was partially passable while the right tube was completely obstructed; (b) right fallopian tube was unobstructed and the left was surgically removed; (c) bilateral fallopian tube was partially passable with the presence of intrauterine adhesions; (d) bilateral fallopian tube was partially passable; (e and f) bilateral fallopian tube was unobstructed; (g) proximal fallopian tubes were completely obstructed bilaterally; (h) left fallopian tube was unobstructed while the right was partially passable

**Table 2: Data arising from tubal patency examinations using TVS 4D-HyCoSy (n=385)**

| Tubal patency situation    | Number | Ratio (%) |
|----------------------------|--------|-----------|
| Tubal patency              | 147    | 38.18     |
| Partial tubal obstruction  | 178    | 46.23     |
| Complete tubal obstruction | 60     | 15.58     |

**Table 3: A comparison of tubal patency observations using either TVS 4D-HyCoSy or dye hydrotubation-based laparoscopy (n=144)**

| TVS 4D-HyCoSy              | Laparoscopy   |                           |                            | Total | Coincidence rate (%) | $\chi^2$           | P      |
|----------------------------|---------------|---------------------------|----------------------------|-------|----------------------|--------------------|--------|
|                            | Tubal patency | Partial tubal obstruction | Complete tubal obstruction |       |                      |                    |        |
| Tubal patency              | 13            | 3                         | 0                          | 16    | 81.25                | 0.45               | 0.799  |
| Partial tubal obstruction  | 1             | 70                        | 4                          | 75    | 93.33                | 0.497              | 0.974  |
| Complete tubal obstruction | 1             | 4                         | 48                         | 53    | 90.57                | 0.414              | 0.813  |
| Total                      | 15            | 77                        | 52                         | 144   | 90.97                | 0.844 <sup>#</sup> | <0.001 |

<sup>#</sup>Consistency test Kappa=0.844, P<0.001

slightly increased the injection pressure, and the contrast agent flowed into the tubes and was distributed from the isthmus to the fimbriae, thus proving at least some degree of dispersion. At present this method is mainly used to simultaneously evaluate tubal patency and diagnose uterine cavity lesions. Consequently, this technique is very useful in analyzing the potential causes of female infertility. The implementation of uterine 3D ultrasonography prior to HSG is particularly valuable in diagnosing certain pathological changes. Our present study, however, excluded other factors associated with infertility, which involve the uterus and ovary, such as intrauterine adhesions and uterine malformations. Our data showed that there was no statistically significant difference in terms of tubal patency when compared between TVS 4D-HyCoSy and laparoscopy. Furthermore, TVS 4D-HyCoSy exhibited higher sensitivity and better diagnostic accuracy as well as laparoscopy.

### Limitations

Some limitations should be taken into account in the present study. The gold standard was laparoscopy in our study. However, laparoscopy may not be the ideal reference test. Several previous studies revealed that patent fallopian tubes did not always mean a good pelvic condition on laparoscopy, which can give false-positive results. Even so, the high sensitivity and diagnostic rate of TVS 4D-HyCoSy cannot be denied. Next, of 195 patients, only 72 patients with 144 fallopian tubes underwent laparoscopy after TVS 4D-HyCoSy in our study. The sample size was limited, and therefore further large-scale studies are needed.

### CONCLUSIONS

In summary, TVS 4D-HyCoSy combined with tubal recanalization represents a safe, simple, noninvasive, reproducible, and cost-effective method, which is a potential method in the diagnosis of tubal obstruction. However, further large-scale studies are warranted to investigate our findings in patients with tubal infertility.

### Financial support and sponsorship

This study was supported by the Binzhou City Science and Technology Bureau (Grant Number: 2014ZC0131).

### Conflicts of interest

There are no conflicts of interest.

### REFERENCES

- Mahalingaiah S, Hart JE, Laden F, Farland LV, Hewlett MM, Chavarro J, *et al.* Adult air pollution exposure and risk of infertility in the Nurses' Health Study II. *Hum Reprod* 2016;31:638-47.
- Lindsay TJ, Vitrikas KR. Evaluation and treatment of infertility. *Am Fam Physician* 2015;91:308-14.
- Lewis RC, Hauser R, Maynard AD, Neitzel RL, Wang L, Kavet R, *et al.* Exposure to power-frequency magnetic fields and the risk of infertility and adverse pregnancy outcomes: Update on the human evidence and recommendations for future study designs. *J Toxicol Environ Health B Crit Rev* 2016;19:29-45.
- Che Y, Cleland J. Infertility in Shanghai: Prevalence, treatment seeking and impact. *J Obstet Gynaecol* 2002;22:643-8.
- Montoya JM, Bernal A, Borrero C. Diagnostics in assisted human reproduction. *Reprod Biomed Online* 2002;5:198-210.
- Briceag I, Costache A, Purcarea VL, Cergan R, Dumitru M, Briceag I, *et al.* Fallopian tubes-literature review of anatomy and etiology in female infertility. *J Med Life* 2015;8:129-31.
- Sakar MN, Gul T, Atay AE, Celik Y. Comparison of hysterosalpingography and laparoscopy in the evaluation of infertile women. *Saudi Med J* 2008;29:1315-8.
- Dessole S, Meloni GB, Capobianco G, Manzoni MA, Ambrosini G, Canalis GC. A second hysterosalpingography reduces the use of selective technique for treatment of a proximal tubal obstruction. *Fertil Steril* 2000;73:1037-9.
- Kupescic S, Plavsic BM. 2D and 3D hysterosalpingo-contrast-sonography in the assessment of uterine cavity and tubal patency. *Eur J Obstet Gynecol Reprod Biol* 2007;133:64-9.
- Exacoustos C, Di Giovanni A, Szaboles B, Binder-Reisinger H, Gabardi C, Arduini D. Automated sonographic tubal patency evaluation with three-dimensional coded contrast imaging (CCI) during hysterosalpingo-contrast sonography (HyCoSy). *Ultrasound Obstet Gynecol* 2009;34:609-12.
- He Y, Geng Q, Liu H, Han X. First experience using 4-dimensional hysterosalpingo-contrast sonography with SonoVue for assessing fallopian tube patency. *J Ultrasound Med* 2013;32:1233-43.
- Wang Y, Qian L. Three- or four-dimensional hysterosalpingo contrast sonography for diagnosing tubal patency in infertile females: A systematic review with meta-analysis. *Br J Radiol* 2016;89:20151013.
- Wang W, Zhou Q, Gong Y, Li Y, Huang Y, Chen Z. Assessment of Fallopian Tube Fimbria Patency With 4-Dimensional Hysterosalpingo-Contrast Sonography in Infertile Women. *J Ultrasound Med* 2017;36:2061-9.
- Smit JG, Kasius JC, Eijkemans MJ, Veersema S, Fatemi HM, Santbrink van EJ, *et al.* The international agreement study on the diagnosis of the septate uterus at office hysteroscopy in infertile patients. *Fertil Steril* 2013;99:2108-13.e2102.
- Stacey C, Bown C, Manhire A, Rose D. HyCoSy-as good as claimed? *Br J Radiol* 2000;73:133-6.