

Case Report

Long-term Follow-up and Treatment of a Patient with Severe Skeletal Open Bite Using Temporary Anchorage Devices

WX Lv, S Chen, TM Xu, B Han

Department of Orthodontics, Peking University School and Hospital of Stomatology, National Engineering Laboratory for Digital and Material Technology of Stomatology, Beijing Key Laboratory of Digital Stomatology, Beijing, China

Date of Acceptance:
10-Aug-2018

ABSTRACT This case report presents the treatment and long-term follow-up of a patient with severe skeletal hyperdivergent open bite, Class II malocclusion, and a severely retruded chin. After failure of early treatment using high-pull headgear with a bite block during the early permanent dentition stage due to an unfavorable growth pattern, orthognathic surgery was proposed but rejected by the patient. Then, temporary anchorage devices were used to correct the occlusion and establish an acceptable overbite and overjet. The overall observation time was 8.5 years; the treatment time using fixed appliances was 3 years and 4 months. The achieved tooth position and occlusal relationship remained stable 2.5 years later without recurrence of the open bite.

KEYWORDS: Class II, skeletal open bite, temporary anchorage devices

INTRODUCTION

An anterior open bite is a malocclusion with deviation in the vertical relationship of the maxillary and mandibular dental arches that is characterized by an open vertical dimension between the incisal edges when the posterior teeth are in occlusion. This malocclusion can lead to impairment of masticatory and phonatory function and raises considerable esthetic issues in the affected patients.^[1]

The etiology of anterior open bite varies and includes skeletal, dental, respiratory, neurological, and habitual factors. Here, we broadly describe it as skeletal or dental in origin.^[2] Dental open bite is determined by the result of a mechanical blockage of the vertical development of the incisors and the alveolar component with normal skeletal relationships. In contrast, skeletal open bite is a vertical skeletal discrepancy that can be observed on cephalograms which includes a longer anterior lower face height, shorter posterior face height, shorter 1 to SN (Anterior Cranial Base Plane) distance, smaller 6 to Mandibular Plane (MP) distance, and larger gonial angle.^[3] A steep mandibular plane is always considered to be the key skeletal finding in skeletal anterior open bite.^[4]

Severe open bite malocclusion (negative overbite ≥ 2 mm) is rare in the population. However, its occurrence

varies by race (less than 1% in whites, approximately 5% in blacks).^[5] Severe open bite is considered to be one of the most difficult challenges for orthodontists, particularly when treating it with an orthodontic strategy alone. Controlling the subsequent posterior vertical growth would be the ideal treatment for these patients. Rotating the mandible upward and forward is the goal of treatment, which can be accomplished by controlling all tooth eruption if adequate mandibular vertical ramus growth is achieved.^[5]

During the early treatment of anterior open bite malocclusions, various methods can be used such as deterrent appliances, high-pull headgear, vertical chincups, and posterior bite blocks.^[2] However, these methods are often viewed as controversial, and their efficacies remain unclear.^[1] The reasons for an uncertain curative effect during early treatment have been speculated to include poor patient compliance and the continuation of vertical facial growth throughout the

Address for correspondence: Prof. B Han,

Department of Orthodontics, Peking University School and Hospital of Stomatology, National Engineering Laboratory for Digital and Material Technology of Stomatology, Beijing Key Laboratory of Digital Stomatology, Beijing 100081, China.
E-mail: kqbinghan@bjmu.edu.cn

This is an open access journal, and articles are distributed under the terms of the Creative Commons Attribution-NonCommercial-ShareAlike 4.0 License, which allows others to remix, tweak, and build upon the work non-commercially, as long as appropriate credit is given and the new creations are licensed under the identical terms.

For reprints contact: reprints@medknow.com

How to cite this article: Lv WX, Chen S, Xu TM, Han B. Long-term follow-up and treatment of a patient with severe skeletal open bite using temporary anchorage devices. *Niger J Clin Pract* 2018;21:1678-84.

Access this article online	
Quick Response Code:	Website: www.njcponline.com
	DOI: 10.4103/njcp.njcp_223_18

Table 1: Summary of cephalometric analysis

	Norm	SD	April 05, 2003 Initial	January 15, 2004 Pre I	September 14, 2004 After phase I	September 02, 2010 Adulthood	October 14, 2011 Pre II	May 05, 2015 After phase II	December 15, 2017 Retention
Patient's age			12 years 1 month	12 years 10 months	13 years 6 months	19 years 6 months	20 years 7 months	24 years 2 months	26 years 9 months
SNA (°)	82.8	4.0	79.9	79.5	79.0	79.8	80.34	79.0	78.4
SNB (°)	80.1	3.9	72.8*	72.0*	70.8*	70.6*	72.27*	71.3*	71.3*
ANB (°)	2.7	2.0	7.1*	7.5*	8.2*	9.3*	8.07*	7.7*	7.0*
Facial angle (FH-NPo) (°)	85.4	3.7	82.5	82.8	80.9*	76.7*	76.88*	81.8*	81.9*
Convexity (NA-APo) (°)	6.0	4.4	15.8*	15.2*	16.5*	20.4*	21.69*	21.7*	21.1*
U1-NA (mm)	5.1	2.4	9.3	11.2*	10.9*	8.2	8.08	0.1	1.6
U1-NA (°)	22.8	5.7	32.0	33.8	32.1	29.3	29.39	6.6*	10.9*
L1-NB (mm)	6.7	2.1	11.6*	13.5*	15.2*	11.7*	9.44*	10.0*	9.6*
L1-NB (°)	30.3	5.8	26.4	31.3	34.5	31.0	36.02	41.1*	35.8
Interincisal angle U1-L1 (°)	125.4	7.9	114.5*	107.4*	105.3*	110.4*	106.51*	124.6	126.2
U1-SN (°)	105.7	6.3	112.0	113.4	111.1	109.1	109.73	85.6*	89.3*
MP-SN (°)	32.5	5.2	50.7*	50.5*	53.7*	54.1*	53.35*	53.2*	53.2*
FMA (MP-FH) (°)	31.1	5.6	40.9*	40.1*	43.9*	47.6*	46.66*	40.7*	40.1*
IMPA (L1-MP) (°)	92.6	7.0	82.8	88.7	90.0	86.4	90.41	96.6	91.2
Y-axis - Downs (SGn-FH) (°)	66.3	7.1	68.8*	69.4*	71.6*	76.2*	76.44*	71.4*	71.3*
Pog-NB (mm)	1.0	1.5	-0.4	0.8	0.9	-0.7	-4.36*	-4.2*	-5.6*

*More than two standard deviations away from the normal value. PRE= Pretreatment; SD= Standard deviation. SNA (°), angle between the Sella, Nasion, and Point A. SNB (°), angle between the Sella, Nasion, and Point B. ANB (°), angle between Point A, Nasion, and Point B. Facial angle (°), angle between the Frankfort Plane and the Nasion-Pogonion Plane. Convexity (°), angle between the extending line of Pogonion-Point A Plane and the Nasion-Point A Plane. U1-NA (mm), distance of the most prominent maxillary incisor in relation to the Nasion-Point A Plane. U1-NA (°), angle between the long axis of the most prominent maxillary incisor and the Nasion-Point A Plane. L1-NB (mm), distance of the most prominent mandibular incisor in relation to the Nasion-Point B Plane. L1-NB (°), angle between the long axis of the most prominent mandibular incisor and the Nasion-Point B Plane. U1-L1 (°), angle between the long axes of the most prominent upper and lower incisors. U1-SN (°), angle between the long axis of the most prominent maxillary incisor and the Sella-Nasion Plane. MP-SN (°), angle between Sella-Nasion Plane and Mandibular Plane. FMA (°), angle between the Frankfort Plane and the Mandibular Plane. IMPA (°), angle between the long axis of the most prominent mandibular incisor and the Mandibular Plane. Y-axis (°), angle between Sella-Nasion Plane and Sella-Gnathion Plane. Pog-NB (mm), distance of Pogonion in relation to the Nasion-Point B Plane

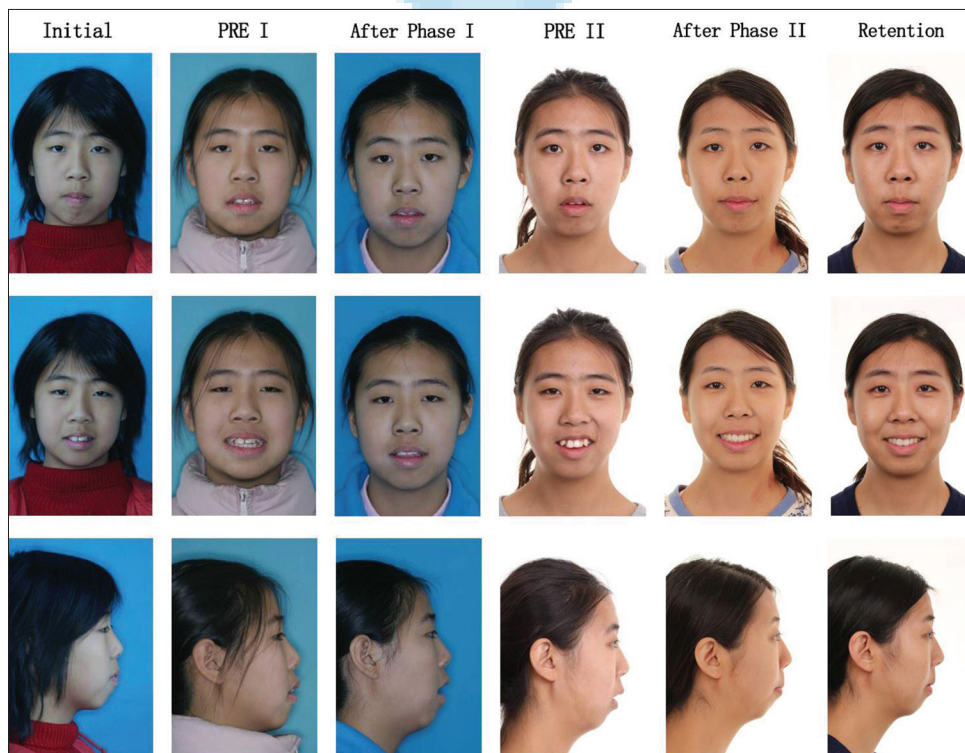


Figure 1: Facial photographs: initial diagnosis, pretreatment I, after phase I, pretreatment II, after phase II, and 2-year retention

Table 2: Measurement of three-dimensional models superimposition

	16				17				26				27			
	MB	DB	ML	DL	MB	DB	ML	DL	MB	DB	ML	DL	MB	DB	ML	DL
Pretreatment	-1.64	-2.35	-2.91	-2.59	-1.59	-1.10	-2.83	-1.10	-1.84	-1.83	-0.32	-1.48	-1.28	-0.32	-2.14	-0.94
Post-treatment	-0.10	0.00	-1.45	-0.51	-0.09	0.44	-1.01	0.59	-1.44	-0.18	-0.36	0.07	0.17	1.93	-0.89	0.50
Molar intrusion (unit: mm)	-1.54	-2.35	-1.46	-2.08	-1.50	-1.54	-1.82	-1.69	-0.40	-1.65	0.04	-1.55	-1.45	-2.25	-1.25	-1.44

16=Upper right first molar; 17=Upper right second molar; 26=Upper left first molar; 27=Upper left second molar; MB=Mesiobuccal cusp tip; DB=Distobuccal cusp tip; ML=Mesiolingual cusp tip; DL=Distolingual cusp tip

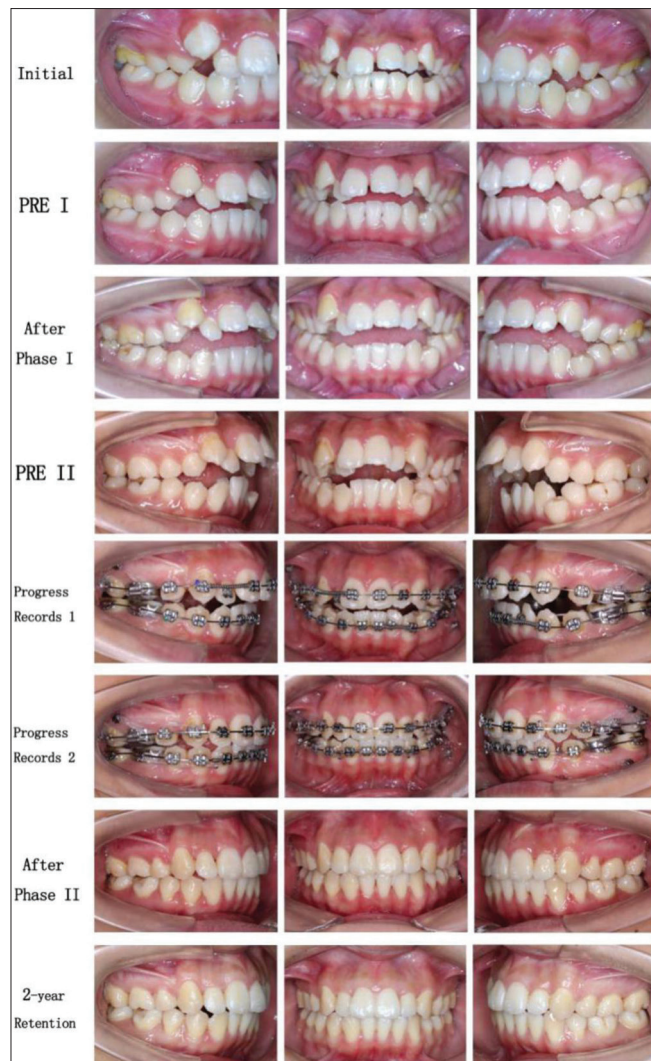

Figure 2: Intraoral photographs: initial diagnosis, pretreatment I, after phase I, pretreatment II, after phase II, and 2-year retention

postadolescent years,^[5] as open bite can presumably become increasingly severe during growth. Therefore, early treatment should be selected cautiously for these patients. Meanwhile, patients should be well informed of the possible need for orthognathic surgery during the later stage to correct the skeletal open bite.

In recent years, temporary anchorage devices (TADs) have been applied successfully in patients with anterior

open bite. These devices can intrude molars to correct open bite regardless of age and without requiring long-term patient compliance. Their advantages for vertical control have been verified, and their relatively simple mechanics and high efficiency made them one of the most popular technologies for open bite correction.^[6,7] Although the surgical option is often considered as the first choice to treat severe skeletal open bite patients, it may still be rejected by some patients and their families due to the relatively high risk and cost. Alternatively, TADs have become a frequently used method to nonsurgically treat anterior open bite.

In this case, a patient with severe anterior open bite was observed and treated for a total duration of 12 years. During this long period, the deformity was observed to deteriorate with the patient's growth, which led to failure of early treatment with high-pull headgear and a bite block during the early permanent dentition stage. After her growth was completed, fixed appliance treatment with TADs, a transpalatal arch (TPA), and a lingual bar was applied and completed successfully.

CASE REPORT

The patient was 12 years old when she first visited our orthodontic clinic with chief complaints of open bite and crooked teeth. The initial clinical examination revealed a convex facial profile, slight anterior open bite (1 mm), and circumoral musculature strain upon lip closure due to a severely retrusive mandible. Midline deviation, facial asymmetry, a constricted maxillary arch, and a congenitally missing lower incisor were observed [Figures 1 and 2 – initial]. A wrist X-ray showed that she was at the peak of growth. Considering the possible deterioration of the open bite with further growth, treatment was postponed, and the patient agreed to be monitored.

After 10 months, the patient returned with a more severe open bite (3 mm), and additional crooked teeth and a clockwise rotated mandible were found [Figures 1 and 2 – pre I]. Although the patient was experiencing peak growth, treatment using high-pull headgear with a posterior bite block was started. The

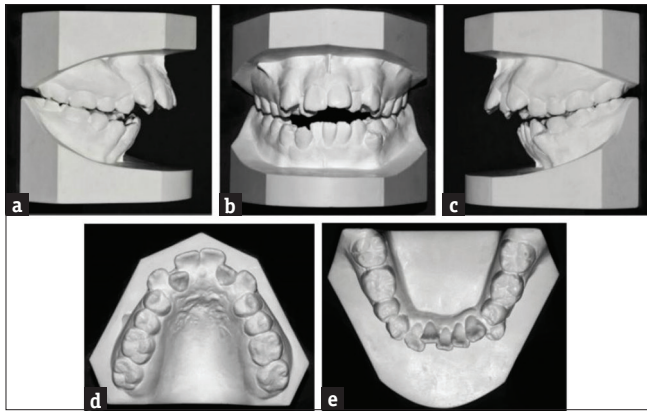


Figure 3: Pretreatment II dental casts (a) right side view; (b) anterior view; (c) left side view; (d) lingual occlusion view of maxillary; (e) lingual occlusion view of mandibular

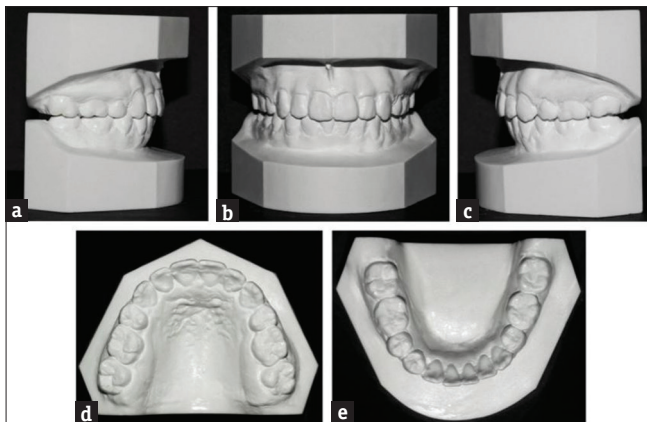


Figure 5: Post-treatment II dental casts (a) right side view; (b) anterior view; (c) left side view; (d) lingual occlusion view of maxillary; (e) lingual occlusion view of mandibular

objective was to prevent posterior vertical maxillary dentoalveolar growth and molar extrusion.

Functional appliance treatment was performed for 1 year and 2 months; however, the efficacy was limited. Due to the backward and downward rotation of the mandible, the anterior open bite increased to 5 mm with a 7-mm anterior overjet [Figures 1 and 2 – after phase I], and anterior overbite greater than 4 mm is an indication of a “very great need for treatment” according to the index of orthognathic functional treatment needs,^[8,9] which is a study that provides useful clinical guidelines to aid in treatment decisions. The patient and her parents were informed of the situation, and orthognathic surgery during adulthood was recommended.

This patient returned at the age of 20. Her dental and skeletal measurements were more severe than 5 years before, and she was still a candidate for orthognathic surgery. However, the patient was still reluctant to consent to surgery. One year later, she decided to

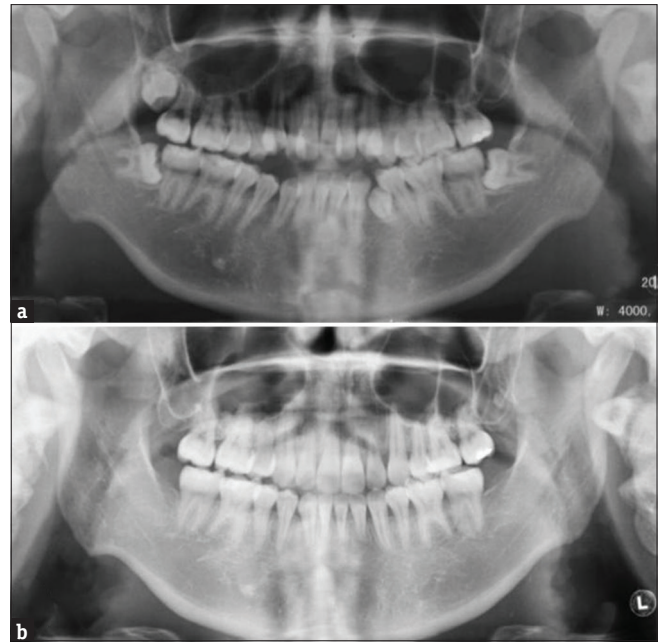


Figure 4: Panoramic radiographs: (a) pretreatment II; (b) post-treatment II

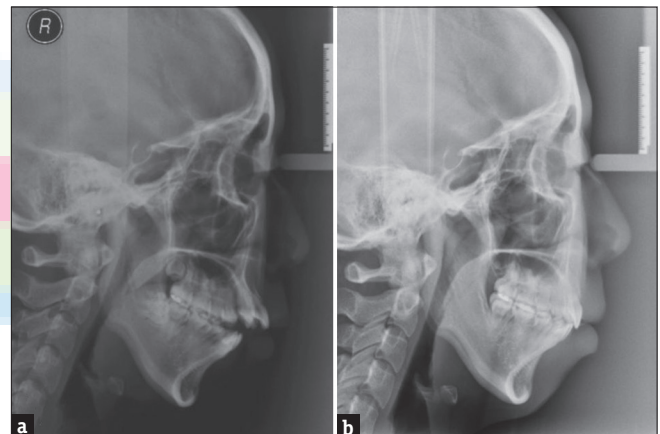


Figure 6: Cephalometric radiographs: (a) pretreatment II; (b) post-treatment II

refuse surgery and received camouflage orthodontic treatment [Figures 1 and 2 – pre II].

Model analysis revealed an arch length discrepancy of 13 mm in the upper arch and 9 mm in the lower arch. Panoramic radiography showed the absence of a lower incisor. The lateral cephalometric measurements indicated a Class II skeletal pattern (ANB 8.07°) with a steep mandibular plane angle (MP/FH 53.35°) and labially inclined upper incisors (U1/NA 29.39°) [Figures 3a-e, 4a, 6a and Table 1].

Combined orthodontic and orthognathic treatment would have been ideal for this patient. However, surgery was refused by the patient. The final treatment plan was as follows: (1) extraction of the upper first premolars and lower left first premolar due to the congenital absence

of a lower incisor; (2) use of a TPA and lingual bar for anchorage control; and (3) placement of TADs on both sides of the posterior maxilla to intrude the molar.

The treatment objectives for this patient were as follows: (1) correct the open bite; (2) bring the teeth into alignment and relieve denture crowding; (3) correct the midline discrepancy; (4) correct the molar relationship; (5) appropriately retract the protruding incisors; (6) intrude the molars; and (7) create an ideal overbite and overjet.

After extraction of the upper first premolars and lower left premolar, preadjusted fixed appliances (0.022 × 0.028 inch) were bonded on both arches with a TPA on the maxillary first molars, and a lingual bar was placed on the mandibular first molars to reinforce anchorage. To level and align both

arches, 0.016-inch nickel-titanium archwires were used [Figure 2 – progress records 1].

After the initial alignment and leveling, 4 self-tapping microscrews (1.6 × 11 mm; Ci Bei, Zhejiang, China) were placed between the roots of first molars and second molars in both arches on the labial side. Then, molar intrusion and canine retraction were initiated using power chains from the TADs. In addition, a TPA was used to maintain palatal cusps of the first molars to guarantee buccopalatal control of molars during the intrusion process.

After 7 months, 0.019 × 0.025-inch stainless steel archwires were placed in both arches. The intrusion of the upper molars was continued using powerchains from the TADs to the archwire. When the overbite became normal, Class II elastics (3/16 inch, 3.5 oz) were worn full time [Figure 2 – progress records 2].

After 2 years of treatment, the extraction space was closed primarily by retraction of the anterior teeth. Next, the lingual bar and the TPA were removed sequentially with a 1-month interval. Then, intermaxillary elastics were used to correct the midline and improve the molar relationship.

At the end of treatment, the occlusion was significantly improved, ideal overjet and overbite were achieved without any Temporomandibular Joint (TMJ) symptoms, and no unfavorable rotation of the mandible was found. Localized surgery on the chin was suggested to further advance the chin after treatment, but it was rejected by the patient. Vacuum-formed retainers were used for retention. The overall active treatment time was 3 years and 4 months [Figures 1 – after phase II, 4b, and 6b].

The post-treatment photographs of the patient showed acceptable esthetic results and considerable improvement of the dental relationships. A Class I molar relationship with normal overbite and overjet was accomplished. The dental midline was coordinated, the mandible was stabilized, and the circumoral musculature showed less strain upon lip closure [Figures 1 and 2 – after phase II].

Cephalometric measurements showed that the ANB angle decreased from 8.07° to 7.7°, and the U1-NA

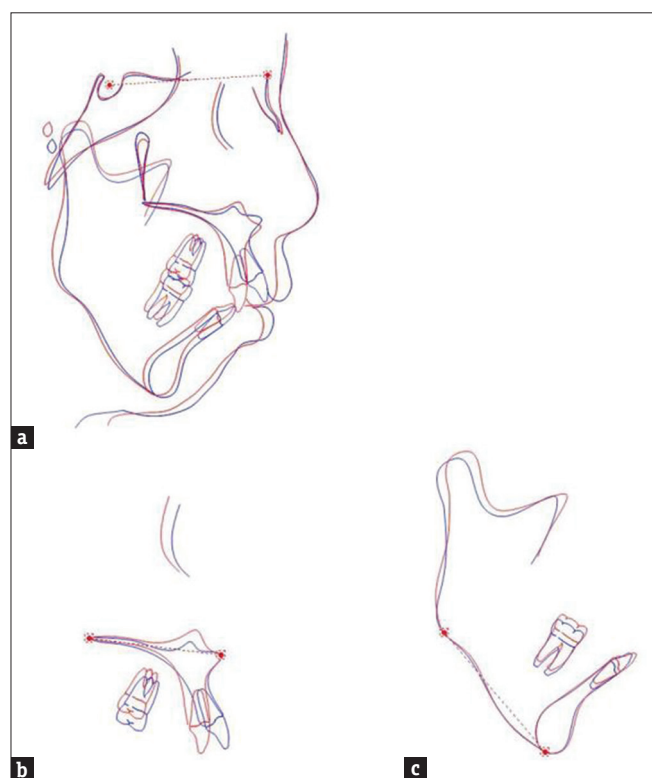


Figure 7: Superimposition of cephalometric tracings before phase II treatment (blue line) and after phase II treatment completion (red line): (a) the SN plane; (b) the maxillary plane; and (c) the mandibular plane

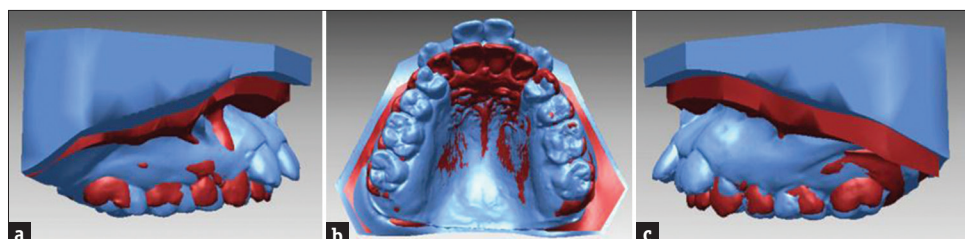


Figure 8: Superimposed dental casts before and after phase II treatment (a) right side view; (b) lingual occlusion view of maxillary; (c) left side view

angle decreased from 8.08° to 0.1° [Table 1]. Meanwhile, the mandibular plane remained stable. Intrusion of the upper molars by TADs was verified by both cephalogram superimposition and digital casts superimposition. The measurement of maxillary molar intrusion relative to the palatal plane is presented [Figures 5a-e, 7a-c, 8a-c and Table 2]. After treatment, the root lengths of the upper incisors were approximately 3 mm shorter than before treatment [Figure 4a,b], which may have been related to the roots themselves due to their initial pipette shapes. Teeth with pipette-shaped roots have been found to have a significantly higher degree of root resorption than teeth with normal root shapes.^[10]

DISCUSSION

This patient first visited our clinic for treatment during her growth peak. Early intervention treatment using high-pull headgear with a posterior bite block was used, but it failed due to the unfavorable growth pattern. Therefore, the treatment was ended until the completion of growth.

When the patient returned at the age of 20, she was a good candidate for orthognathic surgery. However, due to her firm rejection of surgery, orthodontic camouflage treatment was performed as per her request, with the aim of improving her dental relationship. After 3 years and 4 months of treatment, good occlusal results were obtained. Her profile improved but not ideal due to a severe skeletal discrepancy. Orthognathic genioplasty and hyaluronic acid injection were recommended after treatment to further improve the chin prominence, but the patient did not wish to undergo surgery. Two years and seven months after treatment, the occlusion remained stable with a mild relapse of crowding in the lower incisors, and a midline deviation was observed. The mandibular plane was still well maintained, and no recurrence of the open bite was noted [Figure 1 – retention].

Due to its multifactorial etiology and very high relapse rate, skeletal anterior open bite is a challenging problem for orthodontists and has been researched for many years. A series of treatments are performed from the mixed dentition stage to the permanent dentition stage. However, because of a lack of strong scientific evidence, the key issues are the effectiveness and long-term stability of available treatment modalities.^[1,2]

Although some studies have confirmed the effectiveness of early treatment of open bite,^[11-13] most of their success rates were not 100%.^[1] As in our case, a past study found that posterior bite blocks sometimes are not effective for the treatment of patients with an open

bite.^[14] The reason for this result may be the difference in initial severity of the open bite or the growth potential of patients. Due to the continuation of vertical facial growth through adolescence,^[5] observation and appropriately delayed treatment may be a better choice for these patients. Due to a lack of standardization and methodological limitations, treatment options during the early stage are also controversial.^[1]

As defined by Bjork, the tendency of an open bite is in large part synonymous with a backward rotation to mandibular growth in growing patients. In addition, Bjork stated that opening of the bite is difficult to prevent in the case of backward rotation,^[15] which is further corroborated by the data of our case. Because the ideal treatment for these patients is controlling the subsequent posterior vertical growth,^[5] we used TADs to obtain vertical control and avoid the elongation of posterior teeth, which can be observed in three-dimensional model superimpositions [Figure 8a-c]. The use of TADs is the main reason for a lack of counterclockwise mandibular rotation. In the sagittal plane, the use of maximum anchorage produced a pendulum effect that led to an extensive maxillary incisal retrusion [Figure 8a-c], which is also beneficial for avoiding disadvantageous rotation of the mandible, correcting the open bite and improving the profile.

The application of TADs to intrude molars has been confirmed to be an effective method to correct the open bite,^[6,7] but the long-term stability after treatment still lacks evidence. A study observed the long-term stability of anterior open bite correction by intrusion of maxillary posterior teeth with TADs and found a relapse rate of approximately 23% at the 3-year follow-up, and 80% of the relapses occurred during the first year of retention.^[16] In our case, no relapse occurred after the 2-year retention period.

Some researchers have suggested that the increased relapse rate of this type of malocclusion is related to vertical growth abnormalities, the influence of maxillofacial nerves and muscles, oral habits, and changes in alveolar bone without jaw changes.^[17] Because this malocclusion type has such a high relapse rate, observation of long-term stability is needed.

In addition, weak evidence suggests that molar intrusion with microscrews may cause counterclockwise mandibular autorotation, but this phenomenon was not present in our case. The possible cause of this result could be the severity of the open bite, measurement of molar intrusion, or growth potential of patients [Table 1].

It is also worth mentioning that the concept of “an envelope of discrepancy” limits the magnitude of

correction of orthodontic treatment,^[5] in which the soft tissue limitations are not reflected. However, the change in soft tissue is often a very influential factor in patient outcome and satisfaction.^[18] In our case, as shown by the superimposition of the cephalometric tracings, obvious improvement occurred in the upper lip and, to a lesser extent, in the lower lip. In contrast, the chin change was small and negative [Figure 7a]. This result suggests that the chin can be improved only slightly by orthodontic treatment in patients with severe Class II malocclusion. In summary, nonsurgical orthodontic treatment can correct the occlusal relationship to a certain extent, but for patients with severe skeletal deformities, orthodontic–orthognathic therapy is a better option for improvement of facial esthetics.

In conclusion, this case report demonstrates the results of long-term observation and orthodontic camouflage treatment for a patient with a severe skeletal open bite, high angle, skeletal Class II malocclusion, and retrognathic mandible. TADs were used for both vertical and horizontal anchorage control. Good dental results were achieved after 3 years and 4 months of treatment. After 2 years of retention, the treatment outcomes remained stable.

Declaration of patient consent

The authors certify that they have obtained all appropriate patient consent forms. In the form, the patient has given her consent for her images and other clinical information to be reported in the journal. The patient understands that name and initial will not be published and due efforts will be made to conceal identity, but anonymity cannot be guaranteed.

Financial support and sponsorship

This work was supported by grants from the National Natural Science Foundation of China (No. 51672009), Beijing Municipal Natural Science Foundation (No. 7172241).

Conflicts of interest

There are no conflicts of interest.

REFERENCES

1. Pisani L, Bonaccorso L, Fastuca R, Spena R, Lombardo L, Caprioglio A, *et al.* Systematic review for orthodontic and orthopedic treatments for anterior open bite in the mixed

dentition. *Prog Orthod* 2016;17:28.

2. Reichert I, Figel P, Winchester L. Orthodontic treatment of anterior open bite: A review article – Is surgery always necessary? *Oral Maxillofac Surg* 2014;18:271-7.
3. Nahoum HI, Horowitz SL, Benedicto EA. Varieties of anterior open-bite. *Am J Orthod* 1972;61:486-92.
4. Nanda R, Urib F. *Biomechanical and Esthetic Strategies in Clinical Orthodontics*. 2nd ed. America: Elsevier; 2005.
5. Proffit WR, Fields HW, Sarver DM. *Contemporary Orthodontics*. 5th ed. America: Elsevier; 2012. p. 768.
6. Hart TR, Cousley RR, Fishman LS, Tallents RH. Dentoskeletal changes following mini-implant molar intrusion in anterior open bite patients. *Angle Orthod* 2015;85:941-8.
7. Xun C, Zeng X, Wang X. Microscrew anchorage in skeletal anterior open-bite treatment. *Angle Orthod* 2007;77:47-56.
8. Harrington C, Gallagher JR, Borzabadi-Farahani A. A retrospective analysis of dentofacial deformities and orthognathic surgeries using the index of orthognathic functional treatment need (IOFTN). *Int J Pediatr Otorhinolaryngol* 2015;79:1063-6.
9. Borzabadi-Farahani A, Eslamipour F, Shahmoradi M. Functional needs of subjects with dentofacial deformities: A study using the index of orthognathic functional treatment need (IOFTN). *J Plast Reconstr Aesthet Surg* 2016;69:796-801.
10. Levander E, Malmgren O, Eliasson S. Evaluation of root resorption in relation to two orthodontic treatment regimes. A clinical experimental study. *Eur J Orthod* 1994;16:223-8.
11. Doshi UH, Bhad WA. Spring-loaded bite-blocks for early correction of skeletal open bite associated with thumb sucking. *Am J Orthod Dentofacial Orthop* 2011;140:115-20.
12. Cozza P, Baccetti T, Franchi L, Mucedero M. Comparison of 2 early treatment protocols for open-bite malocclusions. *Am J Orthod Dentofacial Orthop* 2007;132:743-7.
13. Mucedero M, Franchi L, Giuntini V, Vangelisti A, McNamara JA Jr, Cozza P, *et al.* Stability of quad-helix/crib therapy in dentoskeletal open bite: A long-term controlled study. *Am J Orthod Dentofacial Orthop* 2013;143:695-703.
14. Iscan HN, Sarisoy L. Comparison of the effects of passive posterior bite-blocks with different construction bites on the craniofacial and dentoalveolar structures. *Am J Orthod Dentofacial Orthop* 1997;112:171-8.
15. Björk A. Prediction of mandibular growth rotation. *Am J Orthod* 1969;55:585-99.
16. Baek MS, Choi YJ, Yu HS, Lee KJ, Kwak J, Park YC, *et al.* Long-term stability of anterior open-bite treatment by intrusion of maxillary posterior teeth. *Am J Orthod Dentofacial Orthop* 2010;138:396.e1.
17. Salehi P, Pakshir HR, Hoseini SA. Evaluating the stability of open bite treatments and its predictive factors in the retention phase during permanent dentition. *J Dent (Shiraz)* 2015;16:22-9.
18. Tulloch JF, Lenz BE, Phillips C. Surgical versus orthodontic correction for class II patients: Age and severity in treatment planning and treatment outcome. *Semin Orthod* 1999;5:231-40.