

Original Article

Incidence of Pyramidal Thyroid Lobe in the University College Hospital Ibadan

OO Ayandipo, OO Afuwape, OY Soneye¹

Department of Surgery,
College of Medicine,
University of Ibadan/
University College Hospital,
¹Department of Surgery,
University College Hospital,
Ibadan, Nigeria

ABSTRACT

Introduction: The pyramidal lobe of the thyroid gland is derived from remnant of the thyroglossal duct. Its presence may be missed clinically; however radiologic and intra-operative findings reveal its presence in up to 50% of cases. The incidence of pyramidal lobe is however not clearly known in Sub-Saharan Africa, particularly in Nigeria. Our aim is to determine the incidence and histological variation of pyramidal lobe of the thyroid gland among surgical patients who underwent thyroid surgery in the University College Hospital, Ibadan. **Methodology:** Consecutive surgical patients that underwent total thyroidectomy in the Endocrine Surgery Division, Department of Surgery, University College Hospital, Ibadan between April 2013 and April 2017 were recruited irrespective of age, sex and clinical diagnosis. The presence, anatomy and subsequent histological diagnosis of the pyramidal lobe were noted. **Results:** One hundred sixty thyroid surgeries were done. Pyramidal lobe was found in 70 patients (44.0%). The presence of the pyramidal lobe was most often associated with multinodular goitres 42 (61.8%) and least found in thyroids with malignant tumours 3 (4.4%). The pyramidal lobe originated commonly from the midline (50.0%) and least from the right (10.3%). The length of the pyramidal lobes ranged from 8 to 80 mm (average 50 mm) in males and 5 to 54 mm (average 42 mm) in females. **Conclusion:** The presence of a pyramidal lobe is not uncommon in people of southwestern Nigeria with its morphologic and histologic profile akin to what obtains in other geographical locations of the world.

KEYWORDS: Goitre, Incidence, Pyramidal Lobe, Thyroidectomy

Date of Acceptance:

01-Aug-2018

INTRODUCTION

Ever since the pyramidal lobe (PL) of the thyroid gland was first described in 1749 by Pierre Lalouette de Vernicourt (gland of Lalouette), its incidence along with its morphological variation (in terms of presence, position, size and extent) have been observed. Embryologically, the PL of the thyroid gland is derived from remnant of the thyroglossal duct situated in the pre-tracheal region between the isthmus and the hyoid bone during the descent of the foetal lingual thyroid to its normal anatomical position in intrauterine life.^[1,2] The PL of the thyroid gland has been regarded both as a normal variant^[3] and an anatomical anomaly.^[4] The PL may originate from the isthmus or on either lobe of thyroid gland,^[5] with a slight predilection for the

left lobe.^[6,7] The PL may be connected to the thyroid cartilage or attached to the hyoid bone^[5] and divided into two or more parts. Variations in its length could be as much as 15–30 mm.^[2] Macroscopically, the PL can be pyramidal, an inverted Y, a nodule, string-like^[5] or flat.^[4] Heterogeneous group of lesions may be found in the PL on histological analysis which may or may not coincide with the pathology in the rest of the thyroid gland.^[4] This spectrum of diseases include diffuse thyroid diseases such as Grave's disease, Hashimoto thyroiditis and focal

Address for correspondence: Dr. OO Ayandipo,

College of Medicine, University of Ibadan, University College Hospital, Ibadan, Nigeria.
E-mail: yokebukola@yahoo.com

This is an open access journal, and articles are distributed under the terms of the Creative Commons Attribution-NonCommercial-ShareAlike 4.0 License, which allows others to remix, tweak, and build upon the work non-commercially, as long as appropriate credit is given and the new creations are licensed under the identical terms.

For reprints contact: reprints@medknow.com

How to cite this article: Ayandipo OO, Afuwape OO, Soneye OY. Incidence of pyramidal thyroid lobe in the university college hospital Ibadan. Niger J Clin Pract 2018;21:1450-3.

Access this article online	
Quick Response Code:	Website: www.njcponline.com
	DOI: 10.4103/njcp.njcp_326_17

thyroid diseases like neoplasms which may be benign or malignant.^[8,9] The presence of a hitherto asymptomatic PL may be missed clinically, however, radiologic investigations and intra-operative exploration reveal its presence in up to 50% of cases.^[2,10]

The incidence of PL is however not known in the Sub-Saharan region in Africa. Our aim is to determine the incidence and histological variation of PL of the thyroid gland among surgical patients who underwent thyroid surgery in the University College Hospital, Ibadan over a specified period.

METHODOLOGY

Consecutive surgical patients that underwent total thyroidectomy in the Endocrine Surgery Division, Department of Surgery, University College Hospital, Ibadan between April 2013 and April 2017 (4-year period) were recruited. Ethical approval was obtained from the ethical review committee and conduct followed the guidelines of the Helsinki declaration on biomedical research in human subject.^[11] During the study, we noted and analysed the occurrence of PL in 160 consecutive total thyroidectomies. The surgeries were chosen independent of sex, age or clinical diagnosis. During this period, all patients with thyroid enlargement or disorders subjected to a total thyroidectomy under the Endocrine Surgery Unit of University College Hospital (UCH), Ibadan were enrolled in this study. Clinical data were obtained from case files, operation notes and histological report.

During the surgical operations, the presence or absence of the PL was noted. The anatomic delineation of the PL identified and the following parameters noted: the point of origin, extent and presence or not of histologically diagnosed disease, draining lymph nodes and vascularity. The length and diameter were measured using a calibrated Bard Parker handle. All procedures were performed by consultant endocrine surgeons in the Endocrine and Hepatobiliary Surgery. Data analysis were done using the Statistical Package for Social Sciences Statistics for Windows, Version 17.0. Chicago.

RESULTS

During this 4-year period, a total of 160 thyroid surgical operations were done. PL was identified in 70 patients (44%). The mean age of the patients was 43.6 years (SD 11.3) with a range of 12–74 years. It was more frequent in females 61 (86.8%) than in males 9 (13.2%). The presence of the PL was most often associated with multinodular goitres in 42 (61.8%) and least found in thyroids with malignant tumours 3 (4.4%) [Table 1]. None of the patients had a preoperative

radiological (ultrasonography) identification of a PL. The Delphian node was found in eight patients (11.8%). Figure 1 shows intraoperative finding of PL originating from the midline.

In 35 patients (50.0%), the PL had its origin from the midline (isthmus), in 28 patients (40.0%), the left of the midline, while the origin was from the right in 7 patients (10.0%) [Table 2]. In 29 patients (42.6%), the thyroid was attached to the levator glandulae superior muscle. There was no malignancy in any of the PL specimens on histology. Diseases found in the PL include: simple multinodular goitre in 34 patients (48.6%), thyroiditis in 3 patients (4.3%),

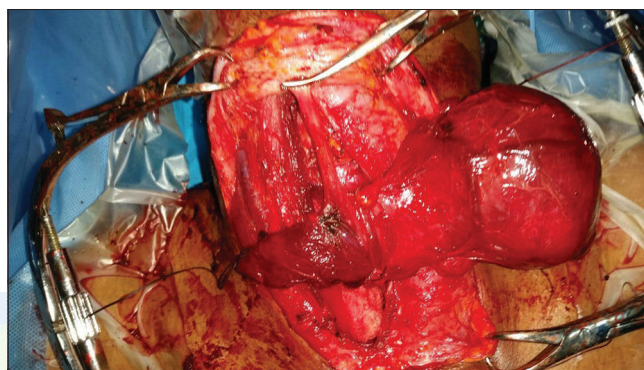


Figure 1: Intra-operative pyramidal lobe dissection

Table 1: Presence of pyramidal lobe in various thyroid diseases

Thyroid disease	Presence of pyramidal lobe (%)
Multinodular goitre	44 (61.8)
Hashimoto's thyroiditis	9 (13.2)
Malignancy (papillary)	3 (4.4)
Graves (primary thyrotoxicosis)	14 (20.6)
Total	70 (100)

Table 2: Frequencies of points of origin of the pyramidal lobe

Point of origin of PL	Frequency (%)
Midline (isthmus)	35 (50.0)
Left of midline	28 (40.0)
Right of midline	7 (10.0)

PL=Pyramidal lobe

Table 3: Involvement of the pyramidal lobe in various thyroid diseases

Thyroid disease	Pyramidal lobe involvement (%)
Multinodular goitre	34 (48.6)
Thyroiditis	3 (4.3)
Grave's disease	11 (15.7)
Normal	22 (31.4)
Total	70 (100)

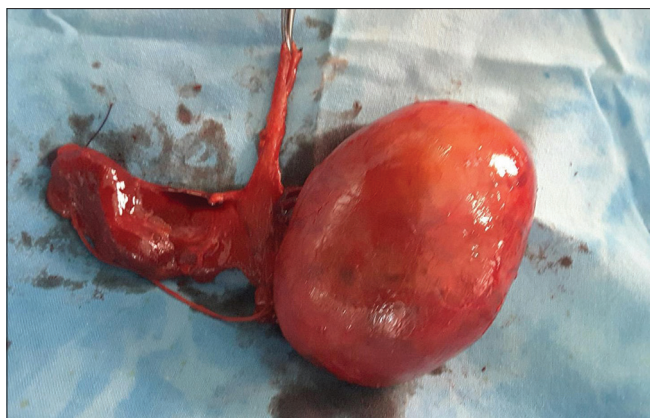

Figure 2: Post-total thyroidectomy picture showing a pyramidal lobe

Graves disease in 11 patients (15.7%) and no disease in the PL of 22 patients (31.4%) [Table 3].

The length of the PL ranged from 8 to 80 mm (average 50 mm) in males and 5 to 54 mm (average 42 mm) in females. Figure 2 shows the post-operative picture of a PL excised along with a total thyroidectomy specimen. The average diameter of the PL was 15 mm (range of 4–20 mm). There was no statistically significant difference in the time it took to complete the surgery between those that had PL and those that did not; neither was there any statistical significance in the estimated blood loss between those that had a PL.

DISCUSSION

Total thyroidectomy is now advocated for most thyroid pathologies.^[12] When considering total thyroidectomy as a treatment option it is pertinent to consider the anatomical variations (including the presence or absence of the PL). This ensures complete surgical extirpation and optimal outcomes when a total thyroidectomy is indicated. Excision of an existing PL is important to the endocrine surgeon firstly, to avoid recurrence due to residual thyroid tissue following incomplete total thyroidectomy.^[5] Secondly it permits the use of adjuvant radioactive iodine therapy in differentiated thyroid cancer as follow-up treatment; which will hitherto not be possible without complete extirpation and thirdly it increases the sensitivity of post-surgical serum thyroglobulin level monitoring in patients with differentiated thyroid cancer as being from a metastatic site only and not from a thyroid gland remnant.^[9]

In our study, the presence of the PL in 43% (68 out of 155) of the cases agrees with Marshall's findings^[13] in North Western Europe and is within the quoted range of 40% and 50.7%. Our finding is however way lower than that indicated by studies done in South Eastern Europe where the PL was found in 55.2%–65% of cases.^[5,9] This could be attributed to the difference

in sample sizes of the various studies and the fact that some of these studies were done on postmortem subjects and not living patients.^[5,9] Our study showed that the PL occurred more frequently in females (86.8%) than in males (13.2%), similar to results obtained by Cengiz *et al.* and Gurleyik *et al.*^[1,2] where 81% and 75.2%, respectively, of the patients with PL were females, respectively. This could be because thyroid pathologies occur mainly in the female gender. This contrasts with the findings of Braun *et al.*^[5] and Geraci *et al.*^[14] that revealed that the appearance of PL is more prevalent in males (62% and 57%, respectively) than in females (50% and 43%, respectively) patients.

Our study's report agrees with Zivic *et al.*^[9] that the PL is more often involved in diffuse thyroid diseases such as multinodular goitre and Grave's disease rather than focal thyroid neoplasms. Geraci *et al.*^[14] in their study also reported that in 77% of the 604 cases, the PL was affected by multinodular goitre. Our study results show that there was no malignancy in any of the PL. This agrees with Ogawa *et al.*^[15] report that thyroid carcinoma rarely arises in the PL. The Delphian node which is said to be the principal draining lymph node of the thyroid gland was found and dissected out in eight patients (11.8%) and it is far lower than 25% that was reported by Geraci *et al.*^[14]

In our study, none of the patients was mentioned to have PL on neck ultrasound. Although computed tomography scan of the neck has been said to be a much better method for detecting PL in living subjects, other researchers however report the pre-operative identification of the PL on ultrasonography within the range of 39.5%–58.5%.^[14,16–18] Our findings of its presence and relevance in thyroid diagnosis and surgeries suggest that radiologists in our geographical location need to look out for the PL and report its radiologic profile as a means of guiding the surgeon who may be inclined to a partial resection initially.

Many authors assert that the most common point of origin is to the left of the isthmus.^[5,9,19] This is not consistent with this study's findings where the most frequent point of origin for PL was the midline (48.5%), in 28 patients (41.2%), the left of the midline while the least origin was from the right 7 patients (10.3%). Similar to our findings, Gurleyik *et al.* reported the highest frequency of origin to be from the midline 52.3%, less commonly from the left and least from the right.^[2] Our study showed that there is no significant difference in thyroidectomy operative time and blood loss between those that had PL and those without it. This is similar to the findings from the study by Geraci *et al.*^[14]

The length of the PL ranged from 8 to 80 mm (mean 42.9 mm) in males and 5 to 54 mm (mean 42 mm) in females. Previous researchers have reported mean lengths to be shorter with a ranges of 23 mm, 25 mm, 27 mm and 29 mm.^[5,9,17] This may indicate that the descent of the thyroid gland in embryonic life deserves to be studied in terms of timing of descent and distance of descent. In conclusion, the presence of a PL is not uncommon in people of southwestern Nigeria with its morphologic and histologic profile akin to what obtains in other geographical locations of the world. The PL was found in almost half of the operated patients and was more common in females. It branched more frequently from the midline and more often involved in diffuse thyroid disease than focal thyroid disease. A missed PL may be associated with recurrent hyperthyroidism following the incomplete resection of the gland. Secondly, it may be the foci of a thyroid cancer, metastasis. In addition, this midline lobe may contain the Delphian lymph node, which is frequently the site of metastasis in thyroid malignancy. It should always be looked for intra-operatively and dissected to its superior extent in total thyroidectomies if found because it may serve as a reservoir of disease if not excised primarily.

Financial support and sponsorship

Nil.

Conflicts of interest

There are no conflicts of interest.

REFERENCES

- Cengiz A, Sakı H, Yürekli Y. Scintigraphic evaluation of thyroid pyramidal lobe. *Mol Imaging Radionucl Ther* 2013;22:32-5.
- Gurleyik E, Gurleyik G, Dogan S, Cobek U, Cetin F, Onsal U. Pyramidal lobe of the thyroid gland: Surgical anatomy in patients undergoing total thyroidectomy. *Anat Res Int* 2015;2015:384148.
- Phukon MJ, Dutta R, Reddy ON, Bhargabhi P, Syed NA. Right sided pyramidal lobe of thyroid gland – A case report. *Int J Biol Med Res* 2012;3:1839-41.
- Sinos G, Sakorafas GH. Pyramidal lobe of the thyroid: Anatomical considerations of importance in thyroid cancer surgery. *Oncol Res Treat* 2015;38:309-10.
- Braun EM, Windisch G, Wolf G, Hausleitner L, Anderhuber F. The pyramidal lobe: Clinical anatomy and its importance in thyroid surgery. *Surg Radiol Anat* 2007;29:21-7.
- Prakash R, Rajini T, Ramachandran A, Savalgi GB, Venkata SP, Mokhasi V, *et al.* Variations in the anatomy of the thyroid gland: Clinical implications of a cadaver study. *Anat Sci Int* 2012; 87:45-9.
- Singh I, Pal GP. The pharyngeal arches In: *Human Embryology*. 8th ed. Macmillan Publishers Hyderabad India Ltd.; 2007. p. 113.
- Spencer RP, Scholl RJ, Erbay N. Tc-99m pertechnetate thyroid images in hyperthyroidism. Size, distribution, and presence of a pyramidal lobe. *Clin Nucl Med* 1997;22:519-22.
- Zivic R, Radovanovic D, Vekic B, Markovic I, Dzodic R, Zivaljevic V. Surgical anatomy of the pyramidal lobe and its significance in thyroid surgery. *S Afr J Surg* 2011;49:110, 112, 114.
- Mortensen C, Lockyer H, Loveday E. The incidence and morphological features of pyramidal lobe on thyroid ultrasound. *Ultrasound* 2014;22:192-8.
- World Medical Association. World Medical Association Declaration of Helsinki. Ethical principles for medical research involving human subjects. *Bull World Health Organ* 2001;79:373-4.
- Efremidou EI, Papageorgiou MS, Liratzopoulos N, Manolas KJ. The efficacy and safety of total thyroidectomy in the management of benign thyroid disease: A review of 932 cases. *Can J Surg* 2009;52:39-44.
- Marshall CF. Variations in the form of the thyroid gland in man. *J Anat Phys* 1895;29:234-9.
- Geraci G, Pisello F, Li Volsi F, Modica G, Sciume C. The importance of pyramidal lobe in thyroid surgery. *Chir Ital* 2008;60:41-6.
- Ogawa C, Kammori M, Onose H, Yamada E, Shimizu K, Yamada T. Follicular carcinoma arising from the pyramidal lobe of the thyroid. *J Nippon Med Sch* 2009;76:169-72.
- Kim DW, Jung SL, Kim J, Ryu JH, Sung JY, Lim HK, *et al.* Comparison between ultrasonography and computed tomography for detecting the pyramidal lobe of the thyroid gland: A prospective multicenter study. *Korean J Radiol* 2015;16:402-9.
- Kim KS, Kim DW, Sung JY. Detection of thyroid pyramidal lobe by ultrasound versus computed tomography: A single-center study. *J Comput Assist Tomogr* 2014;38:464-8.
- Ryu JH, Kim DW, Kang T. Preoperative detection of thyroid pyramidal lobes by ultrasound and computed tomography. *Ultrasound Med Biol* 2014;7:1442-6.
- Wahl R, Müh U, Kallee E. Hyperthyroidism with or without pyramidal lobe Graves' disease or disseminated autonomously functioning thyroid tissue? *Clin Nucl Med* 1997;22:451-8.