

Case Report

Pemphigus Vegetans Presenting as Serpiginous Oral, Esophageal and Genital Mucosal Ulcers Undiagnosed for 3 Years

E Hadlaq, H Al Bagieh, A Qannam, IO Bello

Department of Oral Medicine and Diagnostic Sciences, King Saud University College of Dentistry, Riyadh, Saudi Arabia

ABSTRACT

Pemphigus vegetans (PVeg) is a relatively milder and chronic variant of pemphigus vulgaris. It is very rare, constituting only about 3% of all cases of pemphigus. It is characterized by initial bullae or pustules which may then progress to papillomatous vegetations or plaques. Usually, oral mucosal and cutaneous lesions are seen in the same patient. Very rarely, only mucosal presentation may be seen. In this report, we present a case of a 30-year-old woman with previously undiagnosed multiple, painful, chronic vegetative ulcers with “snail-track”-like appearance present for 3 years. Extensive clinical and laboratory investigations revealed the lesions to be due to PVeg. The patient responded to prednisolone and cyclophosphamide therapy with complete remission after 2 months.

KEYWORDS: *Mucosa, pemphigus vegetans, serpiginous, ulcers, vegetations*

Date of Acceptance:

30-Apr-2018

INTRODUCTION

Persistent mucosal ulcers may be a burden to the patient. To the clinician, the differential diagnosis may range from innocuous or nonspecific ulcers to debilitating conditions like pemphigus. Exhaustive investigations are often required. We present in this report, a case of persistent mucosal ulcers that were undiagnosed for 3 years and required extensive investigations and consultations before being definitively diagnosed as pemphigus vegetans (PVeg).

CASE REPORT

A 30-year-old Saudi woman resented at the Oral Diagnosis Clinic, King Saud University, Riyadh, Saudi Arabia, with a 3-year history of oral soreness and multiple chronic oral ulcers. She reported no initial precipitating event as the lesion started with a hemorrhagic bulla on the soft palate [Figure 1a]. Over time, the lesion slowly progressed to other parts of the oral mucosa as small ulcers with hyperkeratotic plaques [Figure 1b]. Previous use of low potency topical steroids, analgesics, topical anesthetics, mouthwashes, antifungal, antibiotics, and over-the-counter remedies was elicited, accompanied by momentary relief but no regression of lesions.

A review of systems revealed dysphagia, abdominal pain and cramping, and presence of similar lesions in the genital area. Past medical and family histories were of noncontributory nature. Extraoral examination did not reveal any abnormality. Intraorally, multiple painful white-to-yellow pustules with erythematous oral mucosa that seemed to be coalescing in linear “snail-track” configuration were observed. These were covered by friable, vegetating hyperkeratotic plaques in many intraoral sites [Figure 2a-f]. Nikolsky sign was negative.

A diagnostic workup involving mucosal biopsy for morphological assessment of the lesion and immunofluorescence studies, complete full blood count (FBC) and blood chemistry, and antibody (ELISA-based) tests for desmogleins (Dsg 1 and 3) was made. In addition, dermatology, internal medicine (gastroenterologist), and gynecology consultations were included. Histopathology of the oral


Address for correspondence: Dr. E Hadlaq,

Department of Oral Medicine and Diagnostic Sciences, College of Dentistry, King Saud University, P. O. Box 60169, Riyadh 11545, Saudi Arabia.
E-mail: dr.hadlaq@gmail.com

This is an open access journal, and articles are distributed under the terms of the Creative Commons Attribution-NonCommercial-ShareAlike 4.0 License, which allows others to remix, tweak, and build upon the work non-commercially, as long as appropriate credit is given and the new creations are licensed under the identical terms.

For reprints contact: reprints@medknow.com

How to cite this article: Hadlaq E, Al Bagieh H, Qannam A, Bello IO. Pemphigus vegetans presenting as serpiginous oral, esophageal and genital mucosal ulcers undiagnosed for 3 years. *Niger J Clin Pract* 2018;21:1238-41.

Access this article online	
Quick Response Code:	Website: www.njcponline.com
	DOI: 10.4103/njcp.njcp_87_18

mucosa revealed tissue fragments with the epithelium showing acantholytic areas with separation above

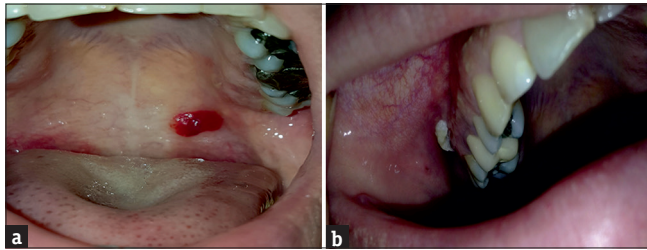


Figure 1: Initial clinical presentation as hemorrhagic bullae in the soft palate (a) and ulcer with hyperkeratotic plaques in buccal vestibule (b) Photos provided courtesy of the patient

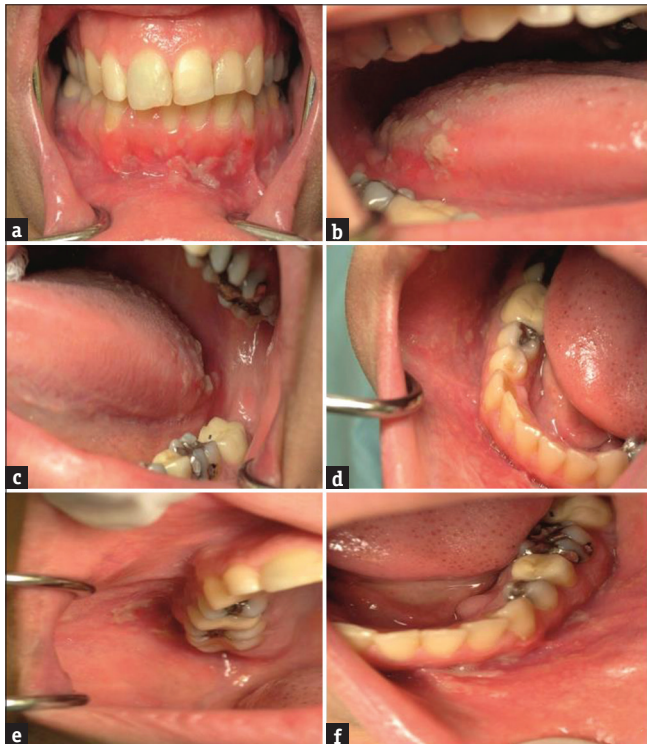


Figure 2: (a) Erosions and coalescent ulcers as lace-like with a purulent surface and the surrounding mucosa is erythematous in the mandibular buccal gingiva and alveolar mucosa, (b and c) multiple coalescent ulcers with vegetations of hyperplastic granulation tissue in lateral surfaces of the tongue, (d and e) ulcers and erosions with friable hyperkeratotic plaques in buccal mucosa, and (f) erosions and ulcers with hyperkeratotic plaques in mandibular buccal vestibule

the basal cells (intraepithelial or suprabasal clefting) with extensive eosinophilia of the adjacent connective tissue [Figure 3a,b]. Focal intraepithelial neutrophilic and eosinophilic abscesses were also observed. An impression of pemphigus-related lesion was made which needed to be correlated with immunofluorescence studies.

Direct immunofluorescence (DIF) showed very strong intercellular deposition of IgG within the epithelium [Figure 3c] but negative for C3 and IgA. All parameters within the FBC were essentially normal except for a high absolute eosinophilic count of $1.58 \times 10^9/L$ (normal $0.05-0.5 \times 10^9/L$). Comprehensive metabolic panel, erythrocyte sedimentation rate, serum folic acid, Vitamin B12, and total serum protein were within normal limits. Circulating antibodies to Dsg 3 but not Dsg 1 were detected using ELISA. Gastroenterologist consultation revealed multiple esophageal ulcers, hyperkeratotic plaques, and vegetations on endoscopy [Figure 4], but all other structures essentially normal. Dermatological consultation did not report any skin lesion. Gynecologic evaluation revealed multiple superficial vulvar and vaginal erosions. On the basis of all these findings, especially the DIF result, a final diagnosis of PVeg was made.

The patient was placed on daily prednisolone 60 mg and cyclophosphamide 100 mg, dexamethasone elixir 0.5 mg/ml, qds and clotrimazole 10 mg troches, tds and reviewed weekly. There was significant resolution of the ulcers after 1 month, although the lower labial vestibular lesions persisted [Figure 5]. Dexamethasone was replaced by topical 0.05% clobetasol propionate cream qds, to be applied to the persistent lesions. After 2 months, the lesions resolved completely without pigmentation or scarring. The systemic steroid was tapered down by 10 mg every 5 days, and the patient was placed on a maintenance therapy of 10 mg prednisolone and 50 mg cyclophosphamide and reviewed monthly for 5 months with no recurrence.

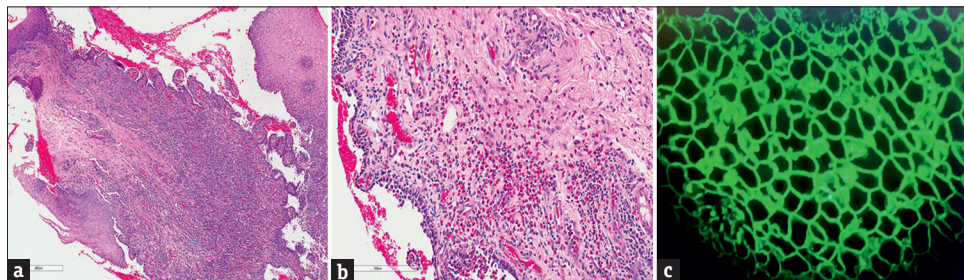


Figure 3: (a and b) Photomicrographs showing intraepithelial clefting alongside extensive eosinophilia of adjacent connective tissue. (c). Direct immunofluorescence showing intercellular deposition of IgG within the epithelium

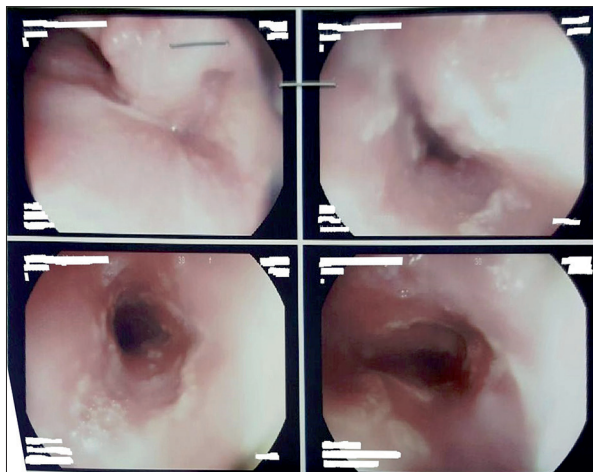


Figure 4: Endoscopic view of multiple discrete superficial ulcers and erosions with hyperkeratotic plaques in esophagus

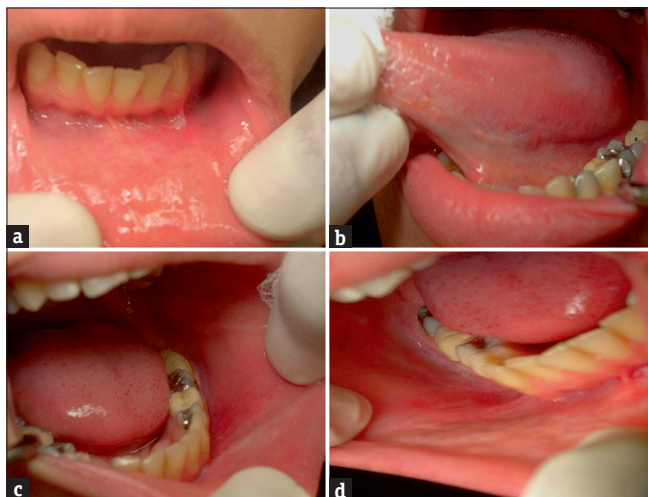


Figure 5: (a) The single ulcer shown here in the lower labial vestibule was the only persistent lesion after 4 weeks with immunosuppressive therapy. (b-d) Resolution of all lesions in the mucosa after 4 weeks with immunosuppressive therapy

DISCUSSION

PVeg is a chronic variant of pemphigus vulgaris characterized by the presence of flaccid blisters which then progresses to papillomatous vegetations. It is generally a rare form of pemphigus vulgaris with several reports confirming that it accounts for <3% of all cases.^[1] The median age of onset is 40–50 years, but PVeg occurs at any age including children.^[2] It has a predilection for flexural areas of the skin, the scalp, and the margins of the mouth. Most cases (>60%) show oral involvement preceding skin involvement, although this can occur in reverse.^[3] The presence of cerebriform or “scrotal” tongue alongside the ulcers and plaques is very useful alongside other manifestations in the diagnosis of PVeg.^[4] Nasal mucosa, larynx, and esophagus may also be involved.^[5,6]

Initially described in two forms: the more severe Neumann type which is basically conventional pemphigus vulgaris that later develop vegetations and the less severe Hallopeau type which begins as pustular eruptions that rapidly develop to verrucous vegetating plaques. The possibility of both variants existing or evolving in the same patient may render this classification to be of minimal clinical use.^[5] This patient presented with mucosal lesions of the mouth and vagina in a serpiginous configuration. There was no cutaneous involvement and common hallmarks of PVeg such as obvious involvement of the vermillion border of lips as well as cerebriform (scrotal) appearance of the tongue were absent. The presence of dysphagia presumably due to lesions in the upper gastrointestinal tract and abdominal discomfort, therefore, needed further investigation. The cause of the abdominal discomfort is not clear as endoscopy revealed no lesions. The gastroenterologist review is warranted as PVeg has been associated with several internal neoplasms including gastric cancer^[7] and colon cancer.^[8] This review did not yield any significant finding.

Among the most common clinical differential diagnosis of PVeg is pyodermitis-pyostomatitis vegetans (PD-PSV). It is almost impossible to rule out the latter clinically and histologically, although a history of inflammatory bowel disease (IBD) is almost invariably associated.^[9] PD-PSV has been suggested as a very good specific marker for IBD, particularly ulcerative colitis.^[10] History and gastroenterologist consultation firmly ruled out the presence of IBD in this patient. Most of the clinical and histological features exhibited in this patient are consistent with PD-PSV. The diagnosis of PVeg was unequivocally supported by the very strong DIF positivity.

The precipitating factors for PVeg are poorly understood. Association with an underlying malignancy has been reported in some patients.^[7,8] PVeg has also been reportedly induced by the use of angiotensin-converting enzyme inhibitors,^[11] prolonged intranasal heroin abuse,^[12] and human immunodeficiency virus infection.^[13] In this patient, no underlying cause could be identified. This case is being presented to reinforce the view that PVeg can be limited to mucosal site with no skin involvement. The patient responded well to treatment within 4 weeks of establishing diagnosis despite the lesions being persistently present for 3 years previously.

Declaration of patient consent

The authors certify that they have obtained all appropriate patient consent forms. In the form the

patient(s) has/have given his/her/their consent for his/her/their images and other clinical information to be reported in the journal. The patients understand that their names and initials will not be published and due efforts will be made to conceal their identity, but anonymity cannot be guaranteed.

Financial support and sponsorship

Nil.

Conflicts of interest

There are no conflicts of interest.

REFERENCES

1. Kanwar AJ, De D. Pemphigus in India. *Indian J Dermatol Venereol Leprol* 2011;77:439-49.
2. Wananukul S, Pongprasit P. Childhood pemphigus. *Int J Dermatol* 1999;38:29-35.
3. Markopoulos AK, Antoniadis DZ, Zaraboukas T. Pemphigus vegetans of the oral cavity. *Int J Dermatol* 2006;45:425-8.
4. Iwata M, Watanabe S, Tamaki K. Pemphigus vegetans presenting as scrotal tongue. *J Dermatol* 1989;16:159-60.
5. Gupta SR, Batra V, Chaudhry Z, Sethi R. An unusual vesiculopustular and vegetative lesion on the lips. *Oral Surg Oral Med Oral Pathol Oral Radiol* 2013;116:666-72.
6. Sigmund GA, Oppenheimer R. Pemphigus vegetans of the nose. *Ear Nose Throat J* 2012;91:E14-5.
7. Koga C, Izu K, Kabashima K, Tokura Y. Pemphigus vegetans associated with gastric cancer. *J Eur Acad Dermatol Venereol* 2007;21:1288-9.
8. Torres T, Ferreira M, Sanches M, Selores M. Pemphigus vegetans in a patient with colonic cancer. *Indian J Dermatol Venereol Leprol* 2009;75:603-5.
9. Mesquita Kde C, Costa IM. Case for diagnosis. *An Bras Dermatol* 2012;87:929-31.
10. Leibovitch I, Ooi C, Huilgol SC, Reid C, James CL, Selva D, *et al.* Pyodermatitis-pyostomatitis vegetans of the eyelids case report and review of the literature. *Ophthalmology* 2005;112:1809-13.
11. Bastiaens MT, Zwan NV, Verschuereen GL, Stoof TJ, Nieboer C. Three cases of pemphigus vegetans: Induction by enalapril – Association with internal malignancy. *Int J Dermatol* 1994;33:168-71.
12. Ngo JT, Trotter MJ, Robertson LH. Pemphigus vegetans associated with intranasal cocaine abuse. *J Cutan Med Surg* 2012;16:344-9.
13. Lateef A, Packles MR, White SM, Don PC, Weinberg JM. Pemphigus vegetans in association with human immunodeficiency virus. *Int J Dermatol* 1999;38:778-81.

