

## Original Article

# Modified Simple Decompression of Ulnar Nerve in the Treatment of Cubital Tunnel Syndrome: Report of a Series of Cases

M Balevi, S Ozturk<sup>1</sup>

Department of Neurosurgery,  
Numune Education and  
Research Hospital, Konya,  
<sup>1</sup>Department of Neurosurgery,  
School of Medicine, Firat  
University, Elazig, Turkey

### ABSTRACT

**Background/Aim:** Ulnar compressive neuropathy is the second most common nerve compression in the upper extremity. Although numerous operative procedures have been defined for the treatment of cubital tunnel syndrome (CuTS), the best operative intervention remains controversial. The aim of this study is to discuss the efficacy of a modified simple decompression (MSD) of the ulnar nerve in the treatment of CuTS. **Materials and Methods:** Each patient was preoperatively examined, and the following data were recorded: initial complaint, duration of symptoms, and presence of Tinel's sign around the elbow, results of provocation by the elbow flexion test, and results of electrodiagnostic studies. Patients' preoperative clinical manifestations were determined based on Dellon's staging system and Bishop scores. Pre- and post-operative motor conduction velocity (MCV) of the ulnar nerve were also recorded. Under the regional anesthesia, 4 cm long curved skin incision, above and below the elbow, was made posterior to the medial epicondyle of the humerus and the ulnar nerve was seen. The nerve was released proximally as it passed through the medial intermuscular septum. The cubital tunnel retinaculum and flexor carpi ulnaris aponeurosis were then cut distally. Only the compressive fascial bands are released. Then, the cubital tunnel reticulum was sutured to subcutaneous tissue loosely to prevent subluxation of the ulnar nerve. **Results:** A total of 15 patients were operated. Postoperative electrophysiological study assessed at 3 months following surgery in 8 patients. In 7 of these patients (86%), the mean value of MCV had improved from  $38.9 \pm 12.0$  m/s to  $48.1 \pm 11.9$  m/s ( $P < 0.05$ ). According to Bishop scoring system, 13 patients (86.7%) were clinically graded as excellent, 1 patient (6.7%) was graded as good, and only 1 patient (6.7%) was graded as fair. **Conclusion:** MSD is a technically simple, safe, and effective method without annoying complications.

**KEYWORDS:** Anterior transposition, cubital tunnel syndrome, simple decompression, ulnar nerve

**Date of Acceptance:**  
31-Jan-2018

## INTRODUCTION

Ulnar compressive neuropathy is the second most common nerve compression in the upper extremity. In contrast to the treatment of carpal tunnel syndrome (CuTS), numerous operative procedures have been defined for the treatment of CuTS. However, the best operative intervention remains controversial.<sup>[1-4]</sup> Many causes include external trauma, pressure, bony impingement, irregularities in muscles, subluxation of

the ulnar nerve over the medial epicondyle, ganglia, and congenital abnormalities such as cubitus valgus.<sup>[5,6]</sup>


The basic surgical concerns are whether the nerve should be transposed or not and if the transposition is performed,

**Address for correspondence:** Prof. S Ozturk,  
Firat Üniversitesi Hastanesi, Beyin Cerrahisi Kliniği,  
23119, Elâzığ, Turkey.  
E-mail: drsaitozturk@yahoo.com

This is an open access journal, and articles are distributed under the terms of the Creative Commons Attribution-NonCommercial-ShareAlike 4.0 License, which allows others to remix, tweak, and build upon the work non-commercially, as long as appropriate credit is given and the new creations are licensed under the identical terms.

**For reprints contact:** reprints@medknow.com

**How to cite this article:** Balevi M, Ozturk S. Modified simple decompression of ulnar nerve in the treatment of cubital tunnel syndrome: Report of a series of cases. Niger J Clin Pract 2018;21:974-8.

Access this article online	
Quick Response Code:	Website: <a href="http://www.njcponline.com">www.njcponline.com</a>
	DOI: 10.4103/njcp.njcp_198_17

which location has better conditions for placing the nerve. Three types of transpositional surgical techniques exist: subcutaneous, submuscular, and intramuscular; each technique has its advantages and disadvantages. Surgical options are categorized into *in situ* (or simple) decompression with or without epicondylectomy<sup>[7-12]</sup> and anterior transposition procedures.<sup>[13-17]</sup>

The classical surgery for simple decompression is performed under general or axillary regional anesthesia. The arm is externally rotated, and the elbow is flexed to 60°–90°. Approximately 6–8 cm long curved skin incision is performed, above and below the elbow, posterior to the medial epicondyle of the humerus. Following the skin incision, overlying subcutaneous tissues are retracted and divided; overlying constricting fascia and the ulnar nerve can be seen. The nerve is released proximally as it passed through the medial intermuscular septum. The cubital tunnel retinaculum and flexor carpi ulnaris aponeurosis are then cut distally, which allowed for simple decompression of the ulnar nerve at the elbow. The wound sutured with usual manners.

The aim of this study is to discuss the efficacy of a modified simple decompression (MSD) of the ulnar nerve in the treatment of CuTS.

## MATERIALS AND METHODS

### Patient selection

After local ethics committee approval, patients who underwent surgery for CuTS were prospectively evaluated for the study. Despite conservative treatment, patients who experienced continuous numbness or tingling in the ring and little fingers, with or without motor deficits, and/or persistent pain along the ulnar border of the hand and forearm, which at times extended to the shoulder, were operated. Each patient was preoperatively examined and the following data were recorded: initial complaint, duration of symptoms, the presence of Tinel's sign around the elbow, results of provocation by the elbow flexion test, and results of electrodiagnostic studies.

Patients' preoperative clinical manifestations were determined based on Dellon's staging system<sup>[18]</sup> [Table 1]. All patients were preoperatively examined based on standard radiographs of the elbow. Accepted indications for anterior transposition included any anatomic lesion that interfered with or impinged the nerve along its native course. Exclusion criteria included deformity or distortion of the cubital tunnel owing to a previous trauma to the elbow and recurrent CuTS after a previous surgery.

Preoperative electromyography of the flexor carpi ulnaris, abductor digiti minimi, and first dorsal interosseous

muscle was performed in all patients. Preoperative motor conduction velocity (MCV) of the ulnar nerve in the axilla above the elbow segment, below the elbow–wrist segment, and below the elbow and above the elbow–wrist segments was also bilaterally evaluated in all patients and compared with that of the nerve in the intact segment (ipsilateral below the elbow–wrist segment). Inching between 4 cm distal and 6 cm proximal to the medial epicondyle was simultaneously performed for all the patients to determine the exact location of the compression site. Postoperative MCV of the ulnar nerve in the affected limb was examined at 1 and 3 months using the same tests. The data were compared with the preoperative results. Both preoperative condition and postoperative clinical outcome were assessed in all patients according to the Bishop scoring system [Table 2].

### Surgical technique

The operative procedure was performed under axillary regional anesthesia using a pneumatic tourniquet. An approximately 4–6 cm long curved skin incision above and below the elbow was made posterior to the medial epicondyle of the humerus. When the overlying subcutaneous tissues were retracted and divided, the overlying constricting fascia and ulnar nerve could be seen. The nerve was released proximally because it passed through the medial intermuscular septum. The cubital tunnel retinaculum and flexor carpi ulnaris aponeurosis were then distally cut for a distance of 3–5 cm, which allowed for simple decompression of the ulnar nerve at the elbow. After the division of the cubital tunnel retinaculum, the nerve was distally isolated using soft loops and immobilized. As accurately as possible, the extrinsic vessels and epineural vascular arborization were preserved to avoid segmental ischemia of the nerve. Circumferential dissection was avoided to prevent the disruption of the surrounding areolar tissue and feeding blood vessels. Only the compressive fascial bands were released without neurolysis to avoid destabilizing the ulnar nerve [Figure 1]. Following release, the elbow was manipulated to check for subluxation, with anterior transposition to be performed if subluxation was noted. The ulnar nerve was identified and freed of the surrounding fibrotic adhesions, ensuring the proximal and distal identification of the nerve in a normal bed. After the ulnar nerve was adequately exposed and freed, the cubital tunnel reticulum, which was sutured to subcutaneous tissue loosely to prevent subluxation of the ulnar nerve, was focused on. Finally, the line of the nerve was checked to ensure that there was no tension or compression because of the sutured cubital tunnel retinaculum [Figure 2]. The superficial tissues were closed in layers, the skin was sutured, and a soft dressing and an elastic bandage were applied.

**Statistical analysis**

To analyze our data, we used STATA version 12 (StataCorp, Texas, USA). *P* < 0.05 was considered statistically significant. To examine differences between groups, we used Chi-square testing for categorical variables and the Student’s *t*-test for continuous variables.

**RESULTS**

Fifteen (9 male, 6 female) patients with a mean age of 43.6 ± 16.5 years (range, 15–72) were operated between the years of 2009–2016. The operation was performed on 6 right and 9 left elbows. None of our patients showed bilateral symptoms. Preoperative chief complaints were paresthesia in 4 patients and paresthesia with weakness in 11. The mean duration of symptoms before surgery was 6.1 (range, 1–24) months. No definite

etiologic factors were observed. None of the elbows showed valgus or varus deformity compared with the opposite elbows. CuTS was observed on the dominant side in 10 patients and nondominant side in 5. Tinel’s sign and the provocation test were positive in all patients. Radiographs of 3 of the 15 elbow joints disclosed mild osteoarthritic changes, but none of these patients experienced any symptoms related to osteoarthritis. According to Dellon’s staging system, 1 of 15 patients was classified as Grade I (mild), 13 were Grade II (moderate), and 1 was Grade III (severe) [Table 1].

Preoperative electrodiagnostic abnormalities were observed in 14 of 15 limbs that underwent MCV examination across the elbow segment of the ulnar nerve. The mean value of MCV within the segment was 38.9 ± 12.0 m/s, which was significantly less than the value of MCV below the elbow–wrist segment of the involved limbs (58.7 ± 6.8 m/s) (*P* < 0.05). The mean value of MCV in the Grade II group according to Dellon’s classification was 40.9 ± 11.5 m/s and that in the Grade III group was 34.3 ± 10.0 m/s (*P* > 0.05). The remaining patient with a normal MCV value showed signs and symptoms consistent with those of the CuTS. Postoperative electrophysiological study was conducted in all patients. In 14 of these patients (93%), the mean value of MCV improved with statistical significance from 38.9 ± 12.0 m/s to 48.1 ± 11.9 m/s (*P* = 0.001) [Table 2]. A patient who had not shown improvement in the postoperative result of MCV had the longest duration of the symptoms before surgery (24 months) among all patients.

In the preoperative period, 13 patients (86.6%) were graded as fair and 2 patients (13.4%) were graded as poor according to the Bishop score system. After an average follow-up of 3.6 ± 6.2 months following surgery, 12 patients (80%) were clinically graded as excellent, 2 patients (13.3%) were graded as good, and only

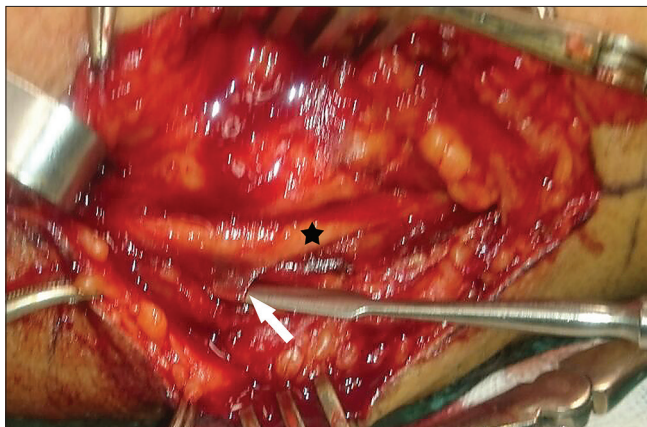**Table 1: Dellon’s classification for cubital tunnel syndrome of the patients preoperatively**

	Mild (I)	Moderate (II)	Severe (III)
Sensory	Intermittent paresthesia	Intermittent paresthesia	Permanent paresthesia
Motor	Subjective weakness	Measurable weakness	Palsy
Number of patients in this study (%)	1 (6.7)	13 (86.6)	1 (6.7)

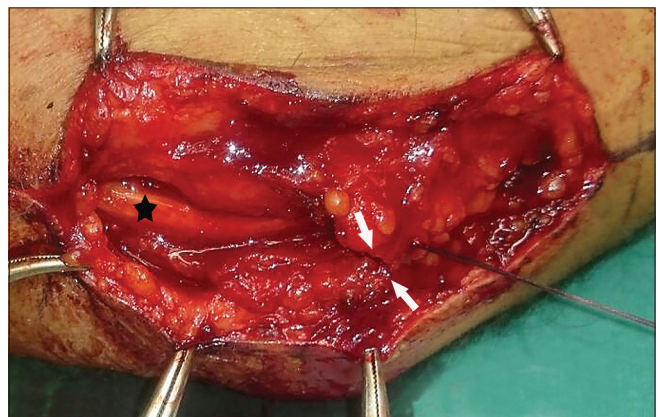
**Table 2: Bishop scale and mean motor conduction velocity results of the patients before and 3 months after surgery**

	Before surgery	After surgery	<i>P</i>
Bishop rate			
Excellent	-	12 patients	
Good	-	2 patients	
Fair	13 patients	1 patients	
Poor	2 patients	-	
Mean MCV (m/s)	38.9±12.0	48.1±11.9	0.001

MCV=Motor conduction velocity



**Figure 1:** Perioperative photograph shows fascial band (arrow) of the ulnar nerve (star) in the cubital tunnel



**Figure 2:** Perioperative photograph shows the ulnar nerve (star) and subcutaneous tissue is sutured to the fascia (arrows)

1 patient (6.4%) was graded as fair in the postoperative period [Table 2]. The patient graded as fair had not shown improvement in the postoperative MCV (with the longest duration of symptoms before surgery [24 months] among all patients). None of the cases were graded as poor. No complications, recurrences, or subluxation of the ulnar nerve were observed.

## DISCUSSION

Controversy exists regarding the best treatment option for CuTS. The literature has not shown any definitely superior procedure for decompression among the surgical modalities, including simple decompression and anterior transposition procedures.<sup>[7,19-24]</sup> However, many authors have reported that simple decompression is the surgical procedure of choice for most CuTS cases.<sup>[11,24,25]</sup> Several comparative studies on simple decompression versus anterior transposition have demonstrated that there are no significant differences between the outcomes of the two procedures.<sup>[20,24,25]</sup> Our opinion, like that of other authors, is that if all surgical techniques yield similar success rates, the selection of a surgical technique should be based on its simplicity.<sup>[7,11,24]</sup>

Medial epicondylectomy has been a successful surgical method to treat CuTS. However, several complications have been reported, including tenderness, postoperative pain, flexor pronator weakness, and valgus instability.<sup>[19,26]</sup> Although medial epicondylectomy has some advantages over anterior transpositions, most neurosurgeons are not familiar with it, and it has drawbacks.

In cases of reoperation for recurrence, persistent symptoms and/or inadequate release were cited as the cause of failure in over 90% of cases.<sup>[1]</sup> Some authors report that the ulnar nerve enters the flexor carpi ulnaris; therefore, the decompression of this area alone yields excellent results with rapid recovery.<sup>[27]</sup> Our observation regarding this comment is that all cases have compression in a bed not only for Osborn's ligament but also for compressive fascial bands of the ulnar nerve.<sup>[28]</sup> For these reasons, all possible compression points of the ulnar nerve at the elbow level should be checked during surgery.

The MSD technique, as we mentioned earlier, has many advantages over anterior transposition techniques. First, MSD is technically simple and does not influence the blood supply of the ulnar nerve.<sup>[19,24]</sup> Second, it is effective because it addresses all foci of the lesions, i.e., the cubital tunnel. Finally, it has a lower rate of postoperative complications and more opportunities for quicker rehabilitation.<sup>[19,24]</sup> MSD, however, is not appropriate in poor beds such as in case of severe cubitus valgus or a subluxing nerve.<sup>[7,28]</sup>

Nerve subluxation is the most common cause of failed cubital tunnel release (CuTR), reported in 2.4%–20% of cases.<sup>[29,30]</sup> To prevent subluxation during an *in situ* release, the ulnar nerve should remain within its epicondylar groove and circumferential dissection should be avoided to prevent the disruption of the surrounding areolar tissue and feeding blood vessels. The compressive fascial bands should be released without neurolysis to avoid destabilizing the ulnar nerve. Following release, the elbow should be manipulated to check for subluxation, and anterior transposition should be performed if subluxation is noted.<sup>[30,31]</sup> We did not observe nerve subluxation in patients who underwent the MSD technique.

Iatrogenic injury to the medial antebrachial cutaneous (MABC) nerve has been reported as the leading cause of pain following CuTR.<sup>[32]</sup> In a study examining intraoperative findings in revision CuTRs, nearly 73 of 100 cases had injury to the MABC nerve.<sup>[33]</sup> Pain in the scar associated with numbness of the posterior and medial elbow region is indicative of neuroma of the MABC nerve. We did not observe injury to the MABC nerve after surgeries. Furthermore, neuropathic symptoms in the distribution of the ulnar nerve occur in up to 30% of patients following CuTR, primarily because of inadequate release and most commonly at the medial intermuscular septum or perineural fibrosis.<sup>[18]</sup> Pain radiating from the elbow scar to the small and ring fingers with numbness suggests recurrent compression, whereas patients who have persistent symptoms owing to inadequate release do not experience symptom resolution.<sup>[32]</sup> In contrast, patients who may have recurrent symptoms owing to perineural fibrosis may initially experience symptom resolution, with symptom reappearance over time.<sup>[27]</sup> We did not observe neuropathic symptoms secondary to perineural fibrosis.

In recent years, endoscopic nerve decompression is increasingly gaining popularity because of the short incision, lower risk of nerve damage, reduced manipulation of the nerve, and possible faster recovery.<sup>[34]</sup> However, no clearly superior procedure has been demonstrated for decompression at the elbow.

In this clinical study, we discussed the reason underlying the simple decompression of ulnar nerve, and it was concluded that minimal elevation of the nerve is an alternative to transposition procedures in most patients with CuTS. In addition, we reported both preoperative clinical findings and surgical results in patients treated with an MSD technique. MSD is a technically simple, safe, and effective method without annoying complications. Its application seems appropriate, regardless of symptom severity, in patients who remain unresponsive to conservative care.

## Financial support and sponsorship

Nil.

## Conflicts of interest

There are no conflicts of interest.

## REFERENCES

- Goldfarb CA, Sutter MM, Martens EJ, Manske PR. Incidence of re-operation and subjective outcome following *in situ* decompression of the ulnar nerve at the cubital tunnel. *J Hand Surg Eur Vol* 2009;34:379-83.
- Yoshida A, Okutsu I, Hamanaka I. Endoscopic anatomical nerve observation and minimally invasive management of cubital tunnel syndrome. *J Hand Surg Eur Vol* 2009;34:115-20.
- Foran I, Vaz K, Sikora-Klak J, Ward SR, Hentzen ER, Shah SB, *et al.* Regional ulnar nerve strain following decompression and anterior subcutaneous transposition in patients with cubital tunnel syndrome. *J Hand Surg Am* 2016;41:e343-50.
- Glowacki KA, Weiss AP. Anterior intramuscular transposition of the ulnar nerve for cubital tunnel syndrome. *J Shoulder Elbow Surg* 1997;6:89-96.
- Gabel GT, Amadio PC. Reoperation for failed decompression of the ulnar nerve in the region of the elbow. *J Bone Joint Surg Am* 1990;72:213-9.
- Robertson C, Saratsiotis J. A review of compressive ulnar neuropathy at the elbow. *J Manipulative Physiol Ther* 2005;28:345.
- Heithoff SJ. Cubital tunnel syndrome does not require transposition of the ulnar nerve. *J Hand Surg Am* 1999;24:898-905.
- Hoffmann R, Siemionow M. The endoscopic management of cubital tunnel syndrome. *J Hand Surg Br* 2006;31:23-9.
- Kim JG, Lee KY, Yoo YR, Kim KN, Chung HY. Medial epicondylectomy for tardy ulnar palsy. *J Korean Neurosurg Soc* 1974;3:101-3.
- Nathan PA, Istvan JA, Meadows KD. Intermediate and long-term outcomes following simple decompression of the ulnar nerve at the elbow. *Chir Main* 2005;24:29-34.
- Nathan PA, Keniston RC, Meadows KD. Outcome study of ulnar nerve compression at the elbow treated with simple decompression and an early programme of physical therapy. *J Hand Surg Br* 1995;20:628-37.
- Taniguchi Y, Takami M, Takami T, Yoshida M. Simple decompression with small skin incision for cubital tunnel syndrome. *J Hand Surg Br* 2002;27:559-62.
- Eliaspour D, Sedighpour L, Hedayati-Moghaddam MR, Rayegani SM, Bahrami MH, Roghani RS, *et al.* The pattern of muscle involvement in ulnar neuropathy at the elbow. *Neurol India* 2012;60:36-9.
- Gervasio O, Gambardella G. Anterior submuscular transposition of the ulnar nerve in severe cubital tunnel syndrome. Personal experience. *J Neurosurg Sci* 2004;48:113-6.
- Kim DH, Han K, Tiel RL, Murovic JA, Kline DG. Surgical outcomes of 654 ulnar nerve lesions. *J Neurosurg* 2003;98:993-1004.
- Lascar T, Laulan J. Cubital tunnel syndrome: A retrospective review of 53 anterior subcutaneous transpositions. *J Hand Surg Br* 2000;25:453-6.
- Mowlavi A, Andrews K, Lille S, Verhulst S, Zook EG, Milner S, *et al.* The management of cubital tunnel syndrome: A meta-analysis of clinical studies. *Plast Reconstr Surg* 2000;106:327-34.
- Dellon AL. Review of treatment results for ulnar nerve entrapment at the elbow. *J Hand Surg Am* 1989;14:688-700.
- Bednar MS, Blair SJ, Light TR. Complications of the treatment of cubital tunnel syndrome. *Hand Clin* 1994;10:83-92.
- Chan RC, Paine KW, Varughese G. Ulnar neuropathy at the elbow: Comparison of simple decompression and anterior transposition. *Neurosurgery* 1980;7:545-50.
- Fernandez E, Pallini R, Lauretti L, Scogna A, La Marca F. Neurosurgery of the peripheral nervous system: Cubital tunnel syndrome. *Surg Neurol* 1998;50:83-5.
- Filippi R, Farag S, Reisch R, Grunert P, Böcher-Schwarz H. Cubital tunnel syndrome. Treatment by decompression without transposition of ulnar nerve. *Minim Invasive Neurosurg* 2002;45:164-8.
- Kleinman WB, Bishop AT. Anterior intramuscular transposition of the ulnar nerve. *J Hand Surg Am* 1989;14:972-9.
- Nabhan A, Ahlhelm F, Kelm J, Reith W, Schwerdtfeger K, Steudel WI, *et al.* Simple decompression or subcutaneous anterior transposition of the ulnar nerve for cubital tunnel syndrome. *J Hand Surg Br* 2005;30:521-4.
- Davies MA, Vonau M, Blum PW, Kwok BC, Matheson JM, Stening WA, *et al.* Results of ulnar neuropathy at the elbow treated by decompression or anterior transposition. *Aust N Z J Surg* 1991;61:929-34.
- Muermans S, De Smet L. Partial medial epicondylectomy for cubital tunnel syndrome: Outcome and complications. *J Shoulder Elbow Surg* 2002;11:248-52.
- Gellman H, Champion DS. Modified *in situ* decompression of the ulnar nerve at the elbow. *Hand Clin* 1996;12:405-10.
- Santosa KB, Chung KC, Waljee JF. Complications of compressive neuropathy: Prevention and management strategies. *Hand Clin* 2015;31:139-49.
- Bartels RH, Menovsky T, Van Overbeeke JJ, Verhagen WI. Surgical management of ulnar nerve compression at the elbow: An analysis of the literature. *J Neurosurg* 1998;89:722-7.
- Nellans K, Tang P. Evaluation and treatment of failed ulnar nerve release at the elbow. *Orthop Clin North Am* 2012;43:487-94.
- Palmer BA, Hughes TB. Cubital tunnel syndrome. *J Hand Surg Am* 2010;35:153-63.
- Dellon AL, MacKinnon SE. Injury to the medial antebrachial cutaneous nerve during cubital tunnel surgery. *J Hand Surg Br* 1985;10:33-6.
- Mackinnon SE, Novak CB. Operative findings in reoperation of patients with cubital tunnel syndrome. *Hand (N Y)* 2007;2:137-43.
- Smeraglia F, Del Buono A, Maffulli N. Endoscopic cubital tunnel release: A systematic review. *Br Med Bull* 2015;116:155-63.