

## Case Report

# Total Maxillectomy with Prosthetic Reconstruction Technique

Y Hayran, N Akbulut<sup>1</sup>

Departments of Prosthodontics and <sup>1</sup>Oral and Maxillofacial Surgery, Faculty of Dentistry, Gaziosmanpasa University, Tokat, Turkey

### ABSTRACT

The prosthetic treatment of patients with total maxillectomies is an enormous reconstruction challenge because of insufficient support and retention from the residual tissues. It is not possible to place the bulb in the presence of unfavorable undercuts throughout the nasal cavity floor and borders. The purpose of this article was to describe a prosthetic reconstruction technique which accomplishes optimum sealing, retention, stabilization, and easy placement of an open-hollow acrylic resin obturator using a spring with a resilient liner for a patient who underwent a total maxillectomy. The springs were placed in the resilient liner to facilitate the placement of the obturator prosthesis because of unfavorable undercuts. It was possible to fit the prosthesis in two stages by means of springs. The objective of this technique is to improve the patient's psychological, functional, and social well-being by producing a stable, retentive, leakproof, comfortable, easy-fitting prosthesis. This technique is appropriate for patients who have undergone total maxillectomies when implant placement is not possible.

**KEYWORDS:** *Dental obturators, maxillectomy reconstruction, maxillofacial prosthesis, open-hollow acrylic resin obturator, total maxillectomy*

**Date of Acceptance:**  
10-Jan-2018

## INTRODUCTION

The most frequent type of treatment for patients diagnosed with a malignant neoplasia of the oral cavity is surgical resection of the tumor.<sup>[1]</sup> The absence of the hard and soft palates makes it difficult to maintain essential functions such as swallowing, chewing, and speaking. Surgical intervention or prosthetic treatments are used to overcome these problems. Often, a successful surgical reconstruction is very difficult when the area of the defect is large, and a prosthetic rehabilitation is inevitable under these circumstances.<sup>[1]</sup> Prosthodontic rehabilitation following a maxillectomy commonly involves the fabrication of an obturator prosthesis. Fabricating a maxillofacial prosthesis in a total maxillectomy patient is a challenging prosthetic reconstruction. The remaining tissues are insufficient for prosthetic retention. The bulb is the most important maxillary obturator prosthesis component used to achieve these goals and also separates the oronasal region.<sup>[2]</sup> The preferred material for bulb construction is polymethylmethacrylate (PMMA).<sup>[1,3]</sup> The hardness and inflexibility of PMMA obturator bulbs, however, creates

continuing local irritation and pain. The management of patients having undesirable undercuts along the defect floor and walls is a significant challenge in the placement of the obturator bulbs into the defect areas. In this case, a new fabrication and retention method for obtaining a stable, retentive, comfortable, easy-fitting hollow acrylic resin obturator prosthesis using a resilient liner and springs was introduced. The springs were placed in the resilient liner to facilitate the placement of the obturator prosthesis because of unfavorable undercuts. It was possible to fit the prosthesis in two stages by means of springs.

## CASE REPORT

This report presents a 78-year-old male patient who had prosthetic treatment after undergoing a total maxillectomy. The patient's main discomforts were inadequate speech, chewing, and swallowing, as well

**Address for correspondence:** Dr. Y Hayran, Department of Prosthodontics, Faculty of Dentistry, Gaziosmanpasa, University, Tokat, Turkey. E-mail: [yeliz\\_hayran@yahoo.com](mailto:yeliz_hayran@yahoo.com)

### Access this article online

#### Quick Response Code:



**Website:** [www.njcponline.com](http://www.njcponline.com)

**DOI:** 10.4103/njcp.njcp\_294\_17

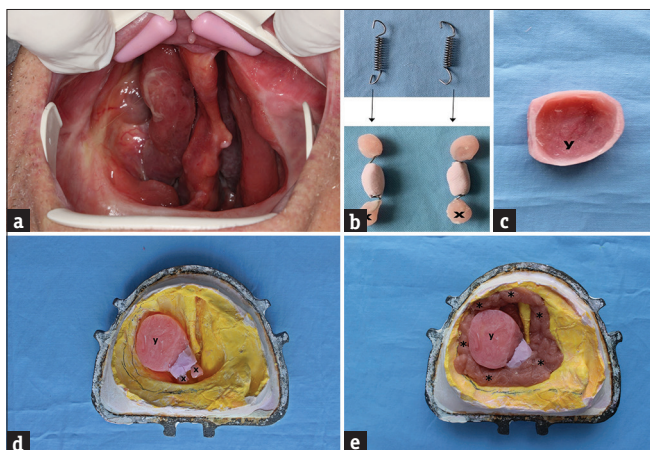
This is an open access journal, and articles are distributed under the terms of the Creative Commons Attribution-NonCommercial-ShareAlike 4.0 License, which allows others to remix, tweak, and build upon the work non-commercially, as long as appropriate credit is given and the new creations are licensed under the identical terms.

**For reprints contact:** [reprints@medknow.com](mailto:reprints@medknow.com)

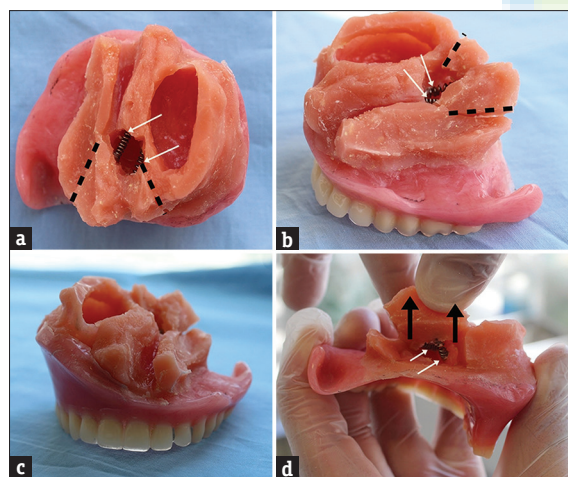
**How to cite this article:** Hayran Y, Akbulut N. Total maxillectomy with prosthetic reconstruction technique. *Niger J Clin Pract* 2018;21:939-41.

as the seepage of nasal secretions into the oral cavity following a major resection of the maxilla because of squamous cell carcinoma. The patient had a bilateral total maxillectomy; only a section of the left maxillary tuberosity was kept [Figure 1a]. Since the remaining tissues cannot provide adequate retention and support, obturator prosthesis with zygomatic implant support

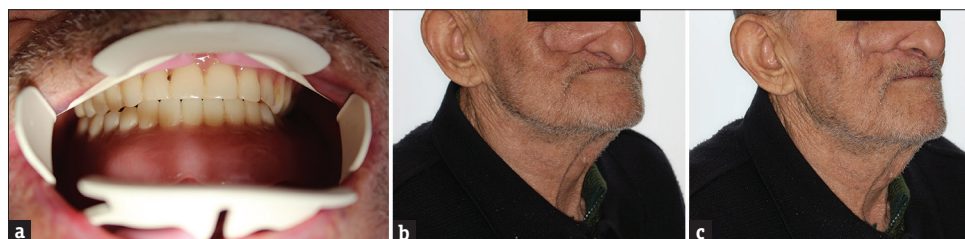which could increase the stability of obturator prosthesis was planned. However, bone deficiency in zygomatic area prevented implant placement. Therefore, an open-hollow acrylic resin obturator with a modification was fabricated. A preliminary impression of the resected maxilla was made with irreversible hydrocolloid impression material (Alginate, Cavex, the Netherlands), and a custom impression tray forming the preliminary cast was fabricated. A final impression using irreversible hydrocolloid impression material (Alginate, Cavex, the Netherlands) was made, after which a master cast was produced using dental stone type IV gypsum product (Denston, Ata Plaster, Turkey). The extension of surgical border was marked on the cast, and a record base with wax occlusion rim was fabricated to determine the facial support, tooth position, vertical dimension, and occlusal registration. Subsequently, artificial teeth were arranged, and wax trial dentures were inserted into the mouth. Vertical dimension, occlusion, esthetics, and function were checked. The wax obturator denture was invested in a flask and the wax was eliminated. A self-cured acrylic resin was used (Panacryl, Arma Dental, Turkey) to fabricate the bulb [Figure 1c] and cured in a pressure pot (Polyclav; Dentaurum, Germany). Two pieces of spring-style wire (round, stainless steel orthodontic wire in 0.5 mm diameter) were curved. The tips of the wires were bent and wrapped with self-cured acrylic resin. Then, the distances between the springs were widened and springs were fixed to the bulb. The springs were surrounded with a combination of light and heavy body C-silicone (Zhermack, Zetaplus, Italy) impression material to prevent the incursion of acrylic resin and soft relining material [Figure 1b and d]. The bulb with the spring wires was placed in the seepage of the nasal secretion area [Figure 1d]. The soft relining dough (Molloplast-B, Detax GmbH, Germany) was adapted to the remainder of the defect area and around the bulb [Figure 1e]. The heat-cured acrylic resin (Meliodent, Heraeus Kulzer, NY, USA) was placed on the flask to cover the entire palate up to the buccal and labial vestibules. The flask was closed, and the denture was cured according to the manufacturer's instructions. After the polymerization, the prosthesis was finished and polished. The impression material around



**Figure 1:** (a) Intraoral view of the defect area, (b) prepared springs, (c) prepared bulb, (d) placement of the bulb with springs, (e) placement of resilient liner dough in the defect area. x = ends of the springs; y = bulb; \* = soft relining material



**Figure 2:** (a) View of the intaglio surface with the exposed springs, (b) view of the left side of the obturator, (c) frontal view of the obturator, (d) cutting of resilient liner material. When the cut part of the prosthesis is lifted up, springs can be seen. Dotted lines indicate the cutting areas, black arrows indicate the movement direction, and white arrows indicate the springs



**Figure 3:** (a) Obturator in function, (b) extraoral view without the dentures, (c) extraoral view with the dentures

the springs was removed [Figure 2a-d], and the soft relining material was cut as shown in Figure 2 so that the trimmed part can allow the prosthesis to fit easily. The dentures were inserted into the mouth and were checked for settling, vertical dimension, occlusion, esthetics, and function [Figure 3a-c].

## DISCUSSION

The surgical removal of the hard and soft palates results in a hypernasal voice, nasal discharge into the mouth, liquid seepage into the nasal cavity, and reduced effectiveness of the chewing system. Obturator prostheses are used to replace defective hard palate, soft palate, and adjacent alveolar tissues to overcome these problems. Implant-supported obturator prostheses are useful if the retention features are inadequate in edentulous maxillary defect patients. The prostheses retention, support, and stabilization become challenging when implant placement is contraindicated for edentulous maxillary defect patients. A conventional maxillofacial obturator prosthesis with a bulb is inevitable in this type of case. The relief of tissue-damaging sites of the bulb in the undercut spaces restricts the support for a prosthesis. However, the existing undercut sites are an advantage in maintaining the retention, support, and stabilization of an obturator. In the present case, the resilient liner was applied to the bulb and the surface of the obturator that contacted the defect area to overcome this problem. It is possible to fit the prosthesis in two stages by means of springs. In this way, a large amount of contact with the defect area of the resilient intaglio surface occurred without causing mechanical irritation in the tissue, and the obturator ensured superior impermeability and retention by allowing engagement of the undercuts within the defect. The liner will buffer the mastication forces during chewing, reducing the transmission of forces to the sensitive tissue.<sup>[4]</sup> It will also help in effective chewing function. The resilience of this prosthesis is also likely to make it more comfortable in retention, stabilization, and ease of prosthetic positioning at the same time. The weight of the obturator used in complete denture patients is important in terms of stabilization and retention.<sup>[3]</sup> The use of a resilient liner and hollow bulb contributes to stabilization, retention, and comfort by reducing the weight of the obturator. The

production stage of the obturator does not require any special ability. It was determined that the prosthesis was unspoiled and functional during the control appointment almost 2 years later. Although the patient is satisfied with the functionality of the prosthesis, the resilient liner material should be replaced after 3–5 years.<sup>[5]</sup>

The obturator applied in the study improved the patient's psychological, functional, and social well-being. This method of fabrication is appropriate for patients who have undergone total maxillectomies when implant placement is not possible.

## Declaration of patient consent

The authors certify that they have obtained all appropriate patient consent forms. In the form the patient(s) has/have given his/her/their consent for his/her/their images and other clinical information to be reported in the journal. The patients understand that their names and initials will not be published and due efforts will be made to conceal their identity, but anonymity cannot be guaranteed.

## Acknowledgment

The authors are thankful to Mehmet Yılmaz, a dental technologist, for helping in the prosthesis fabricating process.

## Financial support and sponsorship

Nil.

## Conflicts of interest

There are no conflicts of interest.

## REFERENCES

1. Seong DJ, Hong SJ, Ha SR, Hong YG, Kim HW. Prosthetic reconstruction with an obturator using swing-lock attachment for a patient underwent maxillectomy: A clinical report. *J Adv Prosthodont* 2016;8:411-6.
2. Aramany MA, Drane JB. Effect of nasal extension sections on the voice quality of acquired cleft palate patients. *J Prosthet Dent* 1972;27:194-202.
3. Kwon HB, Chang SW, Lee SH. The effect of obturator bulb height on speech in maxillectomy patients. *J Oral Rehabil* 2011;38:185-95.
4. Ikusika OF, Dosumu OO, Ajayi DM, Ogunrinde TJ. Effect of resilient lining of obturator bulbs on patients with maxillectomies. *J Prosthet Dent* 2016;116:932-6.e1.
5. Duncan JD, Clark LL. The use of a soft denture liner for chronic residual ridge soreness. *J Am Dent Assoc* 1985;111:64-5.