

## Original Article

# Outcome of Management of Elevated Skull Fractures in Enugu, South-East Nigeria

EE Onyia, MC Chikani, WC Mezue, EO Uche, I Iloabachie, E Okorie, G Dung<sup>1</sup>

Department of Surgery,  
Neurosurgery Unit,  
University of Nigeria  
Teaching Hospital, Enugu,  
<sup>1</sup>Department of Surgery,  
Ahmadu Bello University  
Teaching Hospital, Zaria,  
Nigeria

### ABSTRACT

**Introduction:** Elevated skull fractures, previously thought of as a very rare variety of fractures, are no longer very uncommon. They are expectedly gradually finding a slowly growing list of references in neurosurgical literature. They are mostly posttraumatic compound fractures due to the mechanism of injury. Outcome of operative neurosurgical care is generally rewarding. **Materials and Methods:** A 4-year retrospective study of case notes, operation registers, and radiology records of patients diagnosed with elevated skull fractures who had neurosurgical care at the University of Nigeria Teaching Hospital, Enugu, Nigeria, between 2012 and 2015, was done. Only patients with evidence of elevated skull fracture on head computed tomography scan were included. The presenting Glasgow Coma Score and Extended Glasgow Outcome Score (GOSE) at the time of discharge from the hospital and 6 months thereafter were analyzed. **Results:** Out of 209 patients managed with skull fractures over the study period, eight met the inclusion criteria. Seven (87.5%) were males. The latency to presentation was 6 h in one case and >8 h in the other cases. All the patients had operative care involving debridement, duroplasty, and bone-fragment realignment (cranioplasty) either primarily or on an interval basis. The GOSE at 6 months was at least 7 in 87.5% of the patients. **Conclusions:** Despite the grotesque appearance at presentation, outcome of properly managed elevated skull fractures is good.

**KEYWORDS:** Cranioplasty, duroplasty, elevated skull fracture, extended Glasgow Outcome Score

**Date of Acceptance:**  
02-May-2018

## INTRODUCTION

Skull fractures are classified on the basis of pattern, anatomic location, and integrity of the overlying skin. Traditionally recognized patterns include linear, comminuted, and depressed skull fractures.<sup>[1-5]</sup> Elevated skull fracture has also been described, but is infrequently mentioned in literature. In the last decade, an increasing number of reports have emerged on this rare pattern of skull fracture, most of which are compound. We present eight cases of elevated skull fractures seen in a child and seven adults, from different modes of injury. This study was carried out with the objective of examining the patient profile, injury patterns, as well as outcomes of elevated skull fractures that were managed at the University of Nigeria Teaching Hospital, Enugu, within the period under review and by doing so contributing to

the growing wealth of knowledge of this unique pattern of skull fractures.

## MATERIALS AND METHODS

This was a retrospective study of patients who presented to the University of Nigeria Teaching Hospital, Enugu, between January 2012 and December 2015, and were managed for elevated skull fractures. Patients' case notes, operation notes, and radiology records were retrieved and relevant clinical and radiological data were extracted. Only patients who had clinical

**Address for correspondence:** Dr. EE Onyia,

Department of Surgery, Neurosurgery Unit, University of Nigeria  
Teaching Hospital, Ituku/Ozalla, Enugu, Nigeria.  
E-mail: ephraim.onyia@unn.edu.ng

This is an open access journal, and articles are distributed under the terms of the Creative Commons Attribution-NonCommercial-ShareAlike 4.0 License, which allows others to remix, tweak, and build upon the work non-commercially, as long as appropriate credit is given and the new creations are licensed under the identical terms.

**For reprints contact:** reprints@medknow.com

**How to cite this article:** Onyia EE, Chikani MC, Mezue WC, Uche EO, Iloabachie I, Okorie E, et al. Outcome of management of elevated skull fractures in Enugu, South-East Nigeria. *Niger J Clin Pract* 2018;21:859-64.

Access this article online	
Quick Response Code: 	Website: <a href="http://www.njcponline.com">www.njcponline.com</a>
	DOI: 10.4103/njcp.njcp_347_17

and computed tomography (CT) scan evidence of elevated skull fractures were included in the study. Their demographic, clinical, and radiologic data were analyzed. The management of the patients involved the perioperative administration of broad-spectrum antibiotics – intravenous ceftriaxone and metronidazole; wound debridement; removal of loose bone fragments; dural repair (duroplasty); and bone fragment realignment. Dural repair was achieved by simple closure, use of autogenous temporalis fascia, or pericranial graft. Bone fragment realignment (autogenous cranioplasty) was done either primarily or in a delayed fashion. The trauma-presentation and trauma-surgery intervals were estimated. The presenting Glasgow Coma Scale Score was noted.

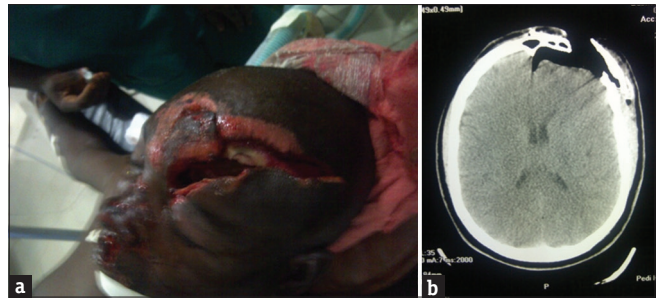
The outcome measures were extended Glasgow Outcome Score (GOSE) at the time of discharge from the hospital and 6 months thereafter. The available literature on elevated skull fractures was reviewed from a search of PubMed and African Index Medicus and compared with data from these patients.

## RESULTS

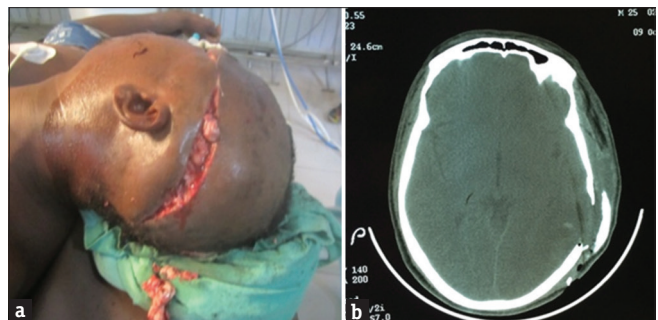
Out of 209 patients managed with skull fractures over the study period, 8 had elevated skull fractures. Seven of them (87.5%) were male and one (12.5%) was female. Only one of the patients was within the pediatric age group – a 13-year-old boy. The other 7 were all adults, with ages ranging from 18 to 47 years.

Various modes of injury were implicated in the etiology of the fractures [Table 1], the most common of which was assault to the head with a machete (three cases). All the eight patients suffered compound elevated fractures with mild or moderate head injuries (presenting Glasgow Coma Scale [GCS]: 9–15).

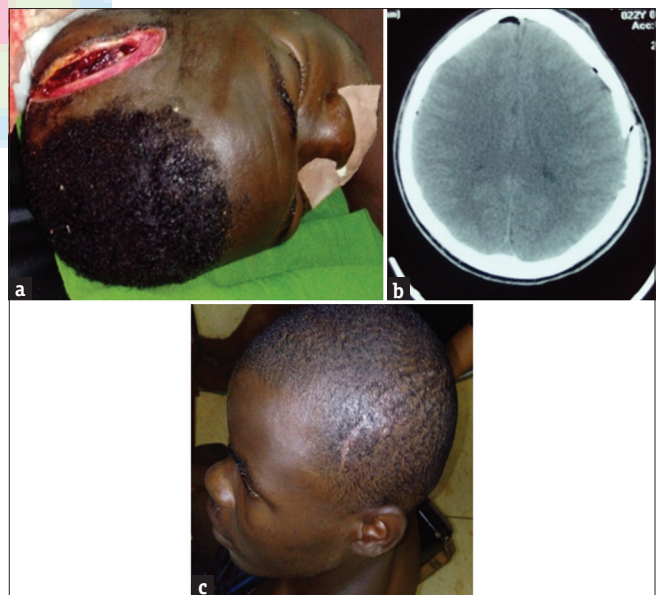
The management of the patients involved the perioperative administration of broad-spectrum antibiotics – intravenous ceftriaxone and metronidazole; wound debridement; removal of loose bone fragments; dural repair; and bone fragment realignment.<sup>[1,5-13]</sup> Dural repair was achieved by simple closure in two cases, autogenous temporalis fascia graft in one and autogenous pericranial graft in the other five. Bone fragment realignment was done primarily in four of the eight patients. However, due to extensive wound contamination and delayed presentation in the other four patients, the elevated bone fragment was thoroughly saline-washed and placed in a subcutaneous abdominal pouch for interval autogenous cranioplasty. The trauma-surgery interval in this series ranged from 19 h to 9 days, largely due to delayed presentation.



**Figure 1:** (a) Motorcycle accident showing extensive soft-tissue injury and an “open door” type injury. A crash helmet may have reduced the extent of the injury, (b) Head computed tomography scan depicting elevated fracture (open door type) with pneumocephalus



**Figure 2:** (a) Machete cut. Note brain tissue presenting from the linear cut, (b) Axial head computed tomography scan showing an elevated floating fragment



**Figure 3:** (a) Clean machete cut. Note elevated bone fragment and dural laceration, (b) postoperative axial computed tomography scan image. Note preserved brain parenchyma and satisfactory re-alignment of previously elevated bone fragment, (c) image 4 weeks postoperatively – note scar

We had very good outcome in seven patients [GOSEs in Table 1]. The only mortality was from the patient with gunshot head injury and this occurred following an intracranial suppurative process.

**Table 1: Summary of eight cases of elevated skull fracture**

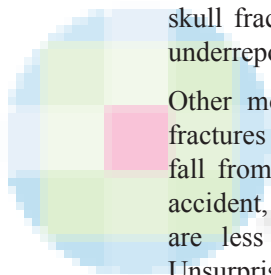
Case	Age (years)	Sex	TPI	TSI	Mode of injury	GCS	Presenting condition	Associated condition	CT findings	Treatment	Complications	GOSE at discharge	GOSE at 6 months
1	13	Male	20 h	48 h	Fell from a tree after being hit in the head by a branch he was cutting down	11 (E4M5V2)	Early posttraumatic seizure, right open femoral fracture	None	Left temporal skull elevated fracture, left temporal lobe contusion	Exploration, debridement, duroplasty, antibiotics, interval autogenous cranioplasty	None	6	7
2	38	Male	8 h	19 h	Rider motorcycle accident [Figure 1a]	15	None	None	[Figure 1b] Elevated frontal bone fracture, pneumocephalus	Exploration, debridement, duroplasty, antibiotics, interval autogenous cranioplasty	Surgical site sepsis	8	8
3	25	Male	15 h	22 h	Machete injury to the head from assault [Figure 2a]	14 (E4M6V4)	None	None	[Figure 2b] Left temporo-parieto-occipital elevated skull fracture, parenchymal contusion, pneumocephalus	Exploration, debridement, duroplasty, antibiotics, interval autogenous cranioplasty	None	8	8
4	47	Female	32 h	50 h	Gunshot injury to the head	10 (E2M5V3)	Right ocular injury	None	Fronto-orbital comminuted mixed elevated-depressed fracture	Exploration, debridement, duroplasty, antibiotics, interval autogenous cranioplasty	Intracranial suppurative process	5	1
5	38	Male	30 h	2 days	Machete injury to the head from assault	15	None	None	Right parietal elevated skull fracture	Debridement, duroplasty and realignment of bone fragment, antibiotics	None	8	8
6	38	Male	8 days	9 days	Driver MVA	9 (E1M6V2)	Left ocular injury	None	Left compound fronto-temporo-parietal mixed elevated-depressed fracture, pan orbital wall fracture, left frontal contusion	Wound, exploration and debridement, duroplasty and realignment of bone fragment, antibiotics	Intracranial suppurative process	6	7
7	18	Male	3 days	4 days	Physical assault	9 (E2V2M5)	Blunt abdominal injury	None	Multiple fractures: Elevated left fronto-temporo-orbital, right temporal linear, bilateral ethmoidal, right temporo-parietal epidural hematoma	Right fronto-parieto-temporal craniotomy + epidural hematoma evacuation, realignment of elevated bone fragment	None	7	8

Contd...

Table 1: Contd...

Case	Age (years)	Sex	TPI	TSI	Mode of injury	Presenting GCS	Associated condition	CT findings	Treatment	Complications	GOSE at discharge	GOSE at 6 months
8	22	Male	6 h	19 h	Machete injury to the head from assault [Figure 3a]	15	Multiple trunk and limb lacerations	Left parietal elevated skull fracture [Figure 3b]; Satisfactory realignment (postoperative), residual aeroceles	Wound debridement and realignment of bone fragment	None	8	8

TPI=Trauma-presentation interval; TSI=Trauma-surgery interval; E=Best eye opening; M=Best motor response; V=Best verbal response; MVA=Motor vehicular accident; GOSE=Extended Glasgow Outcome Score; GCS=Glasgow Coma Score; CT=Computed tomography



Other clinical and radiological details are as outlined in Table 1.

## DISCUSSION

An elevated skull fracture is one in which the fractured bone fragment is lifted above the level of the surrounding intact skull.<sup>[1,6,8,13]</sup> Though recognized as early as in the historical surgical manuscript, the Edwin Smith Papyrus, it is a rarely reported pattern of skull fracture.<sup>[8]</sup>

Its mechanism of occurrence is the tangential application of force to the scalp, skull, brain, and its meninges.<sup>[1]</sup> This commonly results from assault with sharp-edged weapons such as machetes, as was suffered by three of the patients in this study.<sup>[8]</sup> Factors that may contribute to elevation of the fractured bone fragment by this mechanism include lateral pull of the weapon of injury during retrieval and rotation of the head during impact.<sup>[11,14]</sup> An interesting observation here was that the resulting elevated bone fragments were floating, with minimal underlying brain injury. With the recent upsurge of attacks by community invaders in the south-east and other regions of Nigeria, the incidence of elevated skull fractures may actually be on the rise and may be underreported.

Other modes of injury associated with elevated skull fractures include domestic violence, road accidents, fall from height, animal attack, crane accident, railway accident, gunshot, and blast injury.<sup>[8,11,15-18]</sup> They are less common causes of elevated skull fracture. Unsurprisingly, therefore, motorcycle and motor vehicular accidents, though common modes of head injury in this environment, were responsible for only one casepiece, in this series. Elevated skull fracture from gunshot as in case 4 has also been reported in literature.<sup>[15]</sup> The mode of injury noted in case 1 (a falling tree branch striking the head, leading to a fall from a 6-m height) is, however, not previously reported in the etiology of elevated skull fracture, to the best of our knowledge.

Majority of published cases of elevated skull fractures were in adults. They are rarely reported in children.<sup>[11]</sup> The finding of only one pediatric patient in this series therefore comes as no surprise.

In this study, all the eight patients suffered compound elevated fractures, consistent with findings in most reports that elevated skull fractures are also compound and may occasionally simulate a formal craniotomy.<sup>[10,11,19]</sup> They may occur either in isolation as in six of the cases, or in combination with a depressed fracture – “mixed elevated-depressed,” as in cases 4 and 6.<sup>[10,11,19]</sup> It is worthy of note, however,

that “simple” elevated skull fracture may rarely occur, as reported by Chhiber *et al.* and Kumar *et al.* in their separate reports.<sup>[11,14]</sup> We did not encounter such case in this study.

Clinical features of elevated skull fractures depend on the site and extent and severity of associated brain injury.<sup>[1,10,11,13]</sup> The variation in GCS scores found in the patients in this study is a reflection of various degrees of associated brain trauma – in keeping with the variations in presenting GCS seen in literature. In Bokar’s series of three patients, one had a GCS of 15 on presentation, while another was brought in dead.<sup>[10]</sup> In Kumar’s series of five patients, three had severe head injury, while the remaining two had moderate and mild injuries, respectively. The severity of injury and the resultant neurological manifestations in elevated skull fracture vary. They depend on the degree of injury to the underlying brain parenchyma and may range from minor ones to fatal ones.<sup>[8,10,13]</sup> In general, however, the injury to brain and associated structures is considered less severe in elevated fractures, due to the characteristic tangential impact, compared to depressed fractures which result from a perpendicular impact, with a more direct vector of force transmission to the brain.<sup>[8]</sup> For the same reason, the degree of scalp and bone injury in elevated fractures may be relatively large compared to that of the underlying brain, as much of the incident force is dissipated tangential to and away from the cortical surface,<sup>[1,16]</sup> this may account for the relatively good presenting GCSs seen in our series.

Common underlying injuries include dural laceration, brain contusion, and epidural hematoma.<sup>[3,14]</sup> Most cases of elevated skull fracture are associated with dural breach, as seen in all the eight patients in this study, but a few cases of intact dura have been reported.<sup>[12-14,16]</sup> Though we did not find an associated epidural hematoma in any of our patients, we consider the possibility that in some of the cases, the elevated bone fragment may have allowed egress of the associated hematoma before presentation.

Noncontrast cranial computed tomography is the investigation of choice for elevated skull fracture because it reveals bony abnormality as well as any underlying hematoma and brain parenchymal injury.<sup>[5,9,10,12,14,16,18]</sup> In cases of suspected superior sagittal sinus occlusion, CT angiography is indicated.<sup>[20]</sup> All patients in this study had cranial CT scan. Angiography was not indicated in any of them.

Elevated skull fractures are usually managed in line with the basic principles of compound skull fracture management such as early recognition and prompt

intervention with broad-spectrum antibiotics, wound debridement, removal of loose bone fragments, and dural repair.<sup>[1,5-13]</sup> Dural repair may be achieved by simple closure when feasible, or by grafting using pericranium, temporalis fascia, or fascia lata.<sup>[10,11]</sup> In this study, these principles were followed and dural repair was achieved by simple closure in two cases: autogenous temporalis fascia graft in one and autogenous pericranial graft in the other five. On the rare occasion, repair of dural rent has been avoided due to the close proximity of the rent to the superior sagittal sinus as was reported by Abu Talha *et al.* Instead, the dural tear was closed with gelfoam.<sup>[20]</sup>

The elevated bone flap at the fracture site has been handled in various ways in previous reports. These include replacement after thorough cleaning and washing, storage away for future cranioplasty due to massive brain swelling, or discarding the bone altogether due to gross wound contamination.<sup>[13,14,16]</sup> This wide range of options suggests that the decision on handling the bone flap should be individualized. The washing and placement of the elevated bone flap in a subcutaneous abdominal pouch for future autologous cranioplasty is an option worth considering in patients with significant wound contamination and delayed presentation, especially in resource-challenged environments like ours where functional bone bank facilities are not available.

The outcome of elevated skull fractures generally depends on the amount of contamination, presence or absence of dural breach, underlying brain injury, appropriate and timely antibiotic and antiepileptic medication, trauma-surgery interval, and quality of wound debridement.<sup>[14,16]</sup> Early surgery is indicated to avoid complications such as meningitis, brain abscess, cerebrospinal fluid fistula, or even death.<sup>[8,18,20]</sup> The apparent delays in surgical intervention were largely due to delayed presentation to our unit. A focused study and intervention on the reasons for this delay may help ensure earlier presentations, and by extension, shorten the trauma-surgery intervals.

With proper management, elevated skull fractures carry a better prognosis than depressed fractures.<sup>[8,11,13,16,18,20]</sup> Only few mortalities have been reported in literature, and delayed surgical intervention is a contributing factor.<sup>[8]</sup> It was instructive that, despite the grotesque appearance of these patients at presentation, the odds favored survival See Figure 3c.

## CONCLUSIONS

Elevated skull fractures are increasingly gaining recognition in literature, and may be more common than previously thought. The injury mechanism is usually striking. Outcome is generally good and rewarding.

### Declaration of patient consent

The authors certify that they have obtained all appropriate patient consent forms. In the form the patient(s) has/have given his/her/their consent for his/her/their images and other clinical information to be reported in the journal. The patients understand that their names and initials will not be published and due efforts will be made to conceal their identity, but anonymity cannot be guaranteed.

### Financial support and sponsorship

Nil.

### Conflicts of interest

There are no conflicts of interest.

### REFERENCES

1. Ralston BL. Compound elevated fractures of the skull. *J Neurosurg* 1976;44:77-9.
2. Agrawal A. Elevated skull fracture. *PAJT* 2014;3:85-6.
3. Sendjaja AN, Sutiono B, Faried A. Open depressed and compound elevated skull fracture over the superior sagittal sinus: A case report. *J Surg Surg Res* 2016;2:1-4.
4. Kaye A. Head injury. *Essential Neurosurgery*. Singapore: Churchill; 1991. p. 59-80.
5. Bhaskar S. Compound "elevated" fracture of the cranium – A case report. *Neurol India* 2010;58:149.
6. Nitin G, Devi Indira BM. Elevated skull fracture. *Indian J Neurotrauma* 2007;4:133.
7. Verdura J, White RJ. Letter: Compound elevated skull fractures. *J Neurosurg* 1976;45:245.
8. Adeolu AA, Shokunbi MT, Malomo AO, Komolafe EO, Olateju SO, Amusa YB, *et al.* Compound elevated skull fracture: A forgotten type of skull fracture. *Surg Neurol* 2006;65:503-5.
9. Mohindra S, Singh H, Savardekar A. Importance of an intact dura in management of compound elevated fractures; a short series and literature review. *Brain Inj* 2012;26:194-8.
10. Borkar SA, Prasad GL, Gupta DK, Sinha S, Mahapatra AK. Compound elevated skull fracture: A clinical series of three patients with a review of the literature. *Turk Neurosurg* 2013;23:514-7.
11. Chhiber SS, Wani MA, Kirmani AR, Ramzan AU, Malik NK, Wani AA, *et al.* Elevated skull fractures in pediatric age group: Report of two cases. *Turk Neurosurg* 2011;21:418-20.
12. Balasubramaniam S, Tyagi DK, Savant HV. Everted skull fracture. *World Neurosurg* 2011;76:479.e1-3.
13. Agrawal A, Kumar SS, Reddy UV, Hegde KV, Subrahmanyam BV. Compound elevated skull fracture: Should we incorporate in skull fracture classification? *Int J Crit Illn Inj Sci* 2015;5:227-9.
14. Kumar J, Prakash A, Harsh V, Kumar A. Elevated fracture of skull in pediatric age group: A series of five patients with review of literature. *Asian J Neurosurg* 2016;11:75.
15. Adeolu AA, Akinbo OC. Gun shot injury as a cause of elevated skull fracture. *J Neurosci Rural Pract* 2012;3:219-20.
16. Sharma R, Kumar A, Bhat DI, Devi BI. Compound elevated skull fractures in adults: A series of five patients and review of literature. *Indian J Neurotrauma* 2012;9:112-6.
17. Agrawal A, Subrahmanyam BV, Malleswara Rao G. Blast injury causing extensive brain injury and elevated skull fracture. *Indian J Neurotrauma* 2014;1:64-7.
18. Borkar SA, Sinha S, Sharma BS. Post-traumatic compound elevated fracture of skull simulating a formal craniotomy. *Turk Neurosurg* 2009;19:103-5.
19. Aniruddha T, Devi B, Arivazhagan A. Traumatic avulsion of cranial bone flap simulating craniotomy. *Indian J Neurotrauma* 2008;5:26995409.
20. Abu Talha K, Selvapandian S, Asaduzzaman K, Selina F, Rahman M, Riad M, *et al.* Compound elevated skull fracture with occlusion of the superior sagittal sinus. A case report. *Kobe J Med Sci* 2009;54:E260-3.