

Original Article

The use of Sural Island Musculo Fasciocutaneous Flap, in the Management of Chronic Osteomyelitis of the Tibia

KO Opara, IC Nwagbara¹

Department of Surgery,
Plastic Surgery Division, Imo
State University Teaching
Hospital, ¹Department
of Surgery, Orthopaedic
Surgery Division, Imo State
University Teaching Hospital
Orlu, Imo, Nigeria

ABSTRACT

Background: The management of soft-tissue defects following surgery for chronic osteomyelitis of the tibia is challenging. It often requires complex reconstructive procedures, especially when the distal third of the tibia is involved. We present a relatively simple method of addressing these defects. **Aim:** This study aims to report our experience with the use of the sural Island musculo fasciocutaneous flap in the management of osteomyelitis of the tibia. **Materials and Methods:** Consecutive patients with osteomyelitis of the tibia requiring soft-tissue cover were managed using the sural Island musculo fasciocutaneous flap, and the outcome was analyzed. The study was prospective in nature. **Results:** There were 21 patients, 15 males and 6 females. Their ages ranged from 21 years to 62 years. Most (71%) were in the 3rd and 4th decades of life. Twelve patients had involvement of the distal third of the tibia, eight involved the middle third, while five patients had involvement of the proximal third. Most of the patients (17) developed osteomyelitis following open fractures of the tibia; thirteen of these were from road crashes and four from gunshot injuries. Four patients developed osteomyelitis through the hematogenous route. Flap sizes ranged from 8 × 7 cm to 16 × 11 cm. There was tip necrosis in 2 flaps and full survival in 19 flaps. The flaps with partial necrosis were managed by simple dressing. Fifteen patients (71%) had cessation of drainage within 4 weeks of surgery. Two patients presented with recurrence of infection within the period of follow-up. Mean follow-up period was 23 months. All donor sites were skin grafted primarily, with 95%–100% graft take. **Conclusion:** The sural Island musculo fasciocutaneous flap is a reliable source of richly vascularized soft tissue for the management of dead space and soft-tissue defects in chronic osteomyelitis of the tibia. It has the added advantage of providing sizeable tissue, with good reach to all segments of the tibia.

KEYWORDS: *Chronic, osteomyelitis, sural musculo fasciocutaneous flap, tibia*

Date of Acceptance:
29-Mar-2018

INTRODUCTION

Chronic osteomyelitis is a common problem in our environment. Being an infection of osseous tissue with significant cicatrization and relative poor vascularization, effective treatment usually requires radical excision of sequestra, sclerotic bone, scar tissue, and draining sinuses, under the cover of appropriate antibiotics.^[1] The challenge over the years has however been the management of the dead space and soft-tissue defect following surgical debridement.^[1,2] Various methods including the use of skin grafts, cancellous

bone grafts, free omental graft, antibiotic-loaded polymethylmethacrylate, fasciocutaneous flaps, and muscle flaps have been suggested.^[3-9]

Of these, the muscle flaps have consistently proved more effective in controlling infection and stimulating healing.^[10] The recalcitrant nature of osteomyelitis has been associated with a marked decrease in the blood

Address for correspondence: Dr. KO Opara,
P.O. Box 442, Woji, Port Harcourt, Nigeria.
E-mail: kin2para@yahoo.co.uk

This is an open access journal, and articles are distributed under the terms of the Creative Commons Attribution-NonCommercial-ShareAlike 4.0 License, which allows others to remix, tweak, and build upon the work non-commercially, as long as appropriate credit is given and the new creations are licensed under the identical terms.

For reprints contact: reprints@medknow.com

How to cite this article: Opara KO, Nwagbara IC. The use of sural Island musculo fasciocutaneous flap, in the management of chronic osteomyelitis of the tibia. *Niger J Clin Pract* 2018;XX:XX-XX.

Access this article online	
Quick Response Code: 	Website: www.njcponline.com
	DOI: 10.4103/njcp.njcp_173_17
	PMID: *****

supply of infected bone,^[11] thus muscle with its rich vascularity is well suited for the management of defects created following debridement. Indeed, the placement of vascularized muscle flap over the involved bone after adequate debridement has permitted salvage of infected extremities that in a previous era would have been amputated.^[12]

The challenge here however is the limited choices of local muscle flaps available for use, especially in the distal 3rd of the leg which incidentally is the most common region involved. This limitation often necessitates the use of free muscle flaps. The use of free flaps however comes with its attendant challenges which include the need for microsurgical skills and facilities and lengthy operating time and hospital stay.^[13,14] These challenges are even more daunting in a resource-poor environment like ours.

A flap that is relatively simple to raise without the need for microvascular surgery, and provides both skin and muscle components is an excellent option in the management of these defects.

In this study, we present our experience with the use of an island myocutaneous flap pedicled on the sural neurovascular axis, in the management of dead space and soft-tissue defects following radical debridement in chronic osteomyelitis of the leg.

MATERIALS AND METHODS

This was a prospective study carried out from June 2012 to July 2014. Consecutive patients with osteomyelitis of the tibia requiring soft-tissue cover were managed using the island myocutaneous flap based on the sural neurovascular axis.

An informed consent was obtained from each patient before being recruited into the study. Each of the patients was then worked up for surgery. The investigations conducted were as follows: erythrocyte sedimentation rate (ESR), C-reactive protein, full blood count, urinalysis, and X-ray of the affected limb.

Data on age, sex, etiology, segment of the tibia involved, flap size, and time to control of drainage were collected and analyzed using descriptive statistics.

Each patient was followed up for a minimum of 6 months.

Surgical technique

The surgeries were done under spinal anesthesia. Routine saucerization, sequestrectomy, and curettage were first carried out with the patient in the supine position [Figure 1b].

A tourniquet was placed in the proximal thigh after limb elevation for about 5 min. The patients were then placed in either prone or lateral position.

Anatomically, the sural myofasciocutaneous island flap consisted of an islet of skin and subcutaneous fat, the superficial and deep fascia, sural nerve, lesser saphenous vein, the superficial sural artery, and a segment of one of the gastrocnemius muscle bellies.

The segment of the muscle belly at the junction of the upper and middle third of the leg was usually harvested so as to incorporate a branch of the sural artery usually supplying the muscle at this point.

During flap elevation, the muscle component is secured to the deep fascia and skin with sutures to prevent shearing forces from disrupting its delicate blood supply [Figure 1c].

Traction on the flap was through stay sutures at the tip, anchoring all the soft-tissue components of the flap, as well as the neurovascular axis.

Transposition of the flap was usually through a subcutaneous tunnel roomy enough to accommodate the pedicle without tension.

Drains were usually placed beneath the flap as well as its pedicle.

Dressings were applied with good padding at the heel and proximal to the pivot of the flap. This was to ensure that the pedicle of the flap was not compressed with the patient in the supine position.

RESULTS

There were 21 patients, 15 males and 6 females. All the patients completed the study.

Their ages ranged from 21 years to 62 years. Fifteen (71%) of the patients were in the 3rd and 4th decades of life [Figure 2].

Twelve (57%) of the patients had involvement of the distal third of the tibia, eight (38%) involved the middle third, while the proximal third of the tibia was involved in five (24%) of the patients [Figure 3].

A vast majority of our patients (17) developed osteomyelitis following open fractures of the tibia; road traffic accidents accounting for 13 (77%) of these and gunshot injuries for the other 4 (23%). Four patients developed osteomyelitis through the hematogenous route.

Flap sizes ranged from 8 × 7 cm to 16 × 11 cm.

There was tip necrosis of 2 flaps and full survival of 19 flaps. The flaps with partial necrosis were managed by simple dressing.

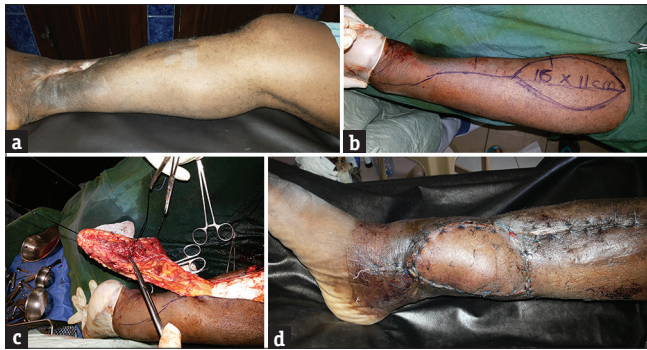


Figure 1: (a) Osteomyelitis affecting the distal tibia. (b) Marking for distally based sural myofasciocutaneous flap to be elevated. (c) Sural island flap elevated with a segment of the gastrocnemius muscle. (d) Ten days after surgery showing complete flap survival

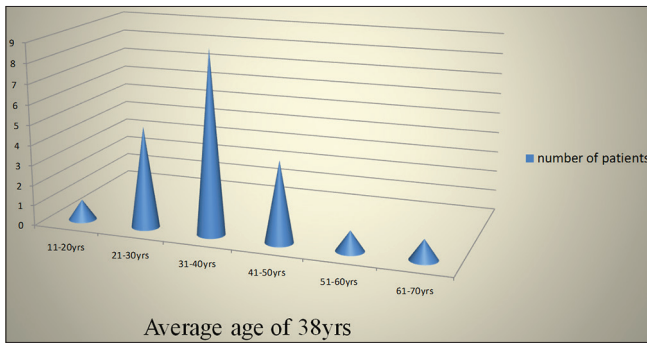


Figure 2: Age distribution

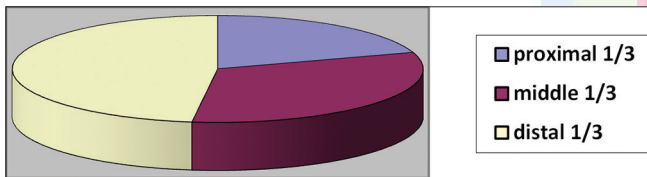


Figure 3: Tibial segment involved

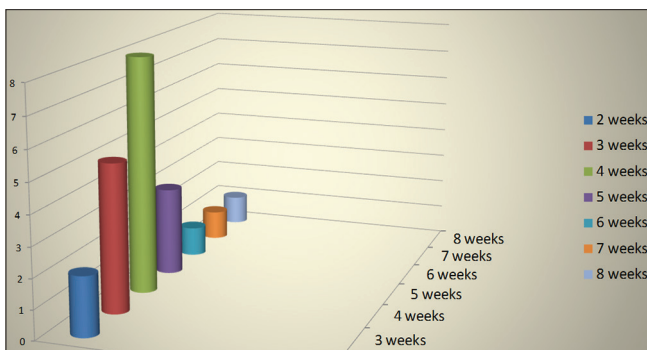


Figure 4: Time to control of drainage

In the flaps with partial necrosis, the necrosis only involved parts of the skin. The muscle appeared not to have been involved.

The flaps showed minimal flap edema in the early postoperative period, which commonly resolved within 2 weeks.

Fifteen patients had cessation of drainage within 4 weeks of surgery. In one patient, drainage persisted up to the 8th week after surgery [Figure 4].

Within the study period, 19 patients had complete cure of the osteomyelitis as evidenced by cessation of drainage and normalization of C-reactive protein and ESR values. The remaining two patients had persistence of infection.

All donor sites were skin grafted primarily, with 95%–100% graft take.

DISCUSSION

Chronic osteomyelitis is a common pathology encountered in surgical practice, especially in the developing societies. It is an infection of bone and osseous tissue associated with significant fibrosis.^[1] Appropriate treatment involves radical debridement of nonviable bone and scarified focus of infection, obliteration of the dead space, and skin cover.^[1] The use of muscle flaps in the management of the dead space has consistently given the best results.^[10,15] Muscle flaps have been shown experimentally to be resistant to bacterial infection, showing rapid recovery when inoculated with a bacterial suspension.^[16] They are also thought to increase vascular supply to the wound, thus improving delivery of systemic antibiotics and the host defense mechanism.^[17] Several authors have reported good control of infection, when the residual dead space in the bone following debridement is obliterated using a muscle flap.^[10] The challenge however is usually in the availability of a local muscle flap for this purpose. This is especially so in the distal 3rd of the leg, which incidentally is the most common region of the leg involved in our series and corroborated in other studies. For these defects involving the distal 3rd of the leg, free muscle transfers are often cited as the best option, especially when sizeable muscle tissue is needed.^[8,9,18] Considering the challenges of free tissue transfers which include the need for microsurgical skills and facilities and lengthy operating time and hospital stay,^[13,14] this option is largely out of reach in a resource-poor environment like ours. A simpler option of a pedicled flap, without the need for microsurgical facilities, providing muscle for dead space obliteration Figure 4, as well as skin cover, and with a wide arc of rotation, capable of reaching all segments of the tibia was described by Yoshimura *et al.* in 1989.^[19] It was an island myocutaneous flap pedicled on the peroneal artery and vein and termed a “peroneal myocutaneous island flap.” They described its use in 10 patients with posttraumatic osteomyelitis and cited the following advantages: (1) immediate filling of dead space and

cover of skin defect, (2) a laterally based pedicle, long enough to permit transfer to anywhere from the upper knee to the foot, (3) one-stage procedure, allowing early mobilization, (4) a muscle graft which can be cut to exact size, minimizing disturbance of function, and (5) a muscle graft with a good circulation and resistance to infection. The pedicled sural island myocutaneous flap shares these advantages and even more. Its vascular pedicle running in the subcutaneous plane of the posterior midline is often away from the zone of injury in distal leg trauma, unlike the peroneal artery and vein whose position along the posterior border of the fibula puts it at risk in open fractures of the leg. Hence, Yoshimura *et al.* did a preoperative angiogram in all their patients to evaluate vascular damage before using the peroneal myocutaneous island flap. Furthermore, the sural island myocutaneous flap centered on the posterior midline of the upper and middle thirds of the leg has the potential for providing more tissue for the management of more extensive defects: The largest size of skin paddle reported in Yoshimura's series was 13 × 4 cm compared to 16 × 11 cm in ours. Indeed, flap sizes up to 20 × 12 cm based on the sural neurovascular axis have been reported.^[20] Furthermore, the sural myocutaneous flap taking its muscle component from the gastrocnemius muscle belly is potentially able to provide more bulk than the peroneal myocutaneous flap which incorporates part of the soleus muscle.

In our experience of raising the sural island fasciocutaneous flap, we have always noted a vascular twig running from the median sural vessel into the medial belly of the gastrocnemius around the junction of the upper and middle thirds of the leg. Incorporating this vessel into the sural island myocutaneous flap allows us differential inset of the muscle and skin components of the flap, thus making this flap quite adaptable in the most complex of defects.

In this study, the infectious process was eradicated in 90% of the patients. This is similar to reports from other series on the use of muscle flaps to provide soft-tissue coverage after debridement following osteomyelitis of the tibia.^[21,22] The sural island myocutaneous flap therefore compares favorably with other muscle flaps in its ability to provide good circulation to the dead space created following debridement and thereby resist infection.

CONCLUSION

The sural island musculo fasciocutaneous flap is a reliable source of richly vascularized soft tissue for the management of dead space and soft-tissue defect in chronic osteomyelitis of the tibia. It has the added

advantage of providing sizeable tissue, with good reach to all segments of the tibia.

Declaration of patient consent

The authors certify that they have obtained all appropriate patient consent forms. In the form the patient(s) has/have given his/her/their consent for his/her/their images and other clinical information to be reported in the journal. The patients understand that their names and initials will not be published and due efforts will be made to conceal their identity, but anonymity cannot be guaranteed.

Financial support and sponsorship

Nil.

Conflicts of interest

There are no conflicts of interest.

REFERENCES

1. Walenkamp GH, van Roermund PM, van Horn JR. One hundred years of orthopedics in the Netherlands. IX. The treatment of chronic osteomyelitis. *Ned Tijdschr Geneesk* 1998;142:1124-30.
2. Kelly PJ. Infections of bones and joints in adult patients. In: *Instructional Course Lectures, The American Academy of Orthopedic Surgical*. Vol. 26. St. Louis: C.V Mosby; 1977. p. 3-13.
3. Azuma H, Kondo T, Mikami M, Harii K. Treatment of chronic osteomyelitis by transplantation of autogenous omentum with microvascular anastomosis. A preliminary report. *Acta Orthop Scand* 1976;47:271-5.
4. Reid R. The use of large reverend in grafts in the healing of chronic osteomyelitis. *Bull John Hopkins Univ* 1922;33:386-8.
5. Fitzgerald RH Jr., Ruttle PE, Arnold PG, Kelly PJ, Irons GB. Local muscle flaps in the treatment of chronic osteomyelitis. *J Bone Joint Surg Am* 1985;67:175-85.
6. Harrison SH. Fractures of the tibia complicated by skin loss. *Br J Plast Surg* 1968;21:262-76.
7. Knight MP, Wood GO. Surgical obliteration of bone cavities following traumatic osteomyelitis. *J Bone Joint Surg* 1945;27:547-56.
8. Mathes SJ, Alpert BS, Chang N. Use of the muscle flap in chronic osteomyelitis: Experimental and clinical correlation. *Plast Reconstr Surg* 1982;69:815-29.
9. May JW Jr., Gallico GG 3rd, Lukash FN. Microvascular transfer of free tissue for closure of bone wounds of the distal lower extremity. *N Engl J Med* 1982;306:253-7.
10. Koval KJ, Meadows SE, Rosen H, Silver L, Zuckerman JD. Posttraumatic tibial osteomyelitis: A comparison of three treatment approaches. *Orthopedics* 1992;15:455-60.
11. Lew DP, Waldvogel FA. Osteomyelitis. *Lancet* 2004;364:369-79.
12. Robert HF, Paul ER, Phillip GA, Patrick JK, George BI. Local muscle flaps in the treatment of chronic osteomyelitis. *J Bone Joint Surg* 1985;67:175-85.
13. Rajacic N, Gang RK, Darweesh N, Abdul Fetah N, Kojic S. Reconstruction of soft tissue defects around the knee with the use of the lateral sural fasciocutaneous artery island flap. *Eur J Plast Surg* 1999;22:12-6.
14. Shim JS, Kim HH. A novel reconstruction technique for the knee and upper one third of lower leg. *J Plast Reconstr Aesthet Surg* 2006;59:919-26.

15. Anthony JP, Mathes SJ, Alpert BS. The muscle flap in the treatment of chronic lower extremity osteomyelitis: Results in patients over 5 years after treatment. *Plast Reconstr Surg* 1991;88:311-8.
16. Chang N, Mathes SJ. Comparison of the effect of bacterial inoculation in musculocutaneous and random-pattern flaps. *Plast Reconstr Surg* 1982;70:1-9.
17. Gosain A, Chang N, Mathes S, Hunt TK, Vasconez L. A study of the relationship between blood flow and bacterial inoculation in musculocutaneous and fasciocutaneous flaps. *Plast Reconstr Surg* 1990;86:1152-62.
18. May JW Jr., Gallico GG 3rd, Jupiter J, Savage RC. Free latissimus dorsi muscle flap with skin graft for treatment of traumatic chronic bony wounds. *Plast Reconstr Surg* 1984;73:641-51.
19. Yoshimura M, Shimada T, Matsuda M, Hosokawa M, Imura S. Treatment of chronic osteomyelitis of the leg by peroneal myocutaneous Island flap transfer. *J Bone Joint Surg Br* 1989;71:593-6.
20. Opara KO, Nwagbara IC, Jiburum BC. Reverse sural Island flap elevated from the proximal third of the leg: Its reliability and versatility in distal leg and foot reconstruction. *Eur J Plast Surg* 2011;34:273-8.
21. Weiland AJ, Moore JR, Daniel RK. The efficacy of free tissue transfer in the treatment of osteomyelitis. *J Bone Joint Surg Am* 1984;66:181-93.
22. Al Kelabi AE, Shabaa KJ, Al-Obaidi M. The role of muscle flaps in treatment of chronic osteomyelitis. *Kufa Med J* 2009;12:388-93.

