

Case Report

Ruptured Ectopic in Heterotopic Pregnancy: Management and Spontaneous Vertex Delivery of a Live Baby at Term

RC Onoh, BN Ejikeme¹, AB Onwe¹, OU Asiegbu¹

Reproductive Endocrinology and Infertility Unit, Department of Obstetrics and Gynaecology, Federal Teaching Hospital, Abakaliki, Ebonyi, ¹Department of Obstetrics and Gynaecology, Federal Teaching Hospital, Ebonyi State, Nigeria

ABSTRACT

Spontaneous heterotopic pregnancy is an uncommon clinical condition in which there is a simultaneous development of intrauterine and extrauterine pregnancies. It is a life-threatening emergency when the ectopic ruptures. We present Mrs. EC, a 27-year-old G₁P⁰ + ⁰ with a family history of multiple gestations who had a heterotopic pregnancy at a gestational age of 7 weeks. She presented with features of threatened miscarriage at early pregnancy with an ultrasound confirmation of intrauterine pregnancy. The diagnosis of ruptured ectopic pregnancy coexisting with intrauterine gestation was made with ultrasound findings as well as clinical features necessitating emergency exploratory laparotomy. Thereafter, pregnancy was carried to term, and she delivered a live male baby that weighed 3.0 kg. Heterotopic pregnancy should be sort for in all pregnancies during the early scan, especially in those with predisposing factors for multiple gestations and risk factors for ectopic gestation. A high index of suspicion is necessary for making a diagnosis in women with intrauterine pregnancy, with or without symptoms of ectopic gestation, and irrespective of the existence of risk factors for ectopic pregnancy.

KEYWORDS: *Exploratory laparotomy, heterotopic pregnancy, live baby, ruptured ectopic, vaginal delivery*

Date of Acceptance:
20-Jun-2017

INTRODUCTION

The simultaneous development of an intrauterine and ectopic pregnancy is an extremely rare occurrence in natural conception but has been reported with an increasing frequency in recent times due to increased assisted reproduction, improved ability to detect ectopic pregnancies and pelvic inflammatory disease.^[1,2]

It presents in an obscure pattern as an acute life-threatening emergency when the ectopic ruptures with increased fetal losses. A high index of suspicion is, therefore, a sine qua non to making a diagnosis. The incidence ranges from 1:7000 to 1:30,000 for naturally conceived pregnancy, to 1-3:100 for assisted reproduction. The incidence is 1:45 when >4 embryos are transferred in assisted reproduction. With the rising incidence of multiple pregnancies due to assisted fertility management and the increasing incidence of ectopic pregnancy due to increasing risk factors, the risk of heterotopic pregnancies is becoming common.^[3] A figure

of 1 in 4000–7000 pregnancies is currently quoted for heterotopic gestation.^[4]

Despite the continued increase in the incidence of an ectopic pregnancy, the rate of death from ectopic pregnancy has declined in developed countries primarily due to earlier diagnosis before tubal rupture which occurs in over 70% of cases.^[5]

The predisposing factors to ectopic pregnancy include early age of sexual intercourse, increasing maternal age, multiple sexual partners, pelvic infections, history of infertility and use of fertility drugs, previous ectopic pregnancies, and previous pelvic surgeries.^[4] Even when these predisposing factors are present diagnosis of heterotopic pregnancy may still be a mirage as the

Address for correspondence: Dr. RC Onoh, Reproductive Endocrinology and Infertility Unit, Department of Obstetrics and Gynaecology, Federal Teaching Hospital, PMB 102, Abakaliki 480001, Ebonyi State, Nigeria. E-mail: onoh406@yahoo.com

Access this article online

Quick Response Code:



Website: www.njcponline.com

DOI: 10.4103/njcp.njcp_67_16

This is an open access article distributed under the terms of the Creative Commons Attribution-NonCommercial-ShareAlike 4.0 License, which allows others to remix, tweak, and build upon the work non-commercially, as long as the author is credited and the new creations are licensed under the identical terms.

For reprints contact: reprints@medknow.com

How to cite this article: Onoh RC, Ejikeme BN, Onwe AB, Asiegbu OU. Ruptured ectopic in heterotopic pregnancy: Management and spontaneous vertex delivery of a live baby at term. *Niger J Clin Pract* 2018;21:672-7.

ectopic tend to pose a masquerading effect, especially in developing countries where the diagnosis is difficult and delayed. This masquerading effect usually becomes revealed as ruptured ectopic pregnancy with possible morbidity and mortality.

Ultrasonography has been found to be promising in the confirmatory diagnosis of an ectopic pregnancy.^[6] Real-time ultrasound shows fetal heart motion. Real-time ultrasonography is of great help in establishing the diagnosis of unruptured ectopic pregnancy. Its primary role lies in documenting a normal intrauterine pregnancy from 5 to 6 weeks of gestation. The goal of bedside ultrasonography is to diagnose an intrauterine pregnancy as heterotopic pregnancy; although, it is rare in occurrence. Ultrasound examination may be of secondary importance in supporting a diagnosis of possible ectopic pregnancy by showing an adnexa mass or fluid within the cul-de-sac or both. Ultrasound evaluation, especially transvaginal scan is invaluable but where there result is equivocal, ancillary tests should be done.^[7]

The ultrasonographic findings of a ruptured ectopic in heterotopic pregnancy are fluid particularly hemorrhagic in the pouch of Douglas, adnexal masses, or hematosalpinx with viable intrauterine gestation. Transvaginal ultrasound provides improved resolution allowing descriptions of early embryonic development characteristics. Bedside ultrasonography is the test of choice in unstable patients.^[7,8] Isolated free fluid in the pelvis is rarely the only sonographic findings. The presence of an adnexal mass and/or free pelvic fluid is a strong predictor of an ectopic pregnancy.

Heterotopic pregnancy when diagnosed is managed by removal of the ectopic and conservation of the intrauterine pregnancy. The survival rate of the uterine fetus of an ectopic pregnancy in heterotopic gestation is about 70%.^[9]

We, therefore, report a case of heterotopic pregnancy with ruptured ectopic following delayed diagnosis and term delivery after exploratory laparotomy and repair of ruptured fimbria ectopic pregnancy.

CASE REPORT

A case of a 27-year-old G₁P⁰ + ⁰ health worker whose last menstrual period was 27/12/14, at a gestational age of 7 weeks + 1 day. She presented on 15/02/2015 with complaints of lower abdominal pain and bleeding per vagina of 3 days before the presentation.

Lower abdominal pain started after a long-distance journey. It was cramping in nature located in the suprapubic area, but subsequently increased in intensity and became generalized.

About 6 h later, there was associated bleeding per vagina which was bright-red in color with an estimated blood loss of 100 ml (she changed two well-soaked pads for 2 days).

She initially presented to a specialist private hospital where she was managed as a case of threatened abortion following clinical findings and an ultrasound that confirmed viable intrauterine pregnancy but was referred to this center for expert management due to worsening condition and sudden collapse.

Index pregnancy was desired and spontaneously conceived. Two weeks before the presentation, the pregnancy was detected with urinary pregnancy test after which she had a 4-day scanty spotting per vaginam which necessitated an ultrasound which confirmed intrauterine pregnancy, but did not identify the ectopic pregnancy. The bleeding stopped spontaneously. There was a past gynecological history of abnormal vaginal discharge before marriage which was managed syndromically. There was also a positive family history of twinning.

She is a health worker and the only wife of a businessman. She takes alcohol sparingly but never used tobacco in any form.

On examination, she was fully conscious and alert, afebrile, anicteric, and pale. Respiratory rate was 32 cycles/min and the lung zones were clinically clear. Her pulse rate was 118 beats/min and blood pressure was 100/50 mmHg. The heart sound I and II were heard and there was no murmur. The abdomen was full and moved with respiration. There was suprapubic fullness. There was generalized abdominal tenderness and guarding. Paracentesis abdominis yielded 5 ml of nonclotting blood.

The vulva and vagina were smeared with dark colored blood. Cervix was tubular with blood clot plugging the os and this was gently removed. Pouch of Douglas was full. Examining was stained with altered blood. An ultrasound done yielded viable intrauterine embryo with a crown-rump length of 14.9 mm giving a gestational age of 7 weeks, and there were areas of hypoechogenic density intraabdominally showing hemoperitoneum following which ultrasound diagnosis of ruptured ectopic with viable intrauterine gestation in a heterotopic gestation was made.

A diagnosis of ruptured ectopic with viable intrauterine pregnancy (Heterotopic pregnancy) in a primigravida was made. She was counseled for an exploratory laparotomy and informed consent was obtained. Resuscitative measures were instituted immediately with cognizance to airway, breathing, and circulation. The

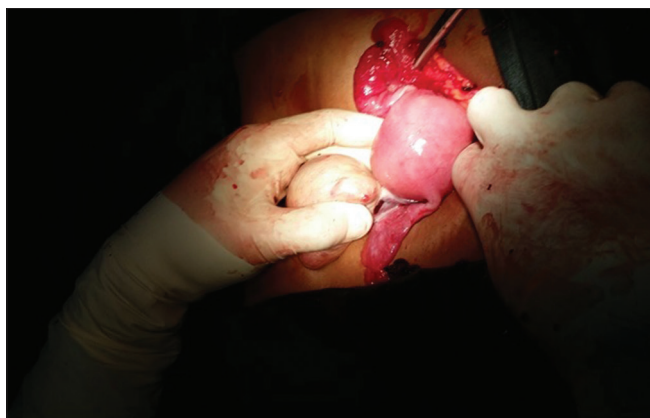


Figure 1: Showing heterotopic pregnancy with evidence of ruptured left ectopic pregnancy, corpus luteum of pregnancy on right ovary and normal right tube

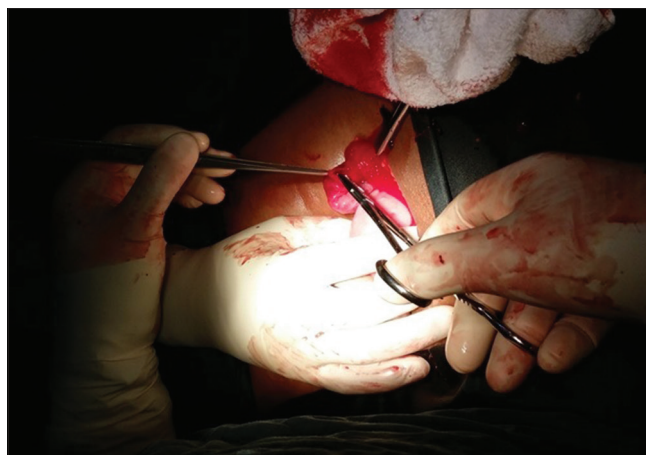


Figure 2: Showing ruptured left tubal ectopic pregnancy




Figure 3: Operation site with drain

packed cell volume was 12%, urinalysis was normal and retroviral screening test was negative. The blood group was O positive. Hepatitis B surface antigen was negative, and venereal disease research laboratory was negative. Two units of blood were crossmatched and made available. She received 2 l of fluid before the surgery and the presentation operation interval was 1 h. She was also given oxygen by face mask at a rate of 6 l/min. Vital signs were monitored continuously with the patient monitor.

Exploratory laparotomy and repair of ruptured left fimbria tube were done on 15/2/15 under general anesthesia. The repair was done with interrupted vicryl 3/0. The intraoperative findings were hemoperitoneum approximately 1 l with clots, the right ovarian cyst about 6 cm in diameter probably the corpus luteum of pregnancy, bulky uterus about 8 weeks size with normal right tube, edematous left tube with linear ruptured fimbria ectopic gestation that was actively bleeding measuring about 3 cm in length, and left ovary was normal as shown in Figures 1 and 2. The total estimated blood loss was 1200 ml. She tolerated the surgery and had a brisk recovery. The patient was monitored continuously in the intensive care unit with patient monitor, and vital signs appreciated tremendously. An abdominal drain was left *in situ* which

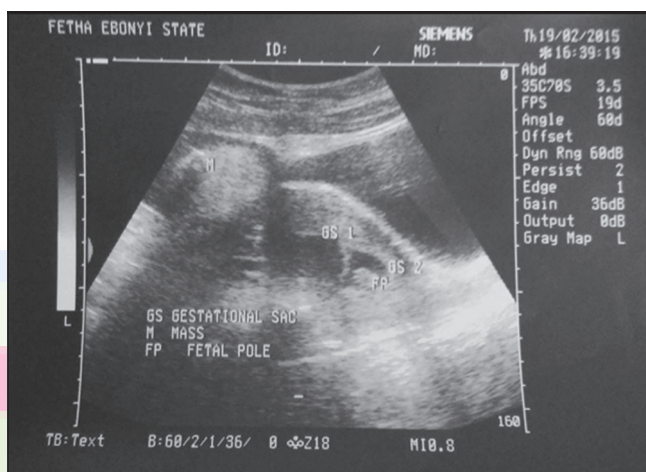


Figure 4: Showing ultrasound findings 3days post operation

was removed on the 3-day postoperation on becoming inactive as shown in Figure 3. Specimen from the site of rupture with blood clots was sent for histology. Macroscopy showed dark brownish tissue weighing 8 g and measuring 5 cm × 3 cm × 2 cm. It is friable in consistency.

Microscopy showed chorionic villi with trophoblastic cells and blood clots.

Feature showed products of conception.

Diagnosis: products of conception from the left tubal ectopic pregnancy.

Two units of fresh whole blood were transfused. She received 1 l of normal saline alternated with 5% dextrose saline 8 h, 1 g of ceftriaxone 12 h, 500 mg of metronidazole 8 h, and 60 mg of pentazocine 6 h for 48 h. On tolerating orally, the parenteral drugs were converted to oral cefpodoxime 200 mg twice daily, metronidazole 400 mg thrice daily for 5 days, and 1000 mg paracetamol thrice daily for 3 days.

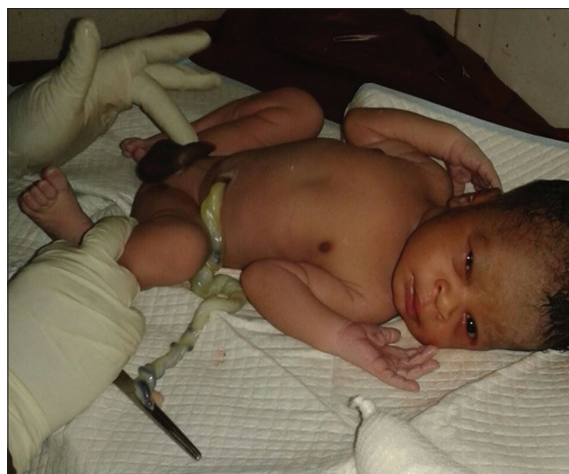

Figure 5: Showing a live male baby delivered at 40 weeks and 2 days

Her packed cell volume was 25% after blood transfusion, and she refused a further blood transfusion. She was placed on routine hematinics. A repeat ultrasound showed a viable single intrauterine embryo with a crown-rump length of 16.4 mm which corresponded to 8 weeks of gestation as shown in Figure 4. She was discharged on strict bed rest and was advised to be regular with her antenatal care. Cyclogest pessary (Progesterone) 400 mg daily was prescribed, but the patient did not accept the prescription. Oral Duphaston (Dydrogesterone) 10 mg twice daily was later prescribed, but the patient did not receive it as she objected to its use not minding the counseling.

Her packed cell volume at 12 weeks was 31% and she had no complaint. Pregnancy remained uneventful and she was regular with her antenatal visit. She had spontaneous delivery of a live male baby with APGAR 10¹:10⁵ at a gestational age of 40 weeks and 2 days on October 05, 2015 as shown in Figure 5. The baby weighed 3.0 kg and was exclusively breastfed. Puerperium was uneventful. She was counseled on the need for early antenatal booking, and the need to confirm pregnancy as early as 5 weeks gestational age in the next pregnancy as there is an increased risk of recurrence of ectopic pregnancy. Thereafter, mother was discharged to family planning clinic after adequate counseling and baby discharged to infant and child clinic.

DISCUSSION

The greatest challenge of heterotopic pregnancy is in making a diagnosis as the presence of an intrauterine gestation is so satisfying to the obstetrician, and the pregnant woman that any other sac seen is regarded as corpus luteum. This missed diagnosis of heterotopic gestation is also more worrisome and common in developing countries where the ultrasound may not have high resolution to identify an early ectopic gestation.

The early ultrasound done in the index case diagnosed intrauterine gestation with nonvisualization of ectopic gestation necessitating the diagnosis of threatened miscarriage. Usually, misdiagnosis of heterotopic gestation results in increased fetal wastage as well as increased risk of maternal morbidity and mortality. Most recent case reports and case series in developing countries revealed that patients with heterotopic pregnancies are more likely to have tubal rupture and present in hypovolemic shock.^[1] Mrs. EC had ruptured tubal pregnancy with hypovolemic shock.

Heterotopic pregnancy is becoming more frequent due to increased genital tract infection and wider use of assisted reproductive techniques.^[10,11] This is the second case of spontaneous heterotopic pregnancy reported in our institution within a time interval of less than a year, even though the earlier report was a case of bilateral tubal heterotopic pregnancy.^[12] The patient had genital tract infection which was treated syndromically and also has a family history of twinning. She most likely would have had double ovulation with one resulting in intrauterine gestation and the other resulting in tubal ectopic pregnancy. Tenore identified certain risk factors of ectopic gestation of which he opined that pelvic inflammatory disease takes the lead.^[7] It is, therefore, recommended that any genital tract infection should be treated appropriately to avert long-term complications.

Even though, heterotopic pregnancy usually presents a diagnostic difficulty.^[13,14] A high index of suspicion is necessary for diagnosis, especially in those with risk factors or when there are clinical features suggesting heterotopic pregnancy. Suspicious adnexal masses can be investigated with Doppler ultrasound in an attempt to improve sensitivity and specificity. Some researchers have described the fire pattern characterized with a high velocity, low-resistance Doppler signal that is associated with the developing trophoblast.^[15,16] They report that identification of this type of flow pattern in an adnexal mass using transabdominal ultrasound raised the sensitivity for the diagnosis of an ectopic pregnancy from 53% to 73%. They also report a sensitivity of 96% and a specificity of 93% using transvaginal color Doppler. Doppler was not done for our case hence the possible delay in diagnosis and this could have averted the rupture of the ectopic gestation with its resultant maternal morbidities. Furthermore, it has been suggested that women with early pregnancy complications are best cared for in dedicated Early Pregnancy Assessment Units (EPAUs) which offer rapid and definitive ultrasonographic and biochemical assessment at the initial review of the patient.^[17] EPAUs are now considered the gold standard of management for early

miscarriage or ectopic pregnancy as it helps to make prompt diagnosis with facilitated health-care services resulting in shorter length of stay in both emergency departments and outpatient clinics, a reduction in the proportion of women requiring hospital admission and a reduction in the number of women representing to health services, greater patient satisfaction, and reduced cost to patients.^[17] We do not have an EPAU in our facility. Hence, Mrs. EC did not benefit from EPAU as such the heterotopic pregnancy was not diagnosed early resulting in rupture of the ectopic pregnancy.

Ruptured ectopic pregnancy is an emergency and a significant cause of maternal mortality. The index case had a linear rupture on the fimbria end of the left tube with hypovolemic shock and had repair of the ruptured tube. She was also transfused, and an abdominal drain was left *in situ* to ensure that there was no active abdominal bleeding. There are no standardized management recommendations currently for heterotopic gestation.^[1] Factors that determine the management of heterotopic pregnancy include the gestational age and clinical presentation of the patient.^[18] The options of management include salpingectomy, salpingotomy, and salpingostomy through exploratory laparotomy or laparoscopy. Several case reports and series have described successful treatment of a heterotopic pregnancy with transvaginal embryo aspiration of the ectopic under ultrasound guidance followed by the local instillation of hyperosmolar solution, methotrexate, or potassium chloride.^[19-21] Aspiration and instillation could also be done through laparoscopically-guided technique. In hemodynamic instability, exploratory laparotomy is usually done and this is the preferred option in most developing countries due to nonavailability of laparoscopy.

The surgery for Mrs. EC was done fast within 20 min and the uterus was handled gently. These could have contributed to the survival of the intrauterine gestation. This outcome was similar to the experiences of some case reports in which the intrauterine pregnancy progressed to fetal maturity and delivery of a live baby after management of the ectopic in heterotopic pregnancy.^[1,10,22,23]

In conclusion, heterotopic pregnancy still poses a diagnostic difficulty in this modern day obstetrics and gynecological practice, especially in developing countries. However, if diagnosed late as ruptured ectopic pregnancy immediate treatment and resuscitation should be offered as the intrauterine gestation could still progress to fetal maturity and live delivery. It is, therefore, recommended that high index of suspicion should be observed among all pregnancies, especially those with risk factors and clinical features suggestive

of heterotopic gestation. The establishment of EPAU in our facilities will also be very useful in making a prompt diagnosis and effective treatment, thereby ensuring that there are no delays in management of early pregnancy complications.^[17] Obstetricians should also be trained on obstetrics ultrasound with emphasis on early pregnancy scan so that prompt diagnosis of early pregnancy complications are made.^[17]

Declaration of patient consent

The authors certify that they have obtained all appropriate patient consent forms. In the form the patient(s) has/have given his/her/their consent for his/her/their images and other clinical information to be reported in the journal. The patients understand that their names and initials will not be published and due efforts will be made to conceal their identity, but anonymity cannot be guaranteed.

Financial support and sponsorship

Nil.

Conflicts of interest

There are no conflicts of interest.

REFERENCES

1. Ikechukwu E, Adeleni M. Heterotopic pregnancy with live infant. *Ann Afr Med* 2013;12:43-5.
2. Eze JN, Obuna JA, Ejikeme BN. Bilateral tubal ectopic pregnancies: A report of two cases. *Ann Afr Med* 2012;11:112-5.
3. Aneziokoro EA. Heterotopic pregnancy with live twins. *Afr J Reprod Health* 2002;6:117-9.
4. Jurkovic D. Ectopic pregnancy. In: Edmonds DK, editor. *Dewhurst's Textbook of Obstetrics and Gynaecology*. 7th ed. Oxford, UK: Blackwell Publishing; 2007. p. 106-16.
5. Rajkhowa M, Glass MR, Rutherford AJ, Balen AH, Sharma V, Cuckle HS, *et al.* Trends in the incidence of ectopic pregnancy in England and wales from 1966 to 1996. *BJOG* 2000;107:369-74.
6. Ikpeze OC. A critical assessment of the usefulness of abdominal ultrasound in the diagnosis of ectopic pregnancy. *Niger J Surg Sci* 1991;1:25-7.
7. Tenore JL. Ectopic pregnancy: Problem-oriented diagnosis. *Am Fam Phys* 2000;61:1080-8.
8. Lucie M, Montreal QC, Michael C, Halifax NS. Ultrasound evaluation of first trimester pregnancy complications. *J Obstet Gynecol Canada* 2005;161:581-5.
9. Lau S, Tulandi T. Conservative medical and surgical management of interstitial ectopic pregnancy. *Fertil Steril* 1999;72:207-15.
10. Laghzaoui Boukaïdi M, Bouhya S, Sefrioui O, Bennani O, Hermas S, Aderdour M, *et al.* Heterotopic pregnancies: 8 cases. *Gynecol Obstet Fertil* 2002;30:218-23.
11. Umezurike CC, Feyi-Waboso PA. Heterotopic pregnancy with spontaneous vaginal delivery at 36 weeks and laparotomy at term – A case report. *Afr J Reprod Health* 2005;9:162-5.
12. Nwali MI, Ejikeme BN, Onyebuchi AK, Onoh RC, Edegebe FO. Bilateral tubal ectopic gestation: A case report. *Ann Niger Med* 2014;8:45-7.
13. Gazvani MR. Modern management of ectopic pregnancy. *Br J Hosp Med* 1996;56:597-9.
14. Ifenne DI, Shittu SO, Mandara MU. Advanced abdominal

- pregnancy with a live baby. *Trop J Obstet Gynaecol* 1999;16:63-5.
15. Taylor KJ, Ramos IM, Feyock AL, Snower DP, Carter D, Shapiro BS, *et al.* Ectopic pregnancy: Duplex Doppler evaluation. *Radiology* 1989;173:93-7.
 16. Pellerito JS, Taylor KJ, Quedens-Case C, Hammers LW, Scoutt LM, Ramos IM, *et al.* Ectopic pregnancy: Evaluation with endovaginal color flow imaging. *Radiology* 1992;183:407-11.
 17. Iyoke CA, Ugwu OG, Ezugwu FO, Onah HE, Agbata AT, Ajah LC, *et al.* Current approaches for assessment and treatment of women with early miscarriage or ectopic pregnancy in Nigeria: A case for dedicated early pregnancy services. *Niger J Clin Pract* 2014;17:419-24.
 18. Ekele BA, Audu LR, Oyetunji JA. Combined extrauterine and intrauterine pregnancy. *Trop J Obstet Gynaecol* 1999;16:61-2.
 19. Oyawoye S, Chander B, Pavlovic B, Hunter J, Gadir AA. Heterotopic pregnancy: Successful management with aspiration of cornual/interstitial gestational sac and instillation of small dose of methotrexate. *Fetal Diagn Ther* 2003;18:1-4.
 20. Porreco RP, Burke MS, Parker DW. Selective embryocide in the nonsurgical management of combined intrauterine-extrauterine pregnancy. *Obstet Gynecol* 1990;75:498-501.
 21. Wright A, Kowalczyk CL, Quintero R, Leach RE. Selective embryo reduction in a heterotopic pregnancy using potassium chloride injection resulting in a hematosalpinx. *Fertil Steril* 1996;66:1028-30.
 22. Adekanle DA, Ekomaye H, Olaitan PB. Heterotopic pregnancy with a live female infant: A case report. *Internet J Gynecol Obstet* 2007;7:1.
 23. El-Nafaty AU, Melah GS, Massa AA, Yahaya UR, Bukar M, Kizaya DD. Heterotopic pregnancy in a natural conception cycle. A case report. *Niger J Clin Pract* 2005;8:128-9.

