

Original Article

Evaluation and Comparison of Mineral Trioxide Aggregate and Biodentine in Primary Tooth Pulpotomy: Clinical and Radiographic Study

O Carti, F Oznurhan

Faculty of Dentistry,
Department of Pediatric
Dentistry, Cumhuriyet
University, Sivas, Turkey

Date of Acceptance:
02-Nov-2015

INTRODUCTION

Caries and traumatic injuries may cause irreversible damage in the pulp, which may lead to early tooth loss.^[1] One of the most important aims in pediatric dentistry is to maintain the primary dentition till eruption of permanent teeth in order to protect arc integrity and esthetics.^[2,3] Pulpotomy is a treatment procedure that may be performed in healthy radicular pulp tissue with healing potential after surgical amputation of the infected or affected coronal pulp.^[4] Pulpotomy therapy for the primary dentition can be classified according to various treatment objectives: devitalization (mummification, cauterization), preservation (minimal devitalization, noninductive), or regeneration (inductive, reparative).^[5] Various materials such as formocresol, ferric sulphate, glutaraldehyde, calcium hydroxide, zinc oxide eugenol, electrosurgery, and lasers have been used for the

ABSTRACT

Objectives: Pulpotomy is the common therapy for cariously exposed pulps in symptom-free primary molar teeth. For many years, researchers have searched for an ideal material that allows regeneration of the residual pulp. The purpose of this study was to evaluate the efficacy of mineral trioxide aggregate (MTA), Biodentine as a pulpotomy medicament in primary teeth, both clinically and radiographically.

Materials and Methods: A total of 25 children (50 human primary molar teeth) aged between 5 and 9 years were selected in this randomized clinical study. The patients were randomly assigned to receive the pulpotomy medicaments in either [Group 1]: MTA or [Group 2]: Biodentine. All pulpotomized teeth were restored with stainless steel crowns and evaluated clinically and radiologically at 1, 3, 6 and 12 months. Statistical analysis using Mann–Whitney U test and Fisher’s exact test, and chi-square test was performed to determine the significant differences between the groups. **Results:** Clinical and radiological success rates were 96 and 80% in Group 1 and 96 and 60% in Group 2, respectively. There were no significant differences between the groups ($P > 0.05$). The radiographic success rates decreased in the controls, but there were no significant differences.

Conclusion: Biodentine showed similar clinical and radiographic results as MTA in the 12-month evaluation and can be safely used as a pulpotomy medicament.

KEYWORDS: Biodentine, mineral trioxide aggregate, pulpotomy,

pulpotomy procedure. The ideal pulpotomy material is expected to be bactericidal, harmless to the pulp and the surrounding tissues, should promote the radicular pulp healing, not inhibit the physiological root resorption, and preserve radicular pulp without causing any clinical and radiological symptoms.^[1]

New innovations and researches in dentistry witnessed new materials that are bioinductive and regenerative, such as mineral trioxide aggregate (MTA).^[6] MTA is an antibacterial material with high bioactivity, biocompatible, and sealing abilities.^[6-9] On the basis of randomized

Address for correspondence: Dr. F Oznurhan,
Cumhuriyet University Faculty of Dentistry Department of
Pediatric Dentistry, Sivas, Turkey.
E-mail: fatihozn@hotmail.com

This is an open access article distributed under the terms of the Creative Commons Attribution-NonCommercial-ShareAlike 3.0 License, which allows others to remix, tweak, and build upon the work non-commercially, as long as the author is credited and the new creations are licensed under the identical terms.

For reprints contact: reprints@medknow.com

How to cite this article: Carti O, Oznurhan F. Evaluation and comparison of mineral trioxide aggregate and biodentine in primary tooth pulpotomy: Clinical and radiographic study. *Niger J Clin Pract* 2017;20:1604-9.

Access this article online

Quick Response Code:



Website: www.njcponline.com

DOI: 10.4103/1119-3077.196074

clinical studies in humans, MTA should be considered the new gold standard for pulp-capping treatment.^[7,10,11] However, the material has some shortcomings, such as difficulties in manipulation, long setting time, high cost, and tooth discoloration.^[9,12] Biodentine, which is a new calcium silicate-based material with active biosilicate technology, was developed to overcome the shortcomings of MTA. Biodentine can be used in crowns and roots where MTA is used because of its dentine-like mechanical properties.^[12-15] It has favorable effects on vital pulp cells and stimulates tertiary dentine formation.^[12-17] Biodentine is composed of powder and liquid. The powder part includes tricalcium silicate, dicalcium silicate (3 CaO SiO_2 and 2 CaO SiO_2), and calcium carbonate (CaCO_3). Zirconium dioxide (ZrO_2) is present as a contrast substance and calcium chloride present as liquid ($\text{CaCl}_2 \cdot 2\text{H}_2\text{O}$) to obtain rapid setting time and high strength.^[13,14]

Both MTA and Biodentine can be used as pulpotomy medicaments and a few studies have investigated the clinical and radiological effects of MTA and Biodentine. Therefore, the aim of this study was to evaluate and compare the clinical and radiological success of MTA and Biodentine pulpotomies in human primary teeth in a 12-month follow-up.

MATERIALS AND METHODS

Ethical approval for this study was obtained from the Cumhuriyet University Clinical Research Ethics Committee (2014-04/46) and the study was conducted at the Faculty of Dentistry, Department of Pediatric Dentistry, Cumhuriyet University. The clinical procedure, associated risks, and benefits were fully explained to the parents of the participants and written consent to participate was obtained before the procedure.

Sample size calculation

Sample size was performed under the assumption of studies that have resemble to our study.^[2,18,19] Accepting $\alpha = 0.05$, $\beta = 0.20$, $(1-\beta) = 0.80$ a total of 50 subjects are necessary (25 in MTA group and 25 in Biodentine group). The power of test was found 0.8063. The study was performed on 50 first and second primary carious molar teeth of 25 patients (12 female, 13 male) aged between 5 and 9 years (in the mind of starting root resorption age according to Logan and Kronfeld)^[20] assigned into two groups that included MTA and Biodentine, allocating 25 teeth in each group using simple lottery method.

Intra- and extraoral examinations of patients were performed before the treatment and their initial radiologic examinations were performed.

Patients who had no disease, such as congenital or rheumatic heart disease, leukemia, allergic reactions to substances, such as local anesthetics and latex, who did not require general anesthesia and sedation, and who had good individual and family cooperation were included in the study.

The teeth requiring pulpotomy were selected based on the inclusion criteria: deep cavity lesions that exposed vital pulp during the removal of caries; no history of spontaneous or nocturnal pain; absence of clinical symptoms such as swelling, fistula, tenderness of the percussion or palpation, pathologic mobility; those in which hemostasis was achieved within 5 minutes during clinical procedure; and the presence of two-thirds of the root length radiographically. No radiographic evidence of pulp degeneration, such as internal or external root resorption, furcal radiolucency, interradicular or periapical bone destruction, or pulp stones.

The 50 teeth that were considered according to the above-mentioned criteria were randomized into two study groups. In the first group, MTA pulpotomy was performed on 25 teeth and Biodentine pulpotomy was performed on the rest in the second group.

Treatment procedures

After performing topical anesthesia by lidocaine spray, regional anesthesia was administered by Maxicaine D-S (Maxicaine, Vem İlaç, Ankara, Turkey). All cavity lesions were removed and an access cavity was prepared under the isolation of rubber dam. A low-speed sterile round bur (No.12, No.18) and excavator were used for removing coronal pulp. Sterile cotton pellets moistened with sterile saline were placed over the pulp stumps and light pressure was applied for 5 minutes. All pulpotomy procedures were performed by same pediatric dentist.

MTA pulpotomy

After hemostasis, MTA was prepared according to the manufacturer's instructions by mixing MTA powder with distilled water in a 3:1 ratio and pulp stumps were covered. The MTA condensed lightly with a moistened cotton pellet. Resin-modified glass ionomer cement (Vitrebond 3M ESPE, Seefeld, Germany) was placed to fill the pulp chamber. The teeth were restored with stainless steel crowns (3M ESPE, Dental Products, St. Paul, MN, USA) and cemented with glass ionomer cement (Meron® Voco, Cuxhaven, Germany). Pulpotomy procedure for MTA group can be seen in [Figures 1a-f].

Biodentine pulpotomy

After hemostasis, Biodentine (Septodont, Saint Maur des Fosse's, France) was mixed according to the manufacturer's instructions and applied. First, the Biodentine capsule was struck gently on a solid surface

to mix the powder inside. It was then mixed with 5 droplets of liquid for 30 seconds using a triturator. The Biodentine mixture was condensed to the pulp stumps using an amalgam carrier and moistened cotton pellet. The cavity was filled with Biodentine and then restored by using a stainless steel crown and cemented with glass ionomer cement. Pulpotomy procedure for Biodentine group can be seen in [Figure 2a-f].

Evaluation of pulpotomy treatment and stainless steel crown (SSC) application

After applying SSC, the first radiographs were taken and the patients were recalled for clinical and radiographic evaluation after 1, 3, 6 and 12 months.^[21] Clinical and radiological evaluations were performed independently by two experienced pediatric dentists. The teeth were considered successful if they had no symptoms of palpation–percussion sensitivity, spontaneous pain, hot–cold sensitivity, presence of fistula–swelling, pathologic mobility, internal–external resorption, periapical/interradicular bone destruction, disintegration of the lamina dura, enlargement of the periodontal space, and radiological calcific metamorphosis.

Statistical analysis

Study data were entered in SPSS (22.0) and the Mann–Whitney U test, Fisher’s exact chi-square test were performed. A *P* value <0.05 was considered statistically significant.

RESULTS

In the present study, 25 children (female = 12, male = 13) and 50 teeth (1st primary molar = 27, 2nd primary molar = 23) were included. The mean age was 7.36 ± 1.25 years. Age, gender, and pulpotomy treatment types of the groups are presented in [Table 1].

Clinical evaluation

There was no statistically significant difference between clinical success rates in months 1, 3, 6 and 12 (*P* > 0.05) [Table 2]. The Kappa index obtained was 1.0 for clinical evaluation. In MTA group, one tooth was extracted due to fistula formation at month 12. In Biodentine group, one tooth was extracted due to fistula formation at month 12. Clinical failures are presented in [Table 3].

Radiological evaluation

The success rates are presented in [Table 4]. The Kappa index obtained was 0.87–1 for radiological evaluation. Radiological failures are presented in [Table 5].

In the radiological evaluation, the success rates were 100% in both groups at the end of the 1st month.

At the end of month 3, there were no statistically differences between the groups (*P* = 0.240). The

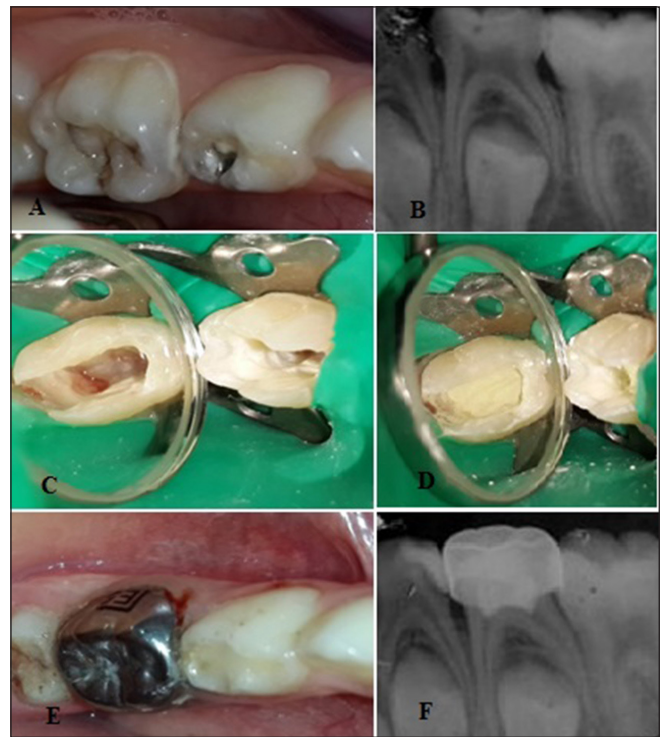


Figure 1: (a) Preoperative clinical appearance of 2nd mandibular primary molar tooth, (b) preoperative radiological appearance of 2nd mandibular primary molar tooth, (c) providing hemostasis, (d) condensation of mineral trioxide aggregate, (e) restoration with SCC, (f) first radiograph after treatment

Table 1: Age, gender, and the type of teeth of patients

	MTA n=25	BIODENTINE n=25	Total n=25
	n	n	N
Age	5	2	4
	6	3	5
	7	11	22
	8	2	4
	9	7	14
Gender	Male	13	26
	Female	12	24
Tooth	First primary molar	12	27
	Second primary molar	13	23

success rate was 92% (n = 23) in MTA group and 80% (n = 20) in the Biodentine group. A total of 4% (n = 1) disintegration of the lamina dura and 4% (n = 1) interradicular or periapical bone destruction were observed in the MTA group. And 4% (n = 1) external resorption, 8% (n = 2) interradicular or periapical bone destruction, and 4% (n = 1) disintegration of the lamina dura were observed in Biodentine group.

Table 2: Clinical evaluation of MTA and Biodentin follow-up from 1-12 months

Groups	MTA	BIODENTINE	p
Clinical Success	(n=25)	(n=25)	
1 month	100% (n=25)	100% (n=25)	-
3 month	100% (n=25)	100% (n=25)	-
6 month	100% (n=25)	100% (n=25)	-
12 month	96% (n=24)	96% (n=24)	0.327

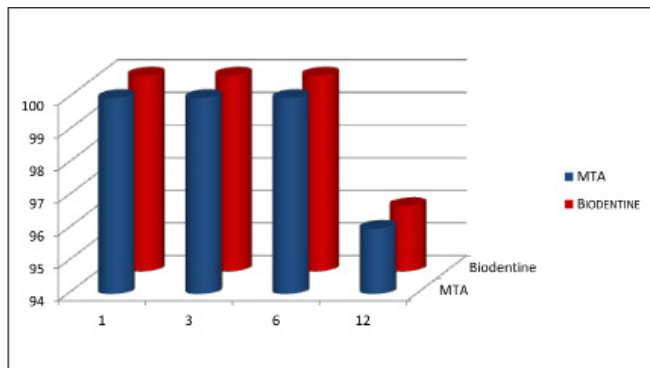


Table 4: Radiological evaluation of MTA and Biodentine follow-up from 1-12 months

Groups	MTA	BIODENTINE	p
Radiographic Success	(n=25)	(n=25)	
1 month	100% (n=25)	100% (n=25)	-
3 month	92% (n=23)	80% (n=20)	0.240
6 month	84% (n=21)	68% (n=17)	0.199
12 month	80% (n=20)	60% (n=15)	0.060

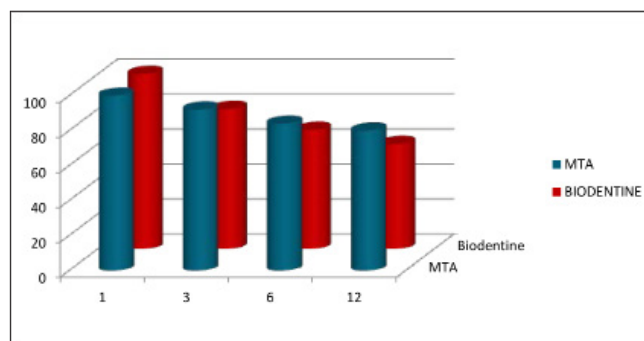


Table 3: Clinical Failures

Groups	Recall periods (months)				Total Failure Success (%)
	(Failure/success In Each Period)				
	1 m	3 m	6 m	12 m	
MTA (n=25)	0/25	0/25	0/25	41/24	1/24 (96%)
BIODENTINE (n=25)	0/25	0/25	0/25	41/24	1/24 (96%)

¹Palpation-percussion sensitivity, ²Spontaneous pain, ³Hot-cold sensitivity, ⁴Presence of fistula-swelling, ⁵Pathologic mobility

In the radiological evaluation at month 6, the success rates were 84% for MTA group and 68% for Biodentine group and there no statistically differences between the groups ($P = 0.199$). While 84% ($n = 21$) of cases were completely successful, cases had 4% ($n = 1$) external root resorption, 8% ($n = 2$) interradicular or periapical bone destruction, and 4% ($n = 1$) enlargement of periodontal space in MTA group.

The radiological evaluation showed 68% ($n = 17$) success rate in the Biodentine group at the end of 6th month. A total of 4% ($n = 1$) external root resorption, 4% ($n = 1$) external root resorption and bone destruction between the periapical and interroot regions, 16% ($n = 4$) interroot regions and interradicular or periapical bone destruction, 8% ($n = 2$) disintegration of the lamina dura were observed.

Table 5: Radiological Failures

Groups	Recall Periods (Months)				Total Failure Success (%)
	(Failure/Success In Each Period)				
	1 m	3 m	6 m	12 m	
MTA (n=25)	0/25	^{2,3} 2/23	^{1,2,4} 4/21	^{1,2} 5/20	5/20(80%)
BIODENTINE (n=25)	0/25	^{1,2,3} 5/20	^{1,2,3} 8/17	^{1,2,3} 10/15	10/15(60%)

¹Internal-external resorption, ²Periapical/interradicular bone destruction, ³Disintegration of the lamina dura, ⁴Enlargement of the periodontal space, ⁵Radiological calcific metamorphosis

The success rates were 80 and 60% for MTA and Biodentine groups at the end of 12th month, respectively, and there no statistically significant differences between the groups ($P = 0.060$). One tooth was extracted due to fistula formation; therefore, the total evaluation was performed on 24 teeth in MTA group. And 80% ($n = 20$) teeth were determined to be successful and 4% ($n = 1$) external root resorption and 12% ($n = 3$) interradicular or periapical bone destruction were observed. In Biodentine group, 4% ($n = 1$) external root resorption, 4% ($n = 1$) external root resorption and bone destruction between interradicular and periapical regions, 24% ($n = 6$) bone destruction between periapical and interradicular regions and 8% ($n = 2$) disintegration of the lamina dura continuity were observed.

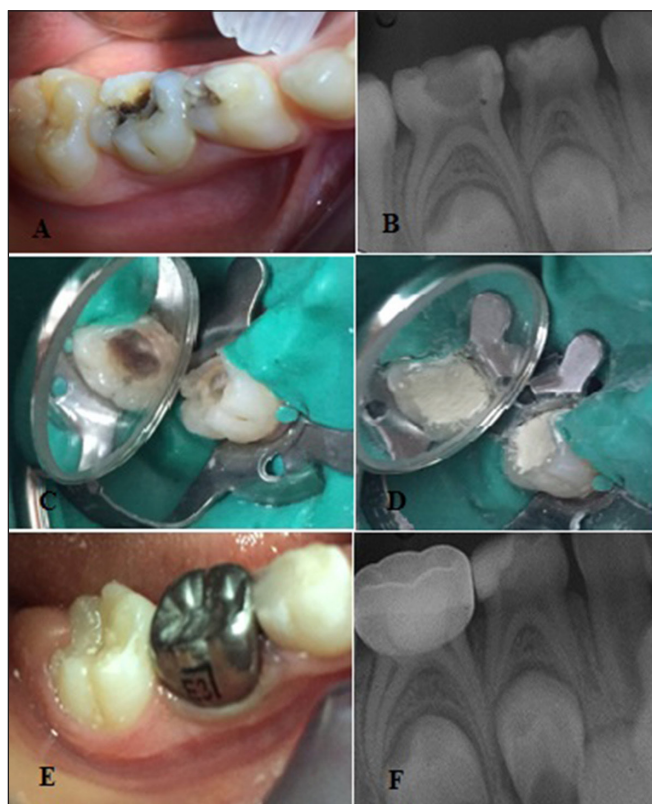


Figure 2: (a) Preoperative clinical appearance of 2nd mandibular primary molar tooth, (b) preoperative radiological appearance of 2nd mandibular primary molar tooth, (c) providing hemostasis, (d) condensation of Biodentine, (e) restoration with SCC, (f) first radiograph after treatment

DISCUSSION

Pulpotomy treatment is a routine treatment for symptom-free primary molar teeth that have been exposed with caries. During the pulpotomy procedure, infected or affected coronal pulp is amputated and the vital radicular pulp tissue surface is covered with a pulp-capping agent that promotes healing. Pulpotomy may be performed by nonpharmacotherapeutic approaches such as electrosurgery and laser treatment. Pharmacotherapeutic approaches may also be used, such as various medicaments and biological materials, including formocresol, ferric sulphate glutaraldehyde, calcium hydroxide, and MTA.^[15]

The latest material for this purpose was bioactive calcium-silicate-based material (Biodentine), which was recently introduced by Septodont and could conciliate high mechanical properties with excellent biocompatibility and has bioactive behavior.^[13] With enhanced properties, Biodentine can be used with the same clinical indications as MTA.^[16,17] There are few studies reported in the literature that compare the clinical and radiological efficiency of MTA and Biodentine in human primary teeth.

Nowicka *et al.*^[19] evaluated human pulp tissue responses when capped with Biodentine and MTA in the third

molar teeth and reported that there was no statistically significant difference between pulp responses.

Kusum *et al.*^[22] evaluated MTA, Biodentine and Propolis as pulpotomy medicaments in their study. They reported that success rates were 100% for MTA, 100% for Biodentine, and 84% for Propolis clinically, whereas they were 92% for MTA, 80% for Biodentine, and 72% for Propolis, radiologically. They indicated that although there was no difference between MTA and Biodentine, both of them were significantly different from Propolis; thus, Biodentine may be used safely as a pulpotomy material.

Niranjani *et al.*^[23] compared MTA, Biodentine and laser in their pulpotomy study and reported that the highest success rate was in MTA group; however, there was no statistically significant difference between the groups.

Cuadros-Fernandez *et al.*^[24] compared MTA and Biodentine and reported that the clinical success rate of Biodentine was 97% and MTA was 92%; radiological success rates were 95 and 97%, respectively. They also reported that there was no significant difference between the success rates of materials.

The results of this clinical study showed a clinical success rate of 96% and radiological success rate of 80% for the MTA group and a clinical success rate of 96% and radiological success rate of 60% for the Biodentine group. There were no statistically significant differences between the groups both clinically and radiologically ($P > 0.05$). The results were in agreement with Kusum, Niranjani, and Cuadros-Fernandez *et al.*^[22-24]

There were two clinical failures, one in MTA group and one in Biodentine group. The failures may be associated with misdiagnosis, iatrogenic errors, poorly adapted SSC, and leakage from these SSC.

There were 5 failures in MTA group and 10 failures in Biodentine group, but these cases were followed and they did not show clinical failure. The reasons for radiological failures should be histologically evaluated, which is one of the shortcomings of the study.

MTA showed higher success rates than Biodentine both clinically and radiologically. The higher success rates of MTA can be explained by it being a biocompatible material, its high-sealing ability and possessing a pH of approximately 11–12.

Both MTA and Biodentine are tricalcium silicate-based materials and they are biocompatible materials for pulp tissue.^[13,25,26] When compared to MTA, Biodentine has advantages, such as being easy-to-manipulate, high viscosity, short setting time, and superior mechanical properties; however, it is not as radioopaque as MTA

and required triturator and an additional time period for it.

CONCLUSION

According to the results of this study, both MTA and Biodentine can be used as pulpotomy agents, but more long-term studies with larger samples size are required.

Financial support and sponsorship

The study was supported by CUBAP.

Conflicts of interest

There are no conflicts of interest.

REFERENCES

- Fuks AB. Current concepts in vital primary pulp therapy. *Eur J Paediatr Dent* 2002;3:115-20.
- Godhi B, Sood PB, Sharma A. Effects of mineral trioxide aggregate and formocresol on vital pulp after pulpotomy of primary molars: An *in vivo* study. *Contemp Clin Dent* 2011;2:296-1.
- Caicedo R, Abbott PV, Alongi DJ, Alarcon MY. Clinical, radiographic and histological analysis of the effects of mineral trioxide aggregate used in direct pulp capping and pulpotomies of primary teeth. *Aust Dent J* 2006;51:297-5.
- Bergenholtz G. Advances since the paper by Zander and Glass (1949) on the pursuit of healing methods for pulpal exposures: Historical perspectives. *Oral Surg Oral Med Oral Pathol Oral Radiol Endod* 2005;100:S102-8.
- Ranly DM, Garcia-Godoy F. Reviewing pulp treatment for primary teeth. *J Am Dent Assoc* 1991;122:83-5.
- Iwamoto CE, Adachi E, Pameijer CH, Barnes D, Romberg EE, Jeffries S. Clinical and histological evaluation of white ProRoot MTA in direct pulp capping. *Am J Dent* 2006;19:85-90.
- Nair PN, Duncan HF, Pitt Ford TR, Luder HU. Histological, ultrastructural and quantitative investigations on the response of healthy human pulps to experimental capping with mineral trioxide aggregate: A randomized controlled trial. *Int Endod J* 2008;41:128-50.
- Eskandarizadeh A, Shahpasandzadeh MH, Shahpasandzadeh M, Torabi M, Parirokh M. A comparative study on dental pulp response to calcium hydroxide, white and grey mineral trioxide aggregate as pulp capping agents. *J Conserv Dent* 2011;14:351-5.
- Parirokh M, Torabinejad M. Mineral trioxide aggregate: A comprehensive literature review-Part I: Chemical, physical, and antibacterial properties. *J Endod* 2010;36:16-27.
- Paranjpe A, Smoot T, Zhang H, Johnson JD. Direct contact with mineral trioxide aggregate activates and differentiates human dental pulp cells. *J Endod* 2011;37:1691-5.
- Paranjpe A, Zhang H, Johnson JD. Effects of mineral trioxide aggregate on human dental pulp cells after pulp-capping procedures. *J Endod* 2010;36:1042-7.
- Dammaschke T, Gerth HU, Zuchner H, Schafer E. Chemical and physical surface and bulk material characterization of white ProRoot MTA and two Portland cements. *Dent Mater* 2005;21:731-8.
- Laurent P, Camps J, About I. Biodentine (TM) induces TGF-beta1 release from human pulp cells and early dental pulp mineralization. *Int Endod J* 2012;45:439-48.
- Koubi G, Colon P, Franquin JC, Hartmann A, Richard G, Faure MO. Clinical evaluation of the performance and safety of a new dentine substitute, Biodentine, in the restoration of posterior teeth - A prospective study. *Clin Oral Investig* 2013;17:243-9.
- Gupta G, Rana V, Srivastava N, Chandna P. Laser pulpotomy-an effective alternative to conventional techniques: A 12 months clinicoradiographic study. *Int J Clin Pediatr Dent* 2015;8:18-21.
- Malkondu O, Karapinar-Kazandag M, Kazazoglu E. A review on biodentine, a contemporary dentine replacement and repair material. *Biomed Res Int* 2014;2014:160951.
- Arora V, Nikhil V, Sharma N, Arora P. Bioactive dentin replacement. *IOSR J Dent Med Sci* 2013;12:51-7.
- De Rossi A, Silva LA, Gatón-Hernandez P, Sousa-Neto MD, Nelson-Filho P, Silva RA. Comparison of pulpal responses to pulpotomy and pulp capping with biodentine and mineral trioxide aggregate in dogs. *J Endod* 2014;40:1362-9.
- Nowicka A, Lipski M, Parafiniuk M, Sporniak-Tutak K, Lichota D, Kosierkiewicz A. Response of human dental pulp capped with biodentine and mineral trioxide aggregate. *J Endod* 2013;39:743-7.
- Logan WH, Kronfeld R. Development of the human jaws and surrounding structures from birth to the age of fifteen years. *J Am Dent Assoc* (1922) 1933;20:379-428.
- Srinivasan V, Waterhouse P, Whitworth J. Mineral trioxide aggregate in paediatric dentistry. *Int J Paediatr Dent* 2009;19:34-47.
- Kusum B, Rakesh K, Richa K. Clinical and radiographical evaluation of mineral trioxide aggregate, biodentine and propolis as pulpotomy medicaments in primary teeth. *Restor Dent Endod* 2015;40:276-85.
- Niranjani K, Prasad MG, Vasa AA, Divya G, Thakur MS, Saujanya K. Clinical evaluation of success of primary teeth pulpotomy using mineral trioxide aggregate((r)), laser and Biodentine(TM)- an *in vivo* study. *J Clin Diagn Res* 2015;9:ZC35-7.
- Cuadros-Fernandez C, Lorente Rodriguez AI, Saez-Martinez S, Garcia-Binimelis J, About I, Mercade M. Short-term treatment outcome of pulpotomies in primary molars using mineral trioxide aggregate and Biodentine: A randomized clinical trial. *Clin Oral Investig* 2015, Nov 18. Epub ahead of print.
- Agamy HA, Bakry NS, Mounir MM, Avery DR. Comparison of mineral trioxide aggregate and formocresol as pulp-capping agents in pulpotomized primary teeth. *Pediatr Dent* 2004;26:302-9.
- Zanini M, Sautier JM, Berdal A, Simon S. Biodentine induces immortalized murine pulp cell differentiation into odontoblast-like cells and stimulates biomineralization. *J Endod* 2012;38:1220-6.