

Case Report

Optic Disc Coloboma in Two Nigerian Siblings: Case Report and Review of Literature

YO Babalola^{1,2}, OO Olawoye^{1,2}, PO Idam¹

¹Department of Ophthalmology, University College Hospital, ²Department of Ophthalmology, College of Medicine, University of Ibadan, Ibadan, Nigeria

ABSTRACT

We report two cases of bilateral asymmetric optic disc coloboma (ODC) in siblings. The index patient is a 9-year-old Nigerian girl with severe cognitive deficit who presented with a poor vision of 3 years' duration. She had a history of childhood febrile convulsions and delayed developmental milestones. Her visual acuity could not be assessed because she had a cognitive deficit and expressive aphasia. Ocular examination revealed a very large excavated right optic disc with only a strip of remnant neuro-retinal rim superiorly, and a smaller left optic disc with inferior disc excavation, superior wedge of the pink neuro-retinal rim as well as a temporal optic disc pit. No systemic features of syndromes associated with ODCs and intellectual disability were present in both patients. The younger sibling an 8-year-old girl later presented to the eye clinic with a 5-month history of poor vision in the left eye. Ocular examination revealed visual acuity of 6/6 in the right eye and counting fingers in the left eye. Dilated binocular indirect ophthalmoscopy revealed a right large excavated colobomatous disc and a left small disc with infero-temporal disc coloboma.

KEYWORDS: *Optic disc coloboma, cognitive deficit, Nigeria*

Date of Acceptance:
09-Jun-2017

INTRODUCTION

Optic disc coloboma (ODC) is a congenital anomaly characterized by whitish bowl-shaped excavation of the optic disc. It may be unilateral or bilateral and may occur in association with other colobomas or congenital disc anomalies or as part of a wider systemic syndrome.^[1] ODC like other ocular colobomas results from incomplete closure of the embryonic fissure during the 5th–7th week of intrauterine life.^[2] It most commonly occurs sporadically; an autosomal dominant variant has however been described in association with mutation in the PAX6 gene.^[1]

ODC may be associated with retarded development in congenital conditions such as the CHARGE and Goldenhar syndromes and chromosomal anomalies such as Edwards and Patau syndromes.^[1] We report two cases of siblings; a 9-year-old girl with bilateral ODC, left optic disc pit (ODP) and acquired intellectual disability and the sister an 8-year-old girl with bilateral ODC (R > L). ODC is rare in Nigeria. To the best of our knowledge,

this is the first reported case of a combined bilateral ODC and ODP occurring in a Nigerian child who has a sibling with a similar congenital optic disc abnormality.

CASE REPORTS

Case 1

A 9-year-old girl was referred from a Catholic Mission Hospital on suspicion of having juvenile open angle glaucoma. She presented with a 3-year history of poor vision in both eyes with associated itching and recurrent catarrh. Patients' mother gave a history of her holding books very close to her face when reading. Delivery was by spontaneous vertex delivery; the pregnancy antenatal and neonatal period was uneventful. Her mother gave a positive history of delay in crying after delivery which may suggest birth asphyxia. There was also a history of neonatal jaundice which was managed with phototherapy

Address for correspondence: Dr. OO Olawoye,
Department of Ophthalmology University College Hospital,
Ibadan, Nigeria.
E-mail: solaolawoye@yahoo.com

Access this article online

Quick Response Code:



Website: www.njcponline.com

DOI: 10.4103/njcp.njcp_412_16

This is an open access article distributed under the terms of the Creative Commons Attribution-NonCommercial-ShareAlike 3.0 License, which allows others to remix, tweak, and build upon the work non-commercially, as long as the author is credited and the new creations are licensed under the identical terms.

For reprints contact: reprints@medknow.com

How to cite this article: Babalola YO, Olawoye OO, Idam PO. Optic disc coloboma in two Nigerian siblings: Case report and review of literature. *Niger J Clin Pract* 2017;20:1505-9.

on an outpatient basis in the delivery hospital. Patient acquired appropriate developmental milestones for age in the first 16 months of life.

At 17 months of age, she was admitted for a duration of 2 months for a severe febrile illness, and multiple episodes of convulsions. She lost consciousness for a few days during this illness. Mother could not ascertain the exact illness she was treated for but she was given intravenous fluid and intravenous drugs which in Nigeria, may be suggestive of meningitis or cerebral malaria.

She subsequently lost previously acquired developmental milestones which included a social smile, sitting, walking and speech appropriate for age. She only regained her ability to walk unaided after 6 months of intensive physiotherapy.

Patient has had expressive aphasia since the febrile illness. Her speech is rarely spontaneous nor coherent. She lacks adequate social skills expected for age. This has had an effect on her education, and she is presently in nursery class usually meant for 2-year-olds though she is 9 years old. Our patient at the age of 9 years is yet to achieve nighttime urinary continence and requires assistance to bath her body. Her academic performance is poor, and she is unable to write. She can carry out minor errands but performs far below her age. Parents, however, report that she is safety conscious. There is no history suggestive of any other systemic diseases. She is otherwise healthy. There is no family history of blinding eye disease, nor similar developmental abnormalities in any of her other two siblings.

On ophthalmic examination, the visual acuity could not be objectively assessed as the patient was nonresponsive and

did not obey instructions. She, however, moved around easily. She had central, steady gaze, and maintained fixation in both eyes with no nystagmus. The anterior segments were essentially normal. Intraocular pressures measured by applanation tonometry was 12 mmHg in each eye. Dilated binocular indirect ophthalmoscopy of the right fundus revealed a large optic disc with an inferior whitish bowl-shaped excavation. There was a small neuroretinal rim seen only superiorly with marked peripapillary degeneration [Figure 1]. Fundoscopy in the left eye revealed an enlarged optic disc smaller than the right with inferior excavation and a wedge of pink neuroretinal rim superiorly. At the temporal aspect of the disc was a grayish coexisting ODP [Figure 2]. The macula appeared normal, and both retinæ were flat with no evidence of retinal nor macula detachment.

An assessment of bilateral ODC with a left optic pit was made.

Fundoscopy was done for both parents, and each had normal fundi (pink discs, CDR of 0.3–0.4, normal macula and vessels). Both parents had a visual acuity of 6/6 in each. The parents were told to bring the other three siblings of the index patient for ocular examination and screening.

A cycloplegic refraction was done as she was not cooperative for subjective refraction due to expressive aphasia and diminished mental status. Refractive state of her eyes was found to be +1.25 DS in both eyes, and appropriate spectacles were prescribed though the visual outcome could not be assessed as the patient was aphasic and nonverbal.

Systemic examination of the chest and cardiac systems were essentially normal. Hearing tests and renal tests

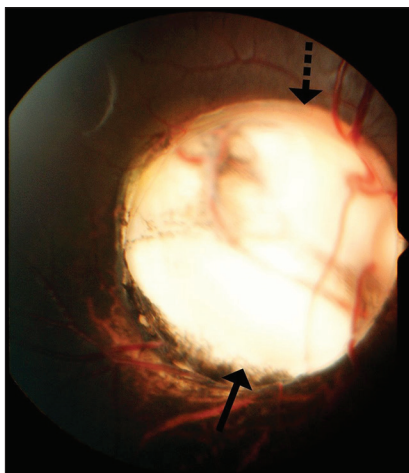


Figure 1: Fundus picture of the right optic disc of index patient showing an enlarged optic disc with a whitish bowl-shaped excavation. A strip of remnant neuro-retinal rim (broken arrow) is seen superiorly, with complete absence of neuro-retinal rim and peripapillary degeneration inferiorly (solid arrow)

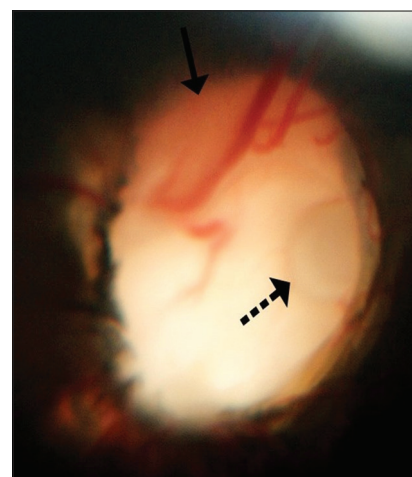


Figure 2: Fundus picture of the left eye of index patient showing a smaller disc with inferior whitish excavation and a superior wedge of pink neuro-retinal rim. Located at the temporal aspect of the disc is an optic disc pit covered by a greyish membrane (broken arrows)

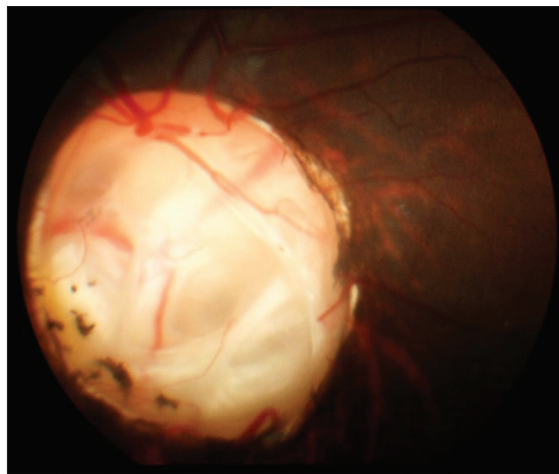


Figure 3: Right optic disc of sibling showing deep excavation with only a strip of neuro-retinal rim superiorly

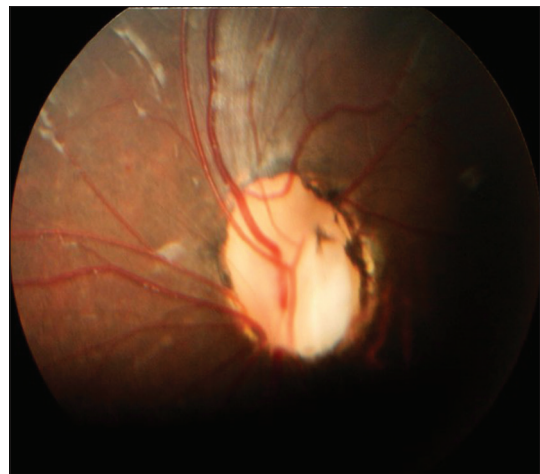


Figure 4: The left optic disc of sibling showing a colobomatous optic nerve

done were also normal. The patient was referred to the pediatric neurologist for neurological and systemic assessment which was found to be normal. An assessment of severe cognitive disability was made.

The patient was referred to see the child psychiatrist for intelligence quotient (IQ) assessment. During the psychiatric review, she was calm but could not comment nor answer any questions thereby making it difficult to carry out the IQ assessment. A diagnosis of intellectual disability was made. She was subsequently recommended for special education.

Case 2

The index patient's sibling is an 8-year-old girl who presented to the eye clinic with a 5-month history of poor vision in the left eye. She was apparently well and enjoying good vision in both eyes until 5 months before presentation when she complained of difficulty with seeing the blackboard from a distance. Her father noticed she turned her head toward the left to view objects better on that side. There was no history of spectacle use.

The pregnancy, birth, and neonatal period were uneventful. She was a product of spontaneous vertex delivery at term.

On examination, the visual acuity was 6/6 and Counting fingers, respectively, in the right and left eyes. There was a 15° esotropia on the left eye. The extraocular movements were full. Anterior segment examination was normal with no pupillary abnormality. The intraocular pressures were 14 mmHg in each eye. Dilated binocular indirect ophthalmoscopy in the right eye revealed large excavated discs with intact superonasal rims, surrounding pigmentation around the disc margins and a large hypopigmented defect in the inferonasal retina in the right eye. The left eye revealed a smaller disc with

inferotemporal coloboma and peripapillary pigmentary changes. The retina was flat and the macula normal. She did not have any systemic abnormalities and was well oriented in time person and place with no cognitive disability. A diagnosis of bilateral ODCs was made with left strabismic amblyopia.

An assessment of a right ODC [Figure 3] and a left inferior disc coloboma with strabismic amblyopia was made [Figure 4].

Written and verbal consents were obtained from the father of the two patients. In reporting this case we conformed to the tenets of the declaration of Helsinki.

DISCUSSION

ODC is a rare congenital disorder with a prevalence of about 0.14% in the general population.^[3] Fifty percent of patients with ODC have bilateral disease.^[4] It results from incomplete closure of the embryonic fissure, and often the defect is filled with varying amounts of glial tissue. They may occur as an isolated defect or in association with other colobomas such as retinochoroidal, lens, or iris colobomas.^[1] Neither of our two patients had other colobomas nor any systemic associations suggesting they may have the isolated defect. The parents of our patients did not have any optic disc abnormality on funduscopy; therefore, this is unlikely to be of autosomal dominant inheritance. It is highly plausible, however that our patients may have an autosomal recessive or X-linked inheritance. Most cases of ODC are sporadic; less frequently an autosomal dominant inheritance may occur. Rarely, inheritance is autosomal recessive or X-linked inheritance.^[5] It is important that all patients with ODC have chromosomal analysis though this was not possible in our patients due to nonavailability of facilities. ODC may either be unilateral or bilateral. Our two patients had

bilateral disease although asymmetrical. This has also been reported by Savell *et al.*^[5]

ODC may occur as a component of systemic syndromes^[6] such as chromosomal disorders such as Patau and Edward syndromes, the CHARGE syndrome (coloboma, heart defects, nasal choanal atresia, growth/developmental retardation, genitourinary anomalies, and ear defects/hearing loss). Neurological disorders such as Dandy-Walker cyst, agenesis of the corpus callosum, Goldenhar syndrome and the renal-coloboma syndrome are associated with the PAX6 gene mutation.^[7] The two patients we reported here did not have any clinical features of any of these syndromes/associations except for the developmental retardation in the index patient. This may have been acquired and related to the childhood febrile convulsions. We, however, cannot completely rule out the possibility of a neurological disorder as an association of ODC; although, our patients did not have syndromic features such as facial/skeletal abnormalities, and hearing impairment.

Individuals with ODCs have variable visual acuities as well as superior visual field defects which may be mistaken for normal tension glaucoma.^[1] The absence of nystagmus and strabismus as well as the presence of good navigational vision in our index patient may suggest fairly good vision bilaterally. It is, however, difficult to ascertain her visual acuity objectively because of the severe cognitive disability. Her younger sister, however, had poor vision in the left eye. This may be due to strabismic amblyopia since she did not have any specific organic defect in the left eye. ODC has been reportedly associated with strabismus.^[8] Other associations of ODC are nonrhegmatogenous retinal detachment, nystagmus, and posterior lenticonus. None of these associations was present in either of our patients. Patients with ODC should be followed up for life because of the risk of retinal detachment which may occur when there are breaks in the membrane that overlies the coloboma and liquefied vitreous leaks into the subretinal space. Visual prognosis is dependent on the involvement of the papillomacular bundle and the severity of complications that may be associated with ODC. Poor vision may result from choroidal neovascularization and retinal detachment, especially in the presence of retinal colobomas.^[5]

Our index patient also had ODP in the left eye. Reports have shown that ODP may be associated with ODC and it may also occur in patients with large optic discs.^[5] ODPs may be congenital or acquired. Acquired ODPs are usually associated with glaucoma while the congenital type is often unilateral but may be bilateral in 15% of patients. Studies have shown that large temporal ODPs such as seen in our index patient are associated with a

higher risk of developing serous macular elevations with detachments and subretinal fluid in 25%–75% of patients resulting in adjacent changes in the retinal pigment epithelium, especially in the third and fourth decades of life. Congenital ODP may have systemic associations such as Aicardi and Alagille syndrome.^[9]

ODP has an incidence of 1 in 11000 in the general population.^[9] It occurs equally in men and women. Histologically, optic pit appears like a dysplastic retina herniated posteriorly into a defect in the lamina cribrosa.^[10] Many patients, however, remain asymptomatic through life. The most common defect seen in ODP is arcuate scotoma, but any visual field defect may occur due to the displacement of the nerve fibers.^[11] Unfortunately, we could not perform a visual field test on our patient because of the severe cognitive defects.

Due to the risk of retinal detachment associated with ODC/pit, our patient will benefit from regular follow-up and dilated binocular indirect ophthalmoscopy to detect these complications as early interventions have been associated with good outcome.^[6]

There is also need for close neurologic/neuropsychiatric follow up so as to maximize the learning potential of our index patient. Psychosocial support for the parents/caregivers is also paramount.

ODC is rare in Nigeria. Notwithstanding the rare nature of the disease, a high index of suspicion as well as regular school screening exercises may help identify cases. Patients may benefit from optimization of their vision or identification and management of serious comorbidities including cardiac/renal anomalies if the early and prompt diagnosis is made. It is also important to evaluate ODC patients for other ocular/systemic disorders, as a multidisciplinary management may be necessary.

ODC may be misdiagnosed as advanced glaucoma as in the case of our index patient. In contrast to glaucoma, the optic disc in ODC is typically very large, whitish, with excavated optic nerve head inferiorly, absent inferior rim and thin rim tissue superiorly. We have reported this case to emphasize the importance of dilated binocular indirect ophthalmoscopy, and the critical assessment of the optic disc to differentiate ODCs from glaucomatous optic neuropathy. This case also highlights the importance of a multidisciplinary approach to the management of patients with ODC as it may be syndromic. Our first patient benefitted from both pediatric and psychiatric review.

Financial support and sponsorship

Nil.

Conflicts of interest

There are no conflicts of interest.

REFERENCES

1. Azuma N, Yamaguchi Y, Handa H, Tadokoro K, Asaka A, Kawase E, *et al.* Mutations of the PAX6 gene detected in patients with a variety of optic-nerve malformations. *Am J Hum Genet* 2003;72:1565-70.
2. Onwochei BC, Simon JW, Bateman JB, Couture KC, Mir E. Ocular colobomata. *Surv Ophthalmol* 2000;45:175-94.
3. Amador-Patarroyo MJ, Pérez-Rueda MA, Tellez CH. Congenital anomalies of the optic nerve. *Saudi J Ophthalmol* 2015;29:32-8.
4. Biedner B, Klemperer I, Dagan M, Yassur Y. Optic disc coloboma associated with macular hole and retinal detachment. *Ann Ophthalmol* 1993;25:350-2.
5. Savell J, Cook JR. Optic nerve colobomas of autosomal-dominant heredity. *Arch Ophthalmol* 1976;94:395-400.
6. Brodsky MC. Congenital anomalies of the optic disc. In: Miller NR, Newman NG, editors. *Walsh & Hoyt's Clinical Neuro-Ophthalmology*. 5th ed., Ch. 18. Baltimore, MO: Williams & Wilkins; 1998. p. 775-823.
7. Dureau P, Attie-Bitach T, Salomon R, Bettembourg O, Amiel J, Uteza Y, *et al.* Renal coloboma syndrome. *Ophthalmology* 2001;108:1912-6.
8. Jacobs M, Taylor D. The systemic and genetic significance of congenital optic disc anomalies. *Eye (Lond)* 1991;5(Pt 4):470-5.
9. Hsu CL, Layton CJ. Familial disorders of the optic disc: Presentation of a mother and daughter and review of the literature. *Case Rep Ophthalmol* 2015;6:251-9.
10. Shah SD, Yee KK, Fortun JA, Albin T. Optic disc pit maculopathy: A review and update on imaging and treatment. *Int Ophthalmol Clin* 2014;54:61-78.
11. Brown GC, Shields JA, Goldberg RE. Congenital pits of the optic nerve head. II. Clinical studies in humans. *Ophthalmology* 1980;87:51-65.

