

Case Report

Torsion of the Spermatic Cord: An Exemplary Early Presentation

OY Oluyemi

Department of Surgery, Ben Carson (SNR) School of Medicine/Babcock University Teaching Hospital, Ilisan Remo, Ogun State, Nigeria

ABSTRACT

Torsion of the spermatic cord may lead to loss of the testis when presentation is delayed. In our environment, a high premium is placed on the male child and his ability to procreate. Hence, torsion of the spermatic cord is a true surgical emergency. Here, we report a case of torsion of the spermatic cord in a 19-year-old student that exemplifies early presentation and short presentation-detorsion time. Immediately after the operation, the clinical information in the patient's case file was summarized. A literature search was conducted on the subject matter, and the findings were compared with those of the present patient. The determinants of outcome include presentation time and the time between presentation and operation. Unfortunately, in many series, late presentation is still the norm. In the index patient, the presentation time was very short. In our environment, patients with torsion of the spermatic cord can present early and be operated promptly if we can provide public health education, mobile phones, commercial taxis, and good road networks.

KEYWORDS: *Spermatic cord, testis, torsion*

Date of Acceptance:
25-Sep-2016

CASE REPORT

The patient was a 19-year-old male 200-level student of Mass Communication at Babcock University, Ilisan-Remo in Ogun State, Nigeria. He was living within the university campus. He presented with sudden onset of pain in the right hemiscrotum of 30-min duration. The pain was very severe, worsening, nonradiating, and associated with nausea and vomiting.

There was no antecedent trauma, and no associated fever. There were no urinary symptoms. There was no past history of intermittent scrotal pain. Three days prior to the onset of scrotal pain, he presented with features suggestive of malaria fever and upper respiratory tract infection. He was commenced on antimalarial and analgesic medications.

On examination, he appeared acutely ill, in severe pain, afebrile, not pale, and well hydrated. Temperature was 36.7°C, respiratory rate was 24/min, pulse rate was 80/min, and blood pressure was 140/90 mmHg.

The phallus was circumcised, external urethral meatus was patent, and there was no urethral discharge. There was no palpable urethral induration. The right

hemiscrotum was swollen, and the cremasteric reflex was absent; there was a palpable tender firm-to-hard mass above the testis, which was high-riding, tender, and firm. Prehn's sign was absent. On the left side, the cremasteric reflex was present, left testis had a horizontal lie, and was soft and nontender.

The findings on digital rectal examination were within normal limits. Doppler ultrasound and radionuclide scintigraphy machines were not available in our Accident and Emergency Department. A clinical diagnosis of torsion of the right spermatic cord was made. There was no attempt at manual detorsion. The patient was counselled for emergency scrotal exploration and bilateral orchidopexy.

Emergency laboratory evaluation were: hemoglobin = 14.9g/dl, white cell count = 6100/cmm, and platelets count = 228×10^3 /cmm. Urinalysis was normal.

Address for correspondence: Dr. OY Oluyemi,
Department of Surgery, Ben Carson (SNR) School of Medicine/
Babcock University Teaching Hospital, Ilisan Remo,
Ogun State, Nigeria.
E-mail: oluyemioy@gmail.com

Access this article online

Quick Response Code:



Website: www.njcponline.com

DOI: 10.4103/njcp.njcp_358_16

This is an open access article distributed under the terms of the Creative Commons Attribution-Non Commercial-Share Alike 3.0 License, which allows others to remix, tweak, and build upon the work non-commercially, as long as the author is credited and the new creations are licensed under the identical terms.

For reprints contact: reprints@medknow.com

How to cite this article: Oluyemi OY. Torsion of the spermatic cord: An exemplary early presentation. *Niger J Clin Pract* 2017;20:1206-9.

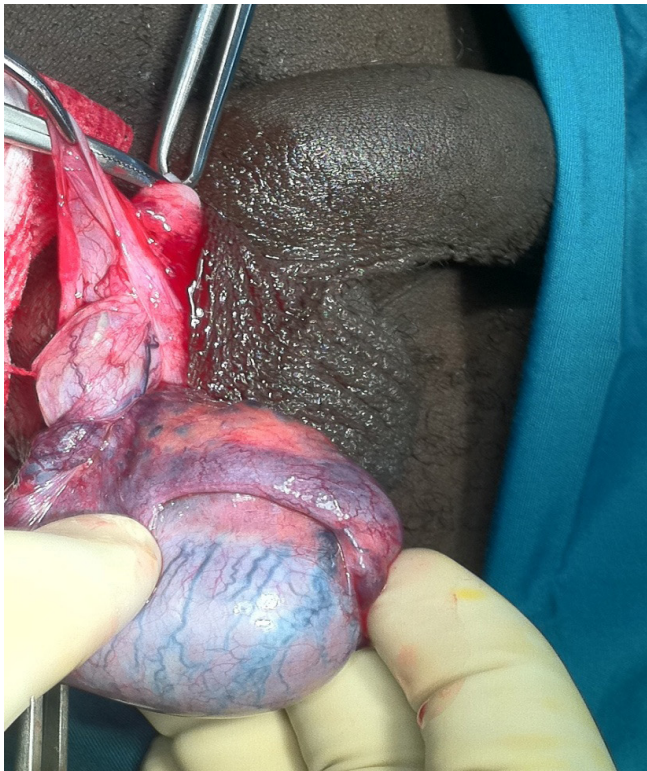

Figure 1: Bluish torted right testis

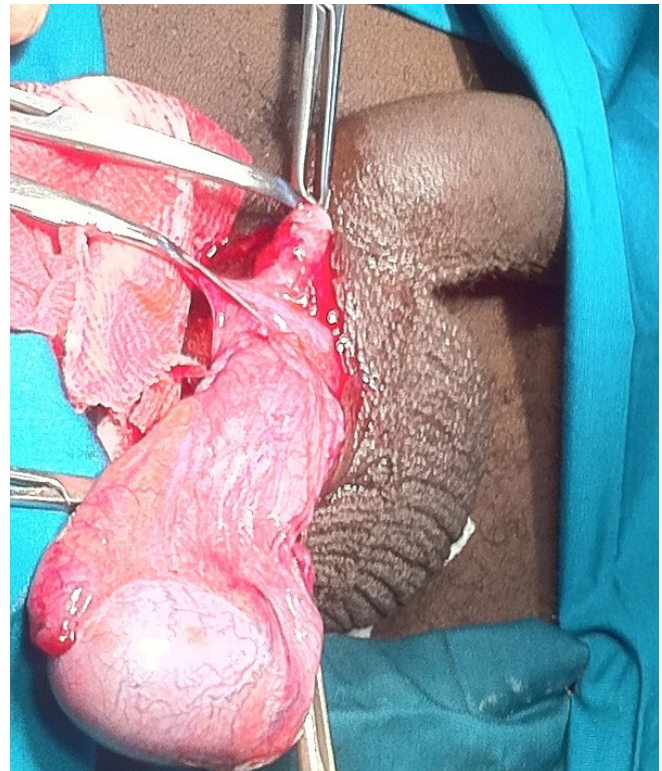


Figure 2: Pink detorted right testis

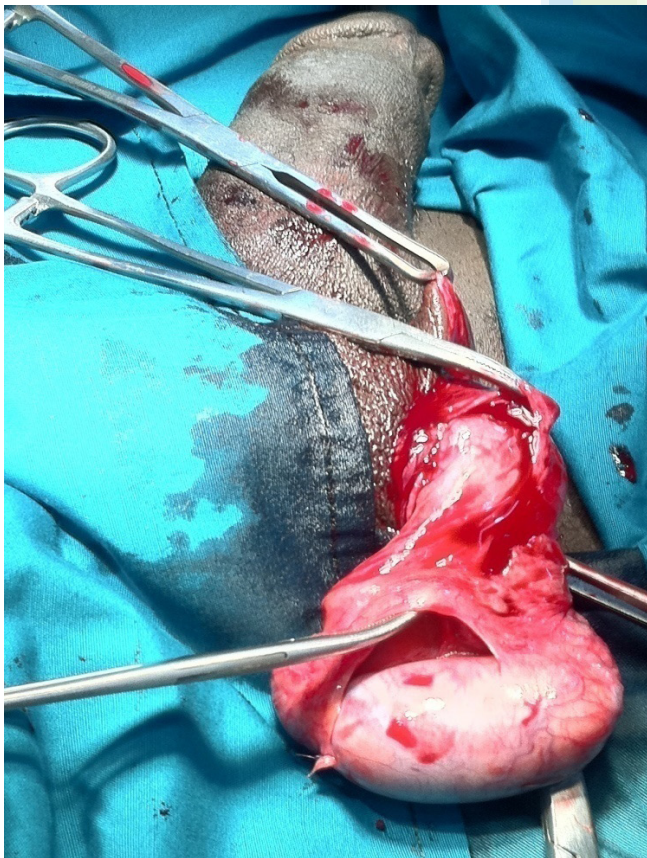


Figure 3: Left testis is a mirror image of the right

He underwent an emergency scrotal exploration and bilateral orchidopexy under local anesthesia. Operative findings in the right hemiscrotum were edematous bluish testis, which became pink on detorsion [Figure 1] and [Figure 2], 360° torsion medially, high investing tunica vaginalis, horizontally lying testis, and long partially detached mesorchium.

The left testis had high investing tunica vaginalis, horizontal lie, and long partially detached mesorchium [Figure 3]. The postoperative period was uneventful.

DISCUSSION

Torsion of the spermatic cord usually occurs in children, teenagers, and postpubertal males, and can occur at any age.^[1,2] The prevalence of torsion was reported as 8.6 per 100,000 males aged 10 to 19 per year in the United States.^[3]

Anomalies of the tunica and processus vaginalis predispose to the torsion of the spermatic cord. The bell-clapper deformity was identified in 12% of males in an autopsy series.^[4] This anatomic variant is due to partial or complete failure of fusion of the tunica vaginalis along the epididymis, resulting in incomplete attachment of the testis/epididymis to the scrotum or to an abnormally wide attachment (mesorchium) of the testis to epididymis. The latter scenario may cause a true torsion of the testis, whereby the testis torses on its mesorchium.^[5]

The exact precipitating factor in each patient may be difficult to ascertain, however, may include cold temperature, sexual foreplay, sudden movement, or trauma. Undescended testes are at a higher risk of torsion. Recurrent torsion of the spermatic cord may occur following orchidopexy as a result of failure of suture material used for the fixation.^[6,7]

Torsion of the spermatic cord may be extravaginal or intravaginal. Extravaginal torsion of the spermatic cord is common before birth and in the perinatal period before established fixation between the tunica vaginalis and dartos within the scrotum. Extravaginal torsion of the spermatic cord may lead to loss of the testis and, depending on the timing, may present as a nonpalpable “vanishing” testis in a child evaluated for cryptorchidism or as an abnormal scrotal testis on the first postnatal examination.

Intravaginal torsion of the spermatic cord is common among older male children, teenagers, and postpubertal boys. In this case, the spermatic cord carrying the testis such as the clapper of a bell, which twists on itself within the tunica vaginalis. Usually torsion of the spermatic cord occurs in the medial direction, towards the midline; however, it can also occur in the lateral direction in a third of cases.^[8]

Torsion of the spermatic cord will cause a reduction or cessation of blood flow to the testicular parenchyma. Irreversible ischemia sets in within 4–6 hours if there is total compromise of blood supply.^[9]

The tight Sertoli-cell junctions provide the testis with a barrier that prevents the immune system from coming in contact with the post-meiotic germ cells. In torsion, the barrier can be violated, resulting in an immune response to sperm, with production of antisperm antibodies (ASABs), which includes sperm agglutinating, sperm immobilizing, or spermotoxic antibodies. This explains the subtle abnormalities of semen quality that occurs after torsion, and it seems to show a positive correlation with shorter duration of torsion and reduced atrophy.^[10]

The determinants of outcome are whether it is extravaginal or intravaginal, degree of torsion, presentation time and time between presentation, and operation, as well as bilaterality. The presentation time is very critical in determining the outcome of management. Unfortunately in many instances, the late presentation is the norm.

In Alabama, Cummings *et al.* reported a mean presentation time of 6.5 h among 17 patients who were 8–20 years old and 11 h among 27 patients who were 21–34 years old. The mean time between presentation

and operation was 4.8 hours among the younger age group and 7.1 h among the older age group.^[11]

In New York, Barada *et al.* reported a mean presentation time of 20 h among patients less than 18 years old, and 4 h among those who are older than 18 years of age. At surgery, 44% of the former group required orchidectomy as against 8% of the latter group.^[12]

In the case being reported the patient presented at our Accident and Emergency Department; it is exemplary that the presentation time was 30 min. He was reviewed by the Consultant Urological Surgeon within 20 min. He was received in the main theatre within 58 min following presentation. The interval between presentation and detorsion was 1 h and 52 min. The entire duration, from the onset of pain to end of the surgery, was 3 h and 27 min.

There are lessons to be learnt from this exemplary early presentation, examining the circumstances that made him present within 30 min of the onset of scrotal pain. He had been on treatment for a febrile illness 3 days prior to the onset of the scrotal pain and the attending medical officer had counselled him to come back if he had any further complaints, though the doctor did not mention scrotal pain. When he developed sudden severe scrotal pain, he quickly took to the advice of the doctor. This case has emphasized the role of counselling in clinical practice. Hence, we should learn to counsel our patients appropriately and adequately in spite of our busy schedule.

This case has highlighted the role of transportation and accessibility in the presentation of torsion of the testis. The patient was living in the university male hostel, located at a short distance from the Accident and Emergency Department, he immediately walked down with the assistance of two roommates. If he had to hire one or two taxis and probably pass through some narrow windy roads, with numerous pot holes, he could have been delayed. Poor road networks and nonavailability of vehicles may be responsible for delayed presentation of testicular torsion in our environment.

Other factors that contributed to the prompt treatment in this case included the use of mobile phone and early diagnosis. The attending medical officer, on suspecting torsion of the testis, rather than writing a letter to request expert consultation, quickly called a Consultant Urological Surgeon on phone to review the patient. Subsequently, a clinical diagnosis was made and the patient had emergency scrotal exploration and bilateral orchidopexy. In other centres, early diagnosis is a challenge; the condition is commonly misdiagnosed and scrotal exploration is often delayed.^[13,14] The lesson

here is to have a high index of suspicion and to call the attention of senior colleagues whenever in doubt. Furthermore, instead of writing the traditional “consult letters” that will be delivered by ward orderlies; we should introduce the use of mobile phones as an official means of requesting expert consultation in our hospitals.

It is highly recommendable to initiate series of health education seminars for male undergraduates in our university campuses, educating them about the risk factors, symptoms and the need for emergency surgical intervention in torsion of the testis. This effort will enhance direct self-referral to the hospital in this subgroup of patients, minimizing the usual delay in presentation.

In conclusion, in our environment, patients with torsion of the spermatic cord can present early and be operated promptly if we can provide reinforced public health education to the population at risk; functional mobile phones in our emergency rooms, government-assisted commercial taxis, and good road networks.

Financial Source of Support

None.

Conflicts of Interest

There are no conflicts of interest.

REFERENCES

1. Lee LM, Wright JE, McLoughlin MG. Testicular torsion in the adult. *J Urol* 1983;130:93-4.
2. Witherington R, Jarrell TS. Torsion of the spermatic cord in adults. *J Urol* 1990;143:62-3.
3. Mansbach JM, Forbes P, Peters C. Testicular torsion and risk factors for orchiectomy. *Arch Pediatr Adolesc Med* 2005;159:1167-71.
4. Wein AJ. *Campbell-Walsh Urology*. 10th ed. Section XVI; 132; 3587-3596.
5. Chan JL, Knoll JM, Depowski PL, Williams RA, Schober JM. Mesorchial testicular torsion: Case report and a review of the literature. *Urology* 2009;73:83-6.
6. Blaut S, Steinbach F, Tittel B, Dürig E. Torsion of the spermatic cord after prophylactic orchidopexy. *Aktuelle Urol* 2008;39:147-9.
7. Mor Y, Pinthus JH, Nadu A, Raviv G, Golomb J, Winkler H, *et al*. Testicular fixation following torsion of the spermatic cord—does it guarantee prevention of recurrent torsion events?. *J Urol* 2006;175:171-3.
8. Sessions AE, Rabinowitz R, Hulbert WC, Goldstein MM, Mevorach RA. Testicular torsion: Direction, degree, duration and disinformation. *J Urol* 2003;169:663-5.
9. Kuremu RT. Testicular torsion: Case report. *East Afr Med J* 2004;81:274-6.
10. Visser AJ, Heyns CF. Testicular function after torsion of the spermatic cord. *BJU Int* 2003;92:200-3.
11. Cummings JM, Boullier JA, Sekhon D, Bose K. Adult testicular torsion. *J Urol* 2002;167:2109-10.
12. Barada JH, Weingarten JL, Cromie WJ. Testicular salvage and age-related delay in the presentation of testicular torsion. *J Urol* 1989;142:746-8.
13. Lawani J. Torsion of testis: A real emergency?. *East Afr Med J* 1987;64:675-82.
14. Magoha GAO. Testicular torsion salvage rate in Nigerians in Lagos. *East Afr Med J* 1989;66:324-7.