

## Case Report

# Choroidal Metastases as the Initial Presentation of Lung Cancer: A Rare Scenario

S Shamim, S Vidya, SKH Kabir, B Ghosh

Department of Pulmonary Medicine, Calcutta National Medical College and Hospital, Kolkata, West Bengal, India

**Date of Acceptance:**  
26-Sep-2016

ABSTRACT

Clinical reports of symptomatic intraocular metastasis as the initial presentation of lung cancer are rare. We report the case of a 49-year-old female patient who presented with loss of vision due to choroidal metastases as the initial manifestation of her disseminated lung cancer. This particular patient was referred to us from ophthalmology department as a case of choroidal metastases from unknown primary. Detailed evaluation at our department helped detect the primary to be a nonsmall cell carcinoma of the right lung, which had multiple distant metastases.

**KEYWORDS:** Choroidal metastases, lung cancer, sudden loss of vision

## INTRODUCTION

Metastatic tumors are the most common intraocular malignancies, and choroid is the most common intraocular site for malignancies. Lung cancer is the first cause of choroidal metastasis in men, as breast cancer is in women. However, the incidence of choroidal metastasis in lung cancer is very low, reported to be 2–7% according to international literature.<sup>[1,2]</sup> This case stands as yet another rare evidence for this uncommon presentation, a disseminated lung cancer manifesting itself with no other symptoms but for those related to the choroidal metastases.

## CASE REPORT

A 49-year-old female patient presented with complaint of sudden painless loss of vision in left eye for the past 3 days, before which vision was apparently normal in both eyes. Initially, she noted blurred vision while chopping vegetables, which then progressed rapidly. On self-examination by covering and uncovering each eye alternatively, she confirmed the visual loss in left eye. There was also history of flashing lights (photopsia) and black spots (floaters). There was no history of trauma/headache. Alarmed by this sudden symptom, the patient consulted an ophthalmologist.

Ophthalmic evaluation revealed visual acuity of 6/18 in right eye while only finger-counting-close-to-face in left eye. Detailed evaluation of left eye was taken

up with Digital Fluorescence Angiography (DFA) and Ultrasound A scan and B scan. DFA revealed hyperfluorescence due to pooling of dye (choroidal fluorescence blocked) with retinal detachment and possibility of huge macular edema or mass [Figure 1]. USG B scan of left eye showed two dome-shaped choroidal masses, larger one measuring  $13 \times 12 \times 5 \text{ mm}^3$  and a smaller one, temporal to the larger one, measuring  $4.5 \times 4 \times 1.5 \text{ mm}^3$ , and small exudative retinal detachment noted [Figure 2]. The ophthalmologist opined that since strikingly two masses were seen, they were suspicious, more of metastases, than a primary choroidal lesion. So, they advised USG breast and chest x-ray, but as both turned out apparently normal, the patient was referred to our department for further evaluation.

At our department, complete evaluation was undertaken. When history was elicited, patient initially denied any complaint other than visual loss. However, on repeated enquiry, patient could recollect having had symptoms of occasional cough with scanty mucoid expectoration, right-sided chest discomfort for last 2 months, which were too mild that she could choose to ignore. No history of breathlessness, wheeze, loss of appetite, or

**Address for correspondence:** Dr. S Vidya, Department of Pulmonary Medicine, Calcutta National Medical College and Hospital, 24 Gorachand Road, Kolkata, West Bengal, India. E-mail: [vippy08@gmail.com](mailto:vippy08@gmail.com)

This is an open access article distributed under the terms of the Creative Commons Attribution-NonCommercial-ShareAlike 3.0 License, which allows others to remix, tweak, and build upon the work non-commercially, as long as the author is credited and the new creations are licensed under the identical terms.

**For reprints contact:** [reprints@medknow.com](mailto:reprints@medknow.com)

**How to cite this article:** Shamim S, Vidya S, Kabir S, Ghosh B. Choroidal metastases as the initial presentation of lung cancer: A rare scenario. *Niger J Clin Pract* 2017;20:905-9.

### Access this article online

#### Quick Response Code:



**Website:** [www.njconline.com](http://www.njconline.com)

**DOI:** 10.4103/1119-3077.212439

weight loss. She had no addiction and was a nondiabetic and nonhypertensive.

On examination, patient was of average built with normal BMI. Chest examination revealed dull note in right infrascapular area with diminished breath sound. Breast examination was normal. There was also a right supraclavicular lymphadenopathy, single, 2 cm × 2 cm, hard, and fixed.

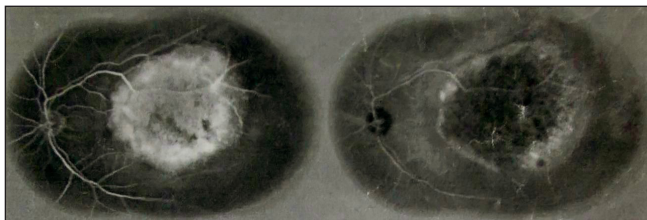
Routine blood investigations were normal. Sputum examination for acid-fast bacilli was negative. USG breast was normal. USG abdomen was also normal but revealed minimal right-sided pleural effusion.

The chest x-ray Posteroanterior view, which had been considered normal, was reviewed by us. On careful evaluation, right parahilar prominence was noted [Figure 3]. Hence, we advised Contrast Enhanced Computed Tomography (CECT) thorax, which promptly revealed a right hilar mass encasing the lower lobe bronchus with collapse of lower lobe, mediastinal

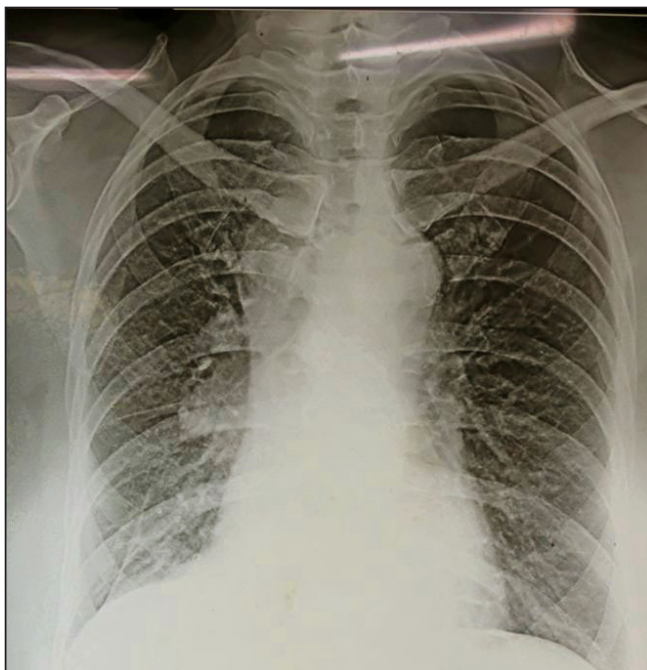
lymphadenopathy, and mild right-sided pleural effusion [Figure 4].

Sputum for malignant cell was negative. Patient did not consent for bronchoscopy. Hence, Computed Tomography (CT)-guided fine needle aspiration cytology from the right hilar mass was done and reported Non-small cell lung carcinoma (NSCLC), possibly squamous cell carcinoma [Figure 5]. Incision biopsy of supraclavicular lymph node showed metastatic deposit of malignant squamous cells, thus confirming the histologic subtype [Figures 6-8].

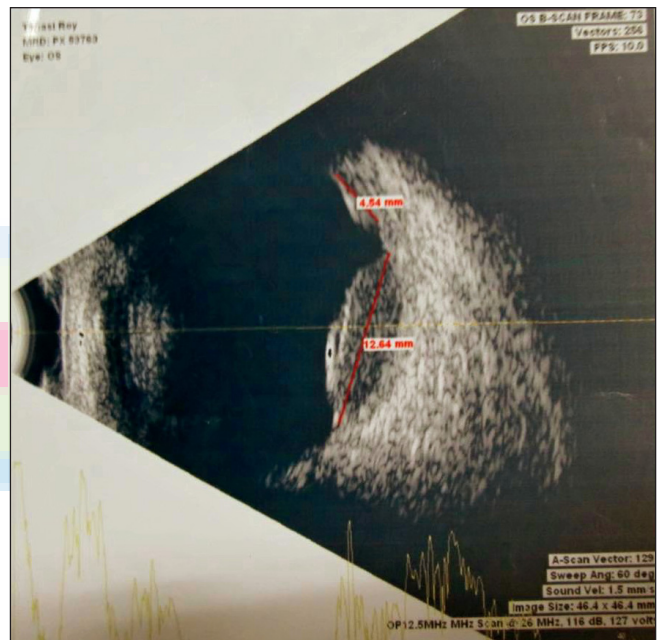
For staging, Magnetic Resonance Imaging (MRI) of brain and whole body PET-CT were done. MRI showed no evidence of brain metastasis. Positron Emission Tomography- Computed Tomography (PET-CT) showed



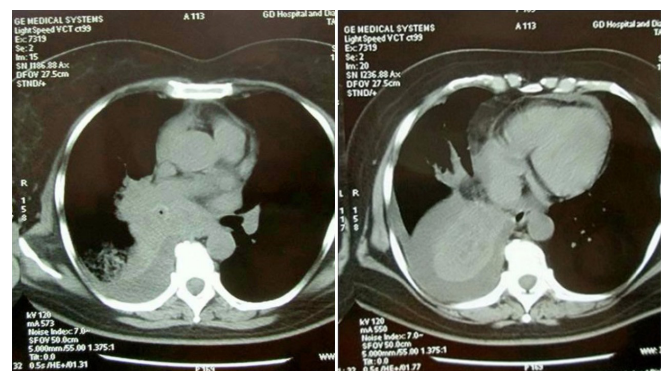**Figure 1:** Digital fluorescence angiography of left eye showing hyperfluorescence due to pooling of dye (choroidal fluorescence blocked) with retinal detachment and possibility of huge macular edema or mass



**Figure 3:** Chest radiography showing right parahilar prominence



**Figure 2:** Ultrasound B scan of left eye showing two dome-shaped choroidal masses, larger one measuring 13 × 12 × 5 mm<sup>3</sup> and the smaller temporal to the larger one, measuring 4.5 × 4 × 1.5 mm<sup>3</sup>, and small exudative retinal detachment



**Figure 4:** Contrast-enhanced computed tomography thorax showing a right hilar mass encasing the lower lobe bronchus with collapse of lower lobe and mild right-sided pleural effusion



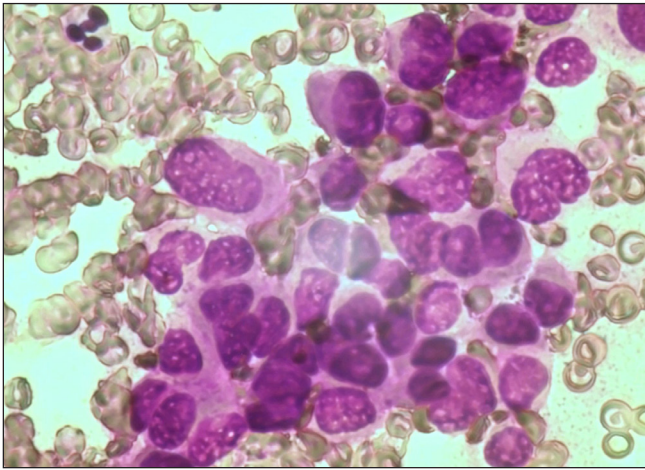
active primary disease in right lung mass encasing the lower lobe bronchus, causing collapse, >6 cm in greatest diameter, close to carina, and pleural effusion, mediastinal lymphadenopathy with involvement of

right supraclavicular node, distant metastasis to liver, intra-abdominal nodes, and entire skeleton [Figures 9-11].

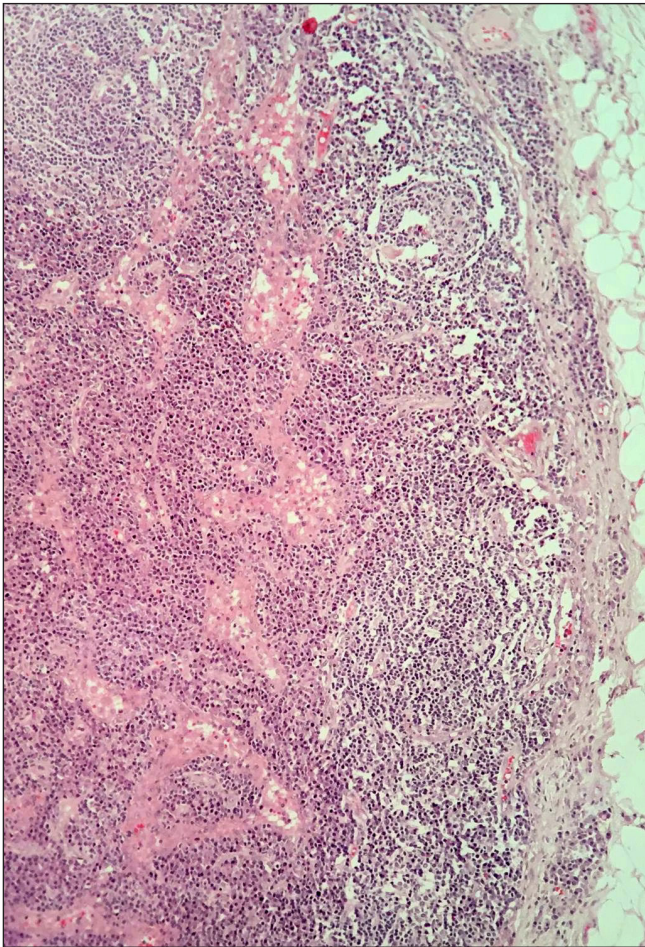
Thus, a final diagnosis of squamous cell carcinoma of right lung stage IV was made. Since she was an Asian nonsmoker female patient, though squamous by histology, Epidermal Growth Factor Receptor (EGFR) mutation study was undertaken with the lymph node sample, which turned out to be negative. The patient was put on palliative chemotherapy with intravenous carboplatin and paclitaxel.

## DISCUSSION

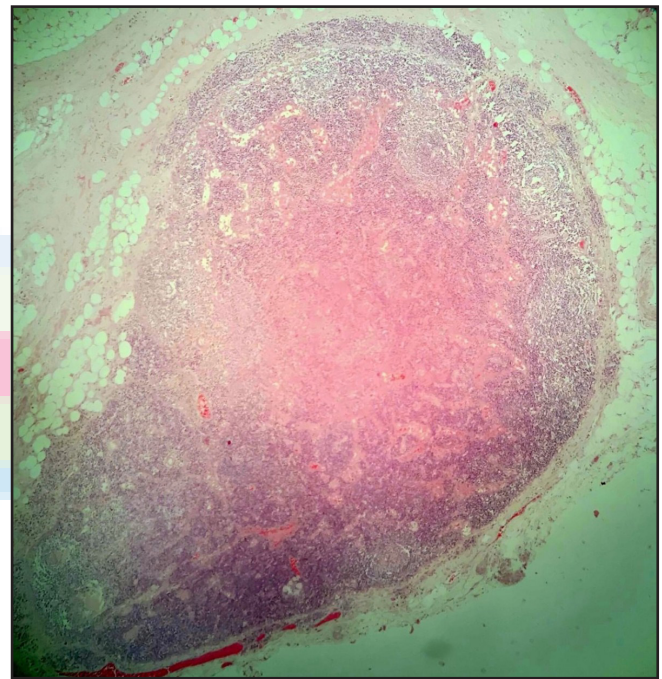
Perls reported the first case of choroidal metastasis in 1872.<sup>[3]</sup> The most common primary includes breast cancer and



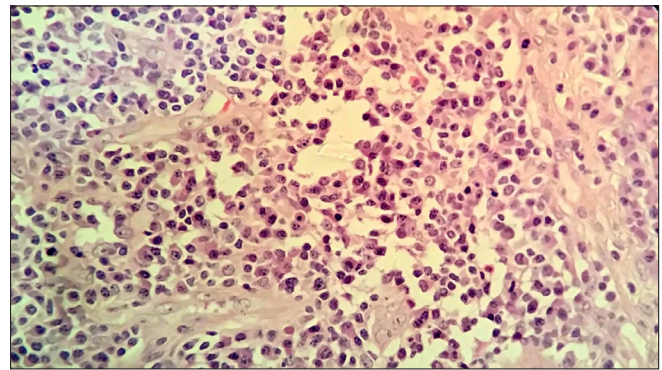
**Figure 5:** Fine needle aspiration cytology of the right lung hilar mass, suggestive of nonsmall cell lung carcinoma, possibly squamous cell carcinoma



**Figure 7:** Photomicrograph of the histologic section of supraclavicular lymphnode suggestive of poorly differentiated squamous cell carcinoma (magnification: ×20)

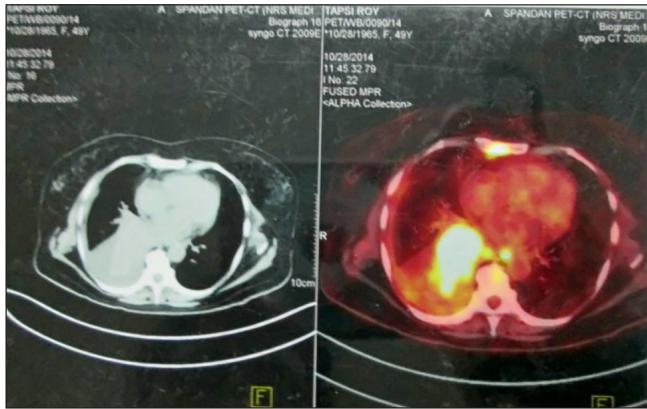

**Figure 6:** Photomicrograph of the histologic section of supraclavicular lymphnode suggestive of poorly differentiated squamous cell carcinoma (magnification: ×2)

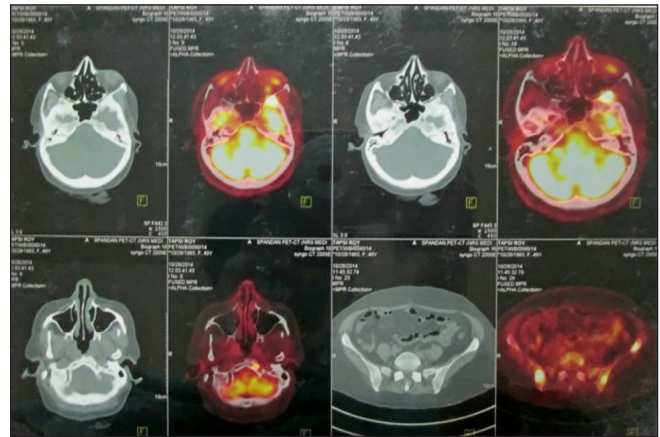


**Figure 8:** Photomicrograph of the histologic section of supraclavicular lymphnode suggestive of poorly differentiated squamous cell carcinoma (magnification: ×40)

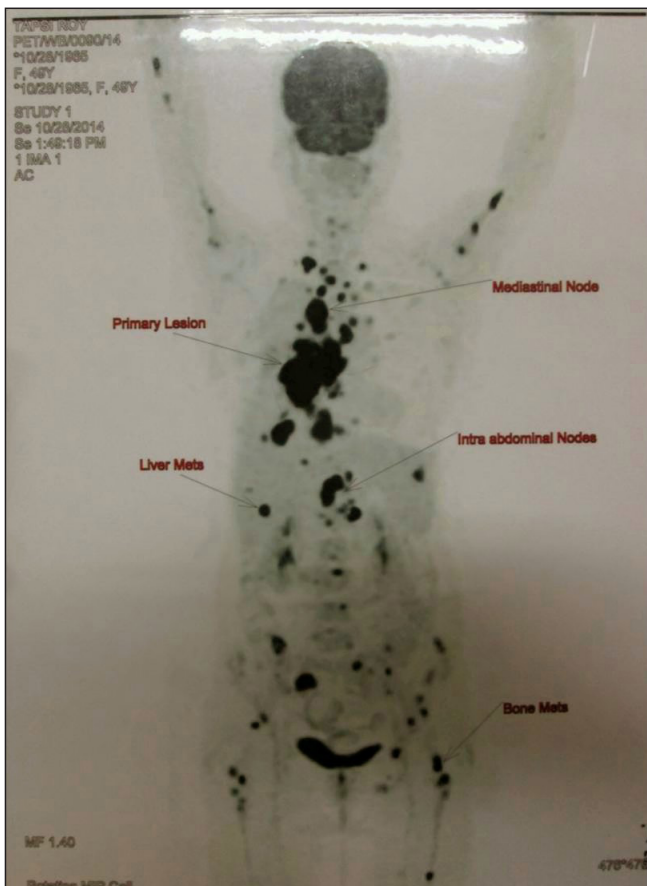




**Figure 9:** PET-CT showing active primary disease in right lung mass encasing the lower lobe bronchus causing collapse and pleural effusion



**Figure 10:** PET-CT showing increased uptake in the left eye posterior aspect and in the right supraclavicular lymph node



**Figure 11:** PET scan showing the primary and the distant metastasis to liver, intra-abdominal nodes, and bone

lung cancer. Patients typically present with blurred vision (70–81%), flashes and floaters (5–12%), and pain (5–14%).<sup>[4]</sup>

Symptomatic choroidal metastasis is, however, a rare presenting manifestation of lung cancer. According to a systematic review of literatures relating to choroidal metastases in lung cancer, majority of such patients were male (67.3%) and current or ex-smokers (78.3%);

adenocarcinoma was the most common histology. Among patients for whom the location of primary lesion was specified, the left upper lobe was the most common site.<sup>[5]</sup>

### PECULIARITIES OF OUR CASE

- Metastasis to choroid from NSCLC is rare. Rarer is the choroidal metastasis itself being the initial presentation
- In rare occasions were the choroidal metastasis precedes the diagnosis of a systemic cancer, only less than half the patients have the primary tumor site identified with evaluation, lung being the primary in 35%. Our case is one such<sup>[6]</sup>
- Given the extensive dissemination, strikingly our patient was disproportionately asymptomatic
- This case stresses the significance of in-depth interpretation of chest x-ray and the need to evaluate suspicious shadow, if any, with CECT thorax, for it helps to pick the primary up with increased sensitivity.

To conclude, a systematic search for lung cancer is required in patients presenting as choroidal metastasis, and histologically adapted chemotherapy must be instituted. Although prognosis is poor, increased awareness regarding this rare presentation of lung cancer can help with its prompt recognition and appropriate management.

### Financial support and sponsorship

Nil.

### Conflicts of interest

There are no conflicts of interest.

### REFERENCES

1. Kreusel KM, Bornfeld N, Hosten N, Wiegel T, Foerster MH. Solitary choroidal metastasis as the first sign of metastatic lung carcinoid. *Arch Ophthalmol* 1998;116:1396-7.

2. Simsek T, Ozdamar Y, Berker N. Choroidal mass as an initial presentation of lung cancer. *Med Oncol* 2008;25:400-2.
3. Perls M. Contributions to pathology of tumors. *Virchows Arch Pathol Anat* 1872;56:437.
4. Arepalli S, Kaliki S, Shields CL. Choroidal metastases: Origin, features, and therapy. *Indian J Ophthalmol* 2015;63:122-7.
5. Singh N, Kulkarni P, Aggarwal AN, Rai Mittal B, Gupta N, Behera D, *et al.* Choroidal metastasis as a presenting manifestation of lung cancer: A report of 3 cases and systematic review of the literature. *Medicine (Baltimore)* 2012;91:179-94.
6. Shields CL, Shields JA, Gross NE, Schwartz GP, Lally SE. Survey of 520 eyes with uveal metastases. *Ophthalmology* 1997;104:1265-76.

