

## Original Article

# Comparative Evaluation of Ankaferd Blood Stopper, Ferric Sulfate, and Formocresol as Pulpotomy Agent in Primary Teeth: A Clinical Study

B Ozmen, S Bayrak<sup>1</sup>

Department of Pediatric Dentistry, Faculty of Dentistry, University of Ondokuz Mayıs, Samsun,  
<sup>1</sup>Department of Pediatric Dentistry, Faculty of Dentistry, University of Eskisehir Osmangazi, Eskisehir, Turkey

### ABSTRACT

**Aim:** The aim of the study was to provide a comparative evaluation of the clinical and radiographic success of Ankaferd blood stopper (ABS), formocresol (FC), and ferric sulfate (FS) as pulpotomy agent in primary teeth. **Settings and Design:** This is a clinical study. **Materials and Methods:** A total of 45 primary mandibular molar teeth in 26 children aged 6–9 were selected for the study. Teeth were randomly divided into three groups according to the pulpotomy agents (ABS, FC, FS). Following treatment, for 24 months, teeth were clinically and radiographically evaluated once every 3 and 6 months respectively. **Statistical Analysis Used:** SPSS version 15 software was used in data analysis. Kaplan–Meier, Log Rank and Fisher’s exact tests were used to analysis. **Results:** After follow-up periods ranging from 6 to 24 months (average 20.8±0.56), the clinical success rates for ABS, FC, and FS were 87%, 87%, and 100% respectively. The overall radiographic success was 87%, 80%, and 87%. When success rates of the ABS were compared with other agents, there were no significant differences between groups ( $P > 0.05$ ). **Conclusion:** Similar success was achieved in the pulpotomy treatment of primary teeth that using ABS, FC, and FS. ABS would be considered a suitable agent for pulpotomy treatment and can be used as an alternative to other agents.

**KEYWORDS:** Ankaferd blood stopper, ferric sulfate, formocresol, primary tooth, pulpotomy

### Date of Acceptance:

24-Jul-2016

## INTRODUCTION

Pulpotomy has been widely accepted as a treatment of cariously or mechanically exposed primary teeth with extensive caries but without evidence of radicular pathology. The coronal pulp is amputated, and the remaining vital radicular pulp tissue surface is treated with a long-term clinically-successful medicament, the tooth is then restored to maintain function and preserve the arch integrity until its exfoliation and the eruption of its successor.<sup>[1]</sup>

Although many agents, such as formocresol (FC), ferric sulfate (FS), calcium hydroxide (CH), and mineral trioxide aggregate have been performed over the years for pulpotomy treatment in primary teeth,<sup>[1–6]</sup> researches which conducted to find alternative medicaments are ongoing.

Ankaferd blood stopper<sup>®</sup> (ABS; Ankaferd Health Products Ltd., Istanbul, Turkey) is a introduced hemostatic solution

that obtained from five different standardized mixtures of the plants which are thymus vulgaris, glycyrrhiza glabra, vitis vinifera, alpinia officinarum, and urtica dioica.<sup>[7]</sup> ABS has been used for centuries as a hemostatic agent in traditional Turkish medicine. The basic mechanism of action for ABS is the formation of an encapsulated protein network. This network formation is related to the functions of blood proteins and red blood cells; especially it provides focal points for the aggregation of vital erythrocytes. *In vitro* tests demonstrated that coagulation factors II, V, VII, VIII, IX, X, XI, and XIII were not affected by the addition of ABS to fresh blood, plasma, or serum.<sup>[8]</sup> Therefore, ABS could be effectively

### Address for correspondence:

Dr. B Ozmen,  
Department of Pediatric Dentistry, Faculty of Dentistry,  
Ondokuz Mayıs University, Atakum, Samsun, Turkey.  
E-mail: bilalozmen@hotmail.com

### Access this article online

#### Quick Response Code:



Website: [www.njcponline.com](http://www.njcponline.com)

DOI: 10.4103/1119-3077.197022

This is an open access article distributed under the terms of the Creative Commons Attribution-NonCommercial-ShareAlike 3.0 License, which allows others to remix, tweak, and build upon the work non-commercially, as long as the author is credited and the new creations are licensed under the identical terms.

For reprints contact: [reprints@medknow.com](mailto:reprints@medknow.com)

**How to cite this article:** Ozmen B, Bayrak S. Comparative evaluation of ankaferd blood stopper, ferric sulfate, and formocresol as pulpotomy agent in primary teeth: A clinical study. Niger J Clin Pract 2017;20:832–8.

used both in individuals with normal hemostatic parameters and in patients with deficient primary and secondary hemostasis.<sup>[7]</sup> Some studies have shown that ABS has been safely used to control bleeding in various types of medical<sup>[9]</sup> and dental treatment.<sup>[10,11]</sup> However, to our knowledge, little published study has investigated the clinical performance of ABS as pulpotomy material in primary teeth<sup>[11]</sup> Therefore, the aim of this study was to evaluate and compare the clinical and radiographical success of ABS, FC, and FS on pulpotomy treatment in primary molar teeth.

## MATERIALS AND METHODS

### Patient selection

The study population consisted of healthy (having no history of systemic diseases or hospitalization) and cooperative children applying for treatment at the Department of Pediatric Dentistry, Faculty of Dentistry, from November 2009 to November 2010. This clinical study was approved by the Clinical Research Ethics Council (2009/103), and informed consent was obtained from the parents of all study participants.

Medical and dental histories were obtained during the initial evaluation of each patient, and clinical and radiographic examinations were performed to assess tooth vitality.

The children having at least one deeply carious mandibular primary molar tooth with following clinical sign and symptoms were included in the study:

- No history of spontaneous, continuous, or severe pain
- No clinical symptoms or evidence of pulp degeneration, such as tenderness to percussion or palpation, swelling or sinus tracts, pathological mobility
- Following coronal pulpal amputation, hemostasis could be easily achievable within 5 min with a sterile moist cotton pellet
- Restorable teeth following completion of procedure.

Radiographic examinations were conducted using a posterior film holder. The following radiographic parameters were assessed:

- Caries lesion should be approximating to the pulp.
- No interradicular or periapical radiolucency or pulp stones
- No internal or pathologic external root resorption and/or inadequate bone support
- No more than one-third physiologic root resorption
- No radiographic pathology, including facial or periapical pathosis.

Sample size was calculated using power analysis and data from previous publication<sup>[3]</sup> ( $n = 15$ ). A total of 52 teeth were assessed for eligibility from November 2009 to November 2010, 7 teeth were excluded for not meeting inclusion criteria and declined to participate (because of one-third physiologic root resorption or periapical pathosis or not restorable). Following clinical and radiographic examinations, 45 mandibular primary molar teeth (20 primary first molar and 25 primary second molar) requiring pulpotomy treatment in 26 children aged 6–9 were selected for inclusion in this study [Figure 1].

### Treatment procedures

All treatment procedures were performed by the same pediatric dentist (BO) using the same protocol. Local anaesthesia (Ultracaine DS Ampul, Sanofi Aventis Ilaclari Ltd. Sti., Istanbul, Turkey) was administered, and teeth were isolated with a rubber dam (OptiDam™ posterior, Kerr, Peterborough, United Kingdom). A sterile high-speed diamond burs (801H016 and 841H012, Meisinger, Hager and Meisinger GmbH, Heisinger, Germany) with water spray was used to prepare an appropriate coronal access cavity to allow removal of all carious lesions. The coronal pulp tissue was completely removed with low-speed round bur (41014, Meisinger Hager and Meisinger GmbH, Heisinger, Germany) and sterile sharp spoon excavator (Jensen JP-1, Dresden, Germany). The pulp chamber was flushed with sterile saline and then dried with sterile cotton pellets. Hemostasis was achieved with moist cotton pellets placed under slight pressure for 5 min. Teeth were then randomly divided into three treatment groups ( $n = 15$ ) according to the pulpotomy agents: FC, FS, ABS (randomization was achieved by coin throwing).

Group 1 (FC): A cotton pellet moistened with 1:5-strength FC (Buckley's Formocresol, Sultan Healthcare, Englewood, NJ, USA) was placed on the pulp stumps for 5 min. After that, the pulp stumps were covered with zinc oxide eugenol (ZOE) cement (Cavex, Haarlem, Holland).

Group 2 (FS): A cotton pellet moistened with 15.5% FS solution (Hemospad, Spad Laboratorie, Dijon Cedex, France) was placed on pulp stumps for 15 sec. Pulp chamber was dried with sterile cotton pellets, and a ZOE base was placed.

Group 3 (ABS): A cotton pellet moistened with ABS solution (Ankaferd Health Products Ltd., Istanbul, Turkey) was placed on the pulp stumps for 15 sec. Pulp chamber was dried with sterile cotton pellets, and covered with ZOE cement.

Class I cavities were restored with amalgam (AM) and class II cavities were restored with a stainless steel crown (SSC) during the same visit. When AM restoration, zinc phosphate cement (Adhesor Cement, Kerr, Jicin, Czech) was placed over the ZOE cement. Glass-ionomer cement (Fuji IX GP, GC Corporation, Tokyo, Japan) was placed over the ZOE and the teeth were restored with SSCs.

**Clinical and radiographic examinations**

All preoperative, immediate postoperative, and recall radiographs were taken with a beam guiding device using paralleling technique. All radiographic films were exposed and processed conventionally under similar conditions and analysed under standardized conditions (darkened room, magnification).

Clinical and radiographic evaluations were performed by two different investigators (BO and SB). Kappa-Cohen test used for examiner calibration showed complete agreement between the two investigators.

Following treatment, study participants were recalled at three-month intervals for 24-month follow-up period. The following clinical parameters were assessed:

- Spontaneous or severe pain
- Pathological mobility
- Swelling or sinus tract
- Tenderness to percussion or palpation

Treatment was recorded as a clinical failure if any of the above parameters were met. The following radiographic parameters were also assessed once every 6 months:

- Furcal or periapical radiolucency
- Widened periodontal ligament spaces
- Internal or external root resorption
- Loss of lamina dura.

Treatment was recorded as a radiographical failure if any of the above parameters were met.

Internal root resorption was regarded as a failure in all instances, but teeth in where internal root resorption was observed were not extracted. Pulp canal obliteration was not regarded as a failure.

**Statistical analysis**

Statistical analysis was performed using the Kaplan–Meier, log rank, and Fisher’s Exact tests (SPSS 15 for Windows, SPSS Inc., Chicago, IL, USA) with the level of significance set at 0.05. Intraexaminer calibration was measured using Kappa-Cohen test.

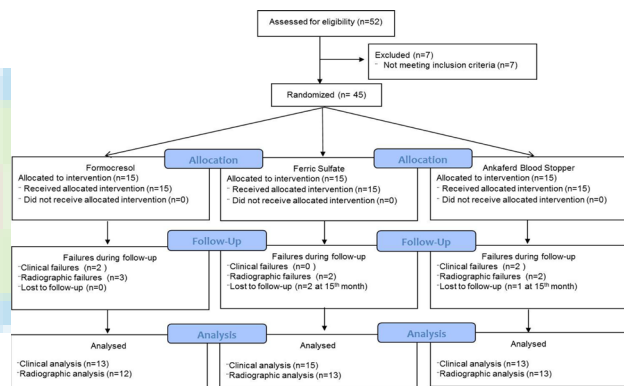
**RESULTS**

The study was conducted with 45 mandibular primary molar teeth in 26 healthy and cooperative children

(14 females, 12 males) aged between 6 and 9 years (mean age:  $7.36 \pm 0.96$  years; in girls:  $6.93 \pm 0.83$ ; in boys:  $7.58 \pm 0.9$ ). The age, gender, types of tooth, and restoration data for each group are presented in [Table 1].

Following treatment, for 24 months follow-up period, teeth were clinically and radiographically evaluated once every 3 and 6 months. The present study follow-up periods were ranging from 6 to 24 months (average  $20.8 \pm 0.56$ ). Three teeth (two-FS group and one-ABS group) were evaluated only 15 months due to loss of patient follow-up.

At the end of follow-up periods, number of teeth with clinically successful were 13, 15, and 13 in ABS, FS, and FC groups, respectively. Twelve teeth in FC group, 13 teeth in FS and ABS groups showed success radiographically [Figure 2]. The clinical and radiographic success rates and survival times of the pulpotomy agents were showed in [Table 2].



**Figure 1:** Flow chart depicting the number of teeth according to enrolment, allocation, failures, lost to follow-up, and final number of teeth analyzed

**Table 1: Distribution of the groups according to age, gender, type of tooth and restoration.**

	FC (n=15)	FS (n=15)	ABS (n=15)
Age (years)	6.78 ± 0.83	7.2 ± 0.92	7.5 ± 0.98
Gender			
Male	5	5	2
Female	4	5	5
Tooth			
First molar	7	6	7
Second molar	8	9	8
Restoration			
SSC	10	10	9
AM	5	5	6

FC=Formocresol; FS=Ferric Sulfate; ABS=Ankaferd Blood Stopper; SSC=Stainless steel crown; AM=Amalgam

According to the results, there were no statistically differences among groups in terms of clinical and radiographic success rates ( $P > 0.05$ ). According to the Kaplan–Meier and log rank analysis, there were no statistically differences among groups in terms of clinical and radiographic survival times (Clinical: Log Rank = 0.49,  $P = 0.78$ ; Radiographic: Log Rank = 2.36,  $P = 0.3$ ).

Time-related clinical success rate was gradually reduced in FC and ABS groups but did not change in FS group. When compared to the clinical success rate according to the follow-up periods of pulpotomy agents, it was determined that FS and ABS had a higher success rates than FC in the 6<sup>th</sup>, 9<sup>th</sup>, 12<sup>th</sup>, 18<sup>th</sup>, and 21<sup>th</sup> months. In the 15<sup>th</sup> and 24<sup>th</sup> months, it was found that clinical success rates of FC and ABS were equal but lower than FS.

At the end of 24 month, the clinical success rates for ABS, formocresol, and ferric sulfate were 87%, 87%, and 100%, respectively. Furthermore, in terms

of clinical success, there was not a statistically significant difference neither among the follow-up periods of each group itself nor between groups ( $P > 0.05$ ).

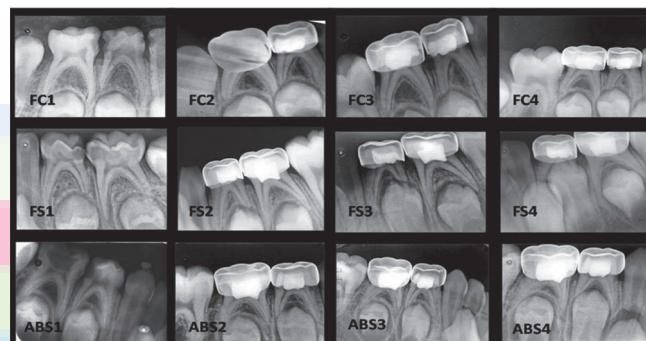
Based on radiographic evaluation, it was determined that radiographic success rates of all pulpotomy agents were found to decrease over time throughout 24 months follow-up. From 18<sup>th</sup> months on, radiographic success rates of ABS and FS were found to be equivalent and higher than FC. At the end of follow-up periods, radiographic failure was observed in seven teeth from all teeth and clinical failure was observed in four of them [Table 3].

According to Fisher’s exact tests, at the end of follow-up periods, it was identified that age, gender, type of tooth, and restoration did not affect the clinical and radiographic success of all groups ( $P > 0.05$ ).

**Table 2: The clinical and radiographic success rates and survival times of the pulpotomy agents**

Groups	Clinical success (%)	Radiographic success (%)	Clinical survival time (Mean ± SD)	Radiographic survival time (Mean ± SD)
FC	87	80	22.4±1.2	23.5±0.5
FS	100	87	21.8±1.0	21.5±1.1
ABS	87	87	22.4±0.8	22.2±0.9
<i>P</i>	>0.05	>0.05	>0.05	>0.05

FC=Formocresol; FS=Ferric Sulfate; ABS=Ankaferd Blood Stopper; SD=Standard Deviation



**Figure 2:** (1) Preoperative radiograph. (2) Postoperative radiograph. (3) Twelve-month follow-up radiograph. (4) Twenty four-month follow-up radiograph (FC=Formocresol, FS=Ferric sulfate, ABS=Ankaferd blood stopper)

**Table 3: Reasons of failures**

Failures	Reasons	Group	Month	Restoration	Tooth
Radiographic	External root resorption	FC	6	SSC	FM
	Internal root resorption	FS	9*	SSC	SM
Both clinical and radiographic	External root resorption	FS	12	SSC	SM
	Pain on percussion, mobility, sinus tract	FC	6	SSC	FM
	Internal root resorption	FC	15*	SSC	FM
	Pain on percussion and spontaneous pain		18		
	Internal root resorption	ABS	6	SSC	FM
	Pain on percussion and spontaneous pain		15		
	Internal root resorption	ABS	6	SSC	FM
	Pain on percussion and spontaneous pain		24		

FS=Ferric Sulfate; ABS=Ankaferd Blood Stopper; FC=Formocresol; SSC=Stainless steel crown; FM=First molar; SM=Second molar.

\*Internal root resorption was detected by radiograph taken for other dental treatments



## DISCUSSION

In the present study, FC, FS, and ABS, which has been used recently as pulpotomy agent in primary molars, were evaluated. This study's results showed that the clinical success rate of ABS pulpotomies after follow-up period was 87%, which was not significantly different than that of the FC (87%) and FS (100%) pulpotomy groups. Radiographic success rates of ABS, FC, and FS pulpotomies were 87%, 80%, and 87%. All that were in agreement with previous pulpotomy studies.<sup>[4,6,11]</sup>

There have been many discussions in the literature about the safety of using aldehyde-based products.<sup>[11-14]</sup> Kahl *et al.*<sup>[12]</sup> tried to determine the presence of FC in the plasma of children undergoing oral rehabilitation involving pulp treatment under general anesthesia. According to the study, formaldehyde and cresol were undetectable in the plasma. Milnes announced,<sup>[13]</sup> in a detailed review, humans inhale and ingest formaldehyde daily. Owen *et al.*<sup>[14]</sup> determined daily formaldehyde intake from food in a North American diet at 11 mg/day but children are exposed to low doses of formaldehyde in pulp therapy. Hence, formocresol is a safe medicament when used judiciously.<sup>[13]</sup> Moreover, there is no definitive evidence of cancer, mutagenesis, or immune sensitization associated with the proper use of formocresol in human pulp treatments. As a result of the discussion on the safety of FC, it could be useful to reduce its exposure time and concentration.<sup>[2,3,6]</sup> If full concentration formocresol is used, its application time (5 min) may be reduced.<sup>[2]</sup> Alternatively, less toxic concentration of FC (diluted at a 5:1 ratio) may be applied for 5 min.<sup>[4,6,11]</sup>

In various studies, FS, which is a hemostatic agent and nonaldehyde chemical, has been used to control pulpal bleeding in primary teeth pulpotomies.<sup>[5,6,15]</sup> It provides ferric ion-protein complex on contact with blood. The complex seal the cut vessels without the presence of a blood clot.<sup>[16]</sup> In the present study, FS was tested due to its increase in popularity as a replacement for FC in pulpotomies.

Nowadays, the use of natural herbs and plant extracts for medicinal purposes has gained extremely importance.<sup>[17]</sup> ABS is an herbal extract obtained from standardized mixture of five different plant extracts. It is claimed that ABS, which is used as a hemostatic agent in traditional Turkish medicine, interact with blood proteins, especially fibrinogen, which leads to the aggregation of erythrocytes, may be used in the treatment of primary teeth pulpotomies.<sup>[8,10,11]</sup> Odabaş *et al.*<sup>[10]</sup> evaluated the effect of the application of a new haemostatic agent (ABS) on the CH pulpotomies in primary molars.

Yaman *et al.*<sup>[11]</sup> used ABS as a vital pulpotomy agent and compared the clinical and radiographic success rates of FC and ABS in primary molars. Follow-up periods in these studies were 12 months. ABS, in the present study, was used as a vital pulpotomy agent, and follow-up periods were ranging from 6 to 24 months (average 20.8±0.56).

Application times of pulpotomy materials, in the dental literature, may be different from each other. For example: application times of FC<sup>[4,11,18]</sup> and glutaraldehyde<sup>[19]</sup> are 5 min, and FS<sup>[4,6,19]</sup> and ABS<sup>[10,11]</sup> are 15 sec. In the present study, application times for diluted FC, FS, and ABS were preferred for 5 min, 15 sec, and 15 sec.

In the dental literature, it was observed that pulpotomy treatments were applied to both the upper and lower jaw primary molars.<sup>[20,21]</sup> Thompson *et al.*<sup>[20]</sup> and Guelmann *et al.*<sup>[21]</sup> reported that there was no difference in terms of treatment success between the upper and lower jaw pulpotomy treatments. However, it was reported that radiographic evaluation was difficult in the upper jaw because of anatomical structures. Therefore, pulpotomy treatments could be perceived as more successful in the upper jaw.<sup>[22]</sup> In the present study, only the lower jaw primary molars were included in order to prevent errors that may occur in radiographic evaluations.

Many studies have investigated the relationship between teeth type and the success rates of the pulpotomies.<sup>[23-25]</sup> Farooq *et al.*<sup>[23]</sup> identified that pulpotomies in the primary second molars were more successful than first molars. On the contrary, in several studies have been reported to be similar failure rates of pulpotomies which applied to first and second molars.<sup>[15,20,24,25]</sup> Similar to these studies, in the present study, it was determined that type of tooth did not affect the clinical and radiographic success of groups.

After the pulpotomy treatment, the long-term sealing ability of the restoration is important for success of the treatment.<sup>[26]</sup> Different restorative materials such as SSC,<sup>[26]</sup> AM,<sup>[6]</sup> composite resin,<sup>[15]</sup> and reinforced ZOE cement<sup>[21]</sup> may be used in the primary teeth pulpotomies. Guelmann *et al.*<sup>[21]</sup> reported that SSC applied in the same session is an ideal restorative material in pulpotomy therapy. Rölling and Thylstrup<sup>[27]</sup> proposed that AM can be used in the occlusal cavity. Holan *et al.*<sup>[24]</sup> assessed the success of SSC and AM restorations in pulpotomies and reported that AM restorations showed successful results in class I cavity. In various studies,<sup>[3-6,19]</sup> cavity types were not mentioned. In the present study, AM was preferred in class I cavities and SSC was performed on class II cavities. It was found that the clinical and radiographic success of materials did not affect from restoration type.

In the present study, the clinical and radiographic success rates in the FC group were 87% and 80%, respectively. At the end of 24-month evaluation period in FC pulpotomies, Huth *et al.*<sup>[15]</sup> reported 87% total success rate, Yildiz and Tosun<sup>[28]</sup> reported 100% clinical and 88.9% radiographic success rates, Erdem *et al.*<sup>[4]</sup> reported 88% total success rate. Ansari and Ranjipour<sup>[29]</sup> detected 90% radiographic success rate at the end of 24 months. The results of these studies were similar to our results.

There were several clinical trials that assessed FS as a pulpotomy agent. Huth *et al.*<sup>[15]</sup> reported 86% total success rate. Sönmez *et al.*<sup>[6]</sup> reported 73.3% radiographic success rate. Erdem *et al.*<sup>[4]</sup> reported 88% total success rate. Yildiz and Tosun<sup>[28]</sup> determined 100% clinical and 86.4% radiographic success rates. In the present study, the clinical and radiographic success rates in the FS group were 100% and 87% at the 24<sup>th</sup> month, which is similar to previous studies with 24-month follow-ups.<sup>[4,6,15,28]</sup>

There were some studies that assessed ABS as a pulpotomy agent.<sup>[10,11]</sup> One of them carried out by Odabaş *et al.*<sup>[10]</sup> They used ABS on CH pulpotomies as a hemostatic agent. Odabaş *et al.*<sup>[10]</sup> showed that the total success rate of CH+ABS pulpotomies after 12 months was 95%, and total success rates in the CH group were 90%. After 12-month evaluation period, Yaman *et al.*<sup>[11]</sup> showed that ABS pulpotomies had the 85.7% total success rates. The present study was the first study that evaluated ABS as a pulpotomy agent for 6 to 24 months (mean 20.8±0.56), and total success was similar to Yaman and colleagues' result.<sup>[11]</sup>

Odabaş *et al.*<sup>[10]</sup> pointed out some causes of failure in pulpotomy treatments. Two of them were misdiagnose of pulp status and microleakage of the final restoration of pulpotomized primary molars.<sup>[10]</sup> Possible reasons for the failures, in the present study, were: misdiagnose of pulp status, presence of infection at the root pulp or irritation of ZOE cement used as a base material.

Several studies reported that the most observed radiographic failure was internal resorption.<sup>[3,6,24]</sup> However, teeth with internal resorption were not extracted until a clinical failure. These teeth may be partially accepted as alive and continue to function. So, internal root resorption may remain stable or may be repaired with hard tissue.<sup>[3,25]</sup> Holan *et al.*<sup>[22]</sup> reported that some teeth with internal resorption were observed to be re-calcified. In the present study, internal resorption was accepted as a radiographic failure, but the teeth were not extracted until a clinical failure occurs. Internal resorption was observed in five teeth (two teeth in ABS group, one tooth in FC group and two teeth in FS group).

In the present study, ABS showed 87% total success rate in primary molar pulpotomies, which was similar to the success rate of FC and FS pulpotomies. Success of ABS pulpotomies may be associated with its antibacterial property<sup>[30]</sup> and agglutination property without the presence of blood clot.<sup>[31]</sup> Considering the absence of any known toxic effects of ABS obtained from standardized mixture of five different plant extracts,<sup>[32]</sup> ABS may be used as an alternative treatment agent in primary teeth pulpotomies. This study's results showed that if high clinical and radiographic success rates are required in pulpotomy treatments, a correct diagnosis is essential. Strengthens of this study, in the pulpotomy treatments, success rate of the ABS, which is an herbal extract and a hemostatic agent, was determined. Follow-up periods ranging from 6 to 24 months but to definite the success rates of ABS, studies with long-term and more cases should be carried out in future.

## CONCLUSION

Similar success was achieved in pulpotomy using FC, FS, and ABS. Within the limitation of the present study, pulpotomy treatments can be applied different cavity types (Class 1 and 2). Different restoration types may be preferred for pulpotomy treatments (AM, SSC). ABS can be considered a possible alternative to the other pulpotomy agents. However, further clinical studies with larger sample sizes, longer follow-up periods, same cavity, and restoration types are required to find the best pulpotomy material in dental practice.

## Financial support and sponsorship

Nil.

## Conflicts of interest

There are no conflicts of interest

## REFERENCES

1. American Academy of Pediatric Dentistry Clinical Affairs Committee-Pulp Therapy Subcommittee; American Academy of Pediatric Dentistry Council on Clinical Affairs. Guideline on pulp therapy for primary and young permanent teeth. *Pediatr Dent* 2005-2006;27:130-34.
2. Kurji ZA, Sigal MJ, Andrews P, Titley K. A retrospective study of a modified 1-minute formocresol pulpotomy technique part 2: Effect on exfoliation times and successors. *Pediatr Dent* 2011;33:139-43.
3. Moretti AB, Sakai VT, Oliveira TM, Fornetti APC, Santos CF, Machado MAAM, *et al.* The effectiveness of mineral trioxide aggregate, calcium hydroxide and formocresol for pulpotomies in primary teeth. *Int Endod J* 2008;41:547-55.
4. Erdem AP, Guven Y, Balli B, Ilhan B, Sepet E, Ulukapi I, *et al.* Success rates of mineral trioxide aggregate, ferric sulfate, and formocresol pulpotomies: A 24-month study. *Pediatr Dent* 2011;33:165-70.
5. Fei AL, Udin RD, Johnson R. A clinical study of ferric sulfate as a pulpotomy agent in primary teeth. *Pediatr Dent*

- 1991;13:327-32.
6. Sonmez D, Sari S, Cetinbaş T. A comparison of four pulpotomy techniques in primary molars: A long-term follow-up. *J Endod* 2008;34:950-5.
  7. Beyazit Y, Kurt M, Kekilli M, Goker H, Haznedaroglu IC. Evaluation of hemostatic effects of Ankaferd as an alternative medicine. *Altern Med Rev* 2010;15:329-36.
  8. Goker H, Haznedaroglu IC, Erceetin S, Kirazli S, Akman U, Ozturk Y, *et al.* Haemostatic actions of the folkloric medicinal plant extract Ankaferd blood stopper. *J Int Med Res* 2008;36:163-70.
  9. Guler M, Maralcan G, Kul S, Baskonus I, Yilmaz M. The efficacy of Ankaferd Blood Stopper for the management of bleeding following total thyroidectomy. *J Invest Surg* 2011;24:205-10.
  10. Odabaş ME, Cinar C, Tulunoğlu O, Işık B. A new haemostatic agent's effect on the success of calcium hydroxide pulpotomy in primary molars. *Pediatr Dent* 2011;33:529-34.
  11. Yaman E, Görken F, Pinar Erdem A, Sepet E, Aytepe Z. Effects of folk medicinal plant extract Ankaferd Blood Stopper® in vital primary molar pulpotomy. *Eur Arch Paediatr Dent* 2012;13:197-202.
  12. Kahl J, Easton J, Johnson G, Zuk J, Wilson S, Galinkin J. Formocresol blood levels in children receiving dental treatment under general anesthesia. *Pediatr Dent* 2008;30:393-9.
  13. Milnes AR. Persuasive evidence that formocresol use in pediatric dentistry is safe. *J Can Den Assoc* 2006;72:247-8.
  14. Owen BA, Dudley CS, Tan EL, Easterly CE. Formaldehyde in drinking water: Comparative hazard evaluation and an approach to regulation. *Regul Toxicol Pharmacol* 1990;11:220-36.
  15. Huth KC, Paschos E, Hajek-Al-Khatir N, Hollweck R, Crispin A, Hickel R, *et al.* Effectiveness of 4 pulpotomy techniques-randomized controlled trial. *J Dent Res* 2005;84:1144-8.
  16. Ranly DM. Pulpotomy therapy in primary teeth: New modalities for old rationales. *Pediatr Dent* 1994;16:403-9.
  17. Lima RV, Esmeraldo MR, de Carvalho MG, de Oliveira PT, de Carvalho RA, da Silva FL, *et al.* Pulp repair after pulpotomy using different pulp capping agents: A comparative histologic analysis. *Pediatr Dent* 2011;33:14-18.
  18. Olatosi OO, Sote EO, Orenuga OO. Effect of mineral trioxide aggregate and formocresol pulpotomy on vital primary teeth: A clinical and radiographic study. *Niger J Clin Pract* 2015;18:292-6.
  19. Goyal P, Pandit IK, Gugnani N, Gupta M, Goel R, Gambhir RS. Clinical and radiographic comparison of various medicaments used for pulpotomy in primary molars: A randomized clinical trial. *Eur J Dent* 2016;10:315-20.
  20. Thompson KS, Seale NS, Nunn ME, Huff G. Alternative method hemorrhage control in full strength formocresol pulpotomy. *Pediatr Dent* 2001;23:217-22.
  21. Guelmann M, Fair J, Turner C, Courts FJ. The success of emergency pulpotomies in primary molars. *Pediatr Dent* 2002;24:217-20.
  22. Holan G, Eidelman E, Fuks AB. Long-term evaluation of pulpotomy in primary molars using mineral trioxide aggregate or formocresol. *Pediatr Dent* 2005;27:129-36.
  23. Farooq NS, Coll JA, Kuwabara A, Shelton P. Success rates of formocresol pulpotomy and indirect pulp therapy in the treatment of deep dentinal caries in primary teeth. *Pediatr Dent* 2000;22:278-86.
  24. Holan G, Fuks AB, Ketzl N. Success rate of formocresol pulpotomy in primary molars restored with stainless steel crown vs amalgam. *Pediatr Dent* 2002;24:212-6.
  25. Smith NL, Seale NS, Nunn ME. Ferric sulfate pulpotomy in primary molars: A retrospective study. *Pediatr Dent* 2000;22:192-9.
  26. Guelmann M, Fair J, Bimstein E. Permanent versus temporary restorations after emergency pulpotomies in primary molars. *Pediatr Dent* 2005;27:478-81.
  27. Rölling I, Thylstrup A. A 3-year clinical follow-up study of pulpotomized primary molars treated with the formocresol technique. *Scand J Dent Res* 1975;83:47-53.
  28. Yildiz E, Tosun G. Evaluation of formocresol, calcium hydroxide, ferric sulfate, and MTA primary molar pulpotomies. *Eur J Dent* 2014;8:234-40.
  29. Ansari G, Ranjpour M. Mineral trioxide aggregate and formocresol pulpotomy of primary teeth: A 2-year follow-up. *Int Endod J* 2010;43:413-8.
  30. Akkoc N, Akcelik M, Haznedaroglu I, Goker H, Turgut M, Aksu S, *et al.* *In vitro* anti-bacterial activities of Ankaferd blood stopper. *Int J Lab Hematol* 2008;30:95.
  31. Baykul T, Alanoglu EG, Kocer G. Use of Ankaferd blood stopper as a hemostatic agent: A clinical experience. *J Contemp Dent Pract* 2010;11:88-94.
  32. Bilgili H, Captug O, Kosar A, Kurt M, Kekilli M, Shorbagi A, *et al.* Oral systemic administration of Ankaferd Blood Stopper has no short-term toxicity in an *in vivo* rabbit experimental model. *Clin Appl Thromb Hemost* 2010;16:533-6.