

## Case Report

# Management of Pediatric Mandibular Fracture Using Orthodontic Vacuum-formed Thermoplastic Splint: A Case Report and Review of Literature

OO Sanu, AOS Ayodele<sup>1</sup>, MO Akeredolu<sup>1</sup>

Department of Child Dental Health, Faculty of Dental Sciences, College of Medicine, University of Lagos/Lagos University Teaching Hospital,  
<sup>1</sup>Department of Child Dental Health, Lagos University Teaching Hospital, Lagos, Nigeria

**Date of Acceptance:**  
25-Apr-2016

### ABSTRACT

Fractures of the mandible are relatively less frequent in children when compared to adults. The anatomic features of children are protected. Children have a higher adaptation to maxillofacial fractures compared to adults. Treatment principles of mandibular fractures in children differ from that of adults due to concerns regarding mandibular growth and the developing dentition. A case of a 6-year-old boy with fractured mandibular symphysis managed by closed reduction using a vacuum formed thermoplastic splint and circummandibular wiring is presented. This article also provides a review of the literature regarding the management of mandibular fracture in young children.

**KEYWORDS:** *Orthodontic vacuum-formed thermoplastic splint, pediatric mandibular fracture, pediatric trauma*

## INTRODUCTION

Fractures of the facial bones and mandible are uncommon in the pediatric age group with the overall frequency being about 1–15%.<sup>[1]</sup> Only 0.8–1.0% of facial fractures occur in children younger than 5 years; and 10–14.7% occurs in patients older than 16 years.<sup>[1,2]</sup> Factors responsible include small volume of facial mass relative to the calvarium, the relative resilience of the pediatric skeleton, higher elasticity, poor pneumatization, thick surrounding adipose tissue, the protected environment in which children live, and stabilization of the mandible and maxilla by the unerupted teeth.<sup>[1]</sup> The frequency of mandibular fractures in children occur at two peaks periods: First, at the age of 6–7 years, associated with the beginning of school attendance;<sup>[1]</sup> and second, at 12–14 years during increased physical activity and participation in sports at puberty and adolescence.<sup>[1,2]</sup>

The mandible is the most frequently fractured facial bone after the nasal bone in the pediatric patient.<sup>[1]</sup> Fractures are usually nondisplaced or greenstick in nature. Grossly displaced pediatric mandibular fracture that requires active treatment is rare.<sup>[2]</sup>

The pediatric patient is a challenge to manage and management is extremely complicated, especially in mixed dentition stage.<sup>[3]</sup> The principles governing the management of mandibular fractures differ in children. A conservative approach is usually indicated in most cases.<sup>[3]</sup> The goal of treatment of these fractures is to restore the underlying bony architecture to the preinjury position, in a stable fashion, as noninvasively as possible, with minimal residual esthetic and functional impairment.<sup>[3]</sup> Open reduction and osteosynthesis of the pediatric fracture with titanium plates and screws or absorbable plates and screws carries risks of a negative effect on the skeletal growth and damaging unerupted teeth.<sup>[4]</sup> Thus, closed reduction is usually advocated.<sup>[4]</sup>

The purpose of this paper is to present a simple method of managing a grossly displaced mandibular fracture in a 6-year-old boy using a vacuum formed thermoplastic


**Address for correspondence:** Dr. OO Sanu,

Department of Child Dental Health, Faculty of Dental Sciences, College of Medicine, University of Lagos/Lagos University Teaching Hospital, PMB 12003, Idiaraba, Lagos, Nigeria.  
E-mail: tosyem@gmail.com

This is an open access article distributed under the terms of the Creative Commons Attribution-NonCommercial-ShareAlike 3.0 License, which allows others to remix, tweak, and build upon the work non-commercially, as long as the author is credited and the new creations are licensed under the identical terms.

**For reprints contact:** [reprints@medknow.com](mailto:reprints@medknow.com)

**How to cite this article:** Sanu OO, Ayodele A, Akeredolu MO. Management of pediatric mandibular fracture using orthodontic vacuum-formed thermoplastic splint: A case report and review of literature. *Niger J Clin Pract* 2017;20:637-41.

Access this article online	
Quick Response Code: 	Website: <a href="http://www.njcponline.com">www.njcponline.com</a>
	DOI: 10.4103/1119-3077.187330

splint which was a practical and effective conservative treatment approach and a subsequent follow-up. The high osteogenic potential of the pediatric mandible allowed a successful management of the case with a high degree of compliance. A literature review was also included.

### CASE REPORT

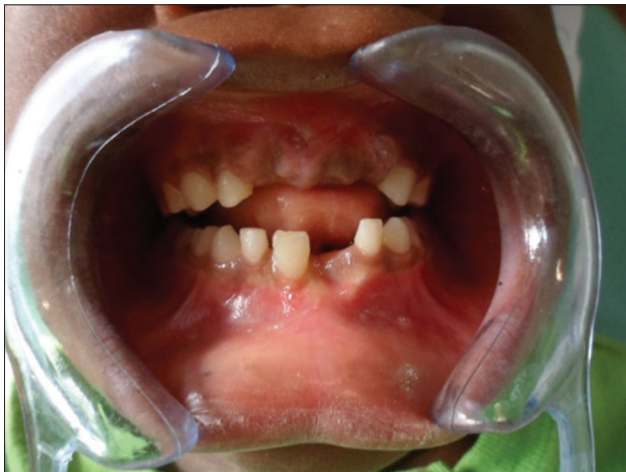A 6-year-old boy presented with a history of a motorcycle road traffic accident, about 10 days after the incidence. There was a history of loss of consciousness, without convulsions or vomiting. The boy sustained a mandibular fracture and multiple facial bruises. The patient appeared anxious but cooperative during the examination.

Teeth 51, 52, 61, and 62 were exfoliated, and tooth 31 was missing. All the other deciduous teeth with 46, 41, and 36 were present. There was a derangement

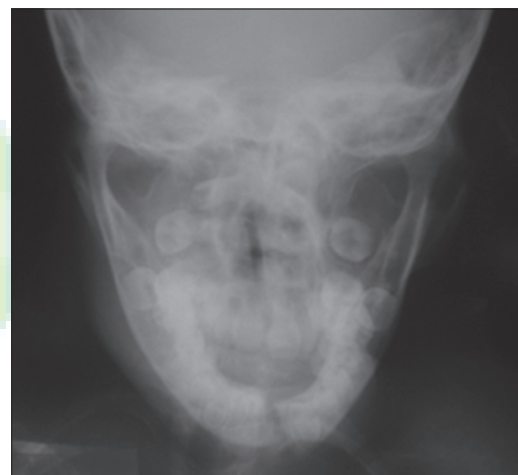
of occlusion, step at the 41, 31 region [Figure 1], and a vertical fracture line between 31 and 72 associated with slightly medially dislocated right mandibular dentoalveolar segment at the symphyseal region. There was no individual tooth fracture present and no tooth in the line of fracture was mobile. There was no fracture elsewhere.

Preoperative posterior-anterior view of the skull revealed a severely displaced fracture at the symphysis [Figure 2]. Wiring was ruled out as there were only deciduous teeth and significant displacement. Plating was contraindicated due to the proximity of the permanent tooth buds. With the suspected concomitant occult condylar injury, it was necessary to maintain mouth opening to prevent any traumatic ankylosis.

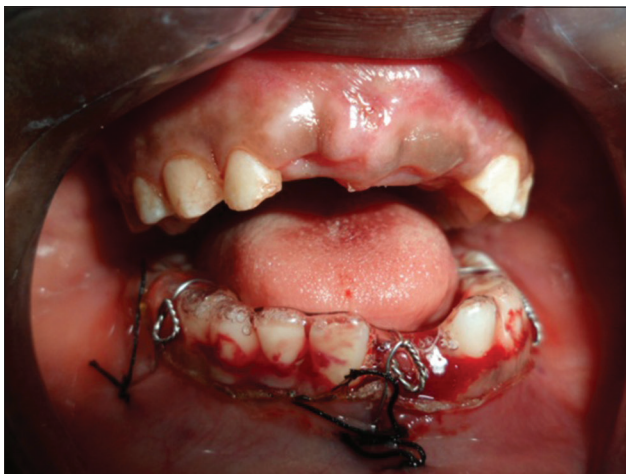Impressions of both jaws were taken with alginate impression material and surgical model prepared with dental stone. The fracture was manually reduced on



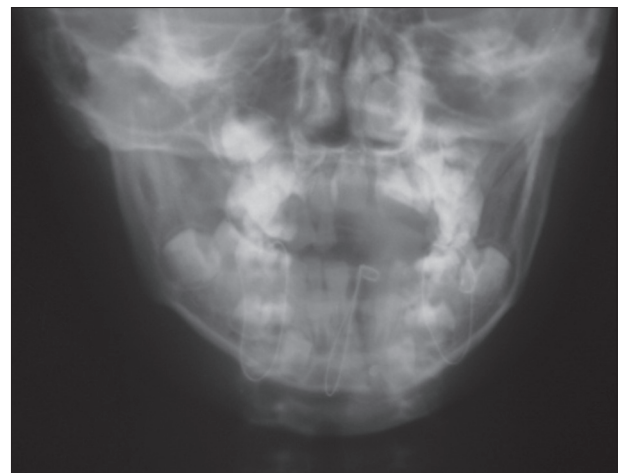
**Figure 1:** Preoperative clinical picture of a 6-year-old boy showing derangement of occlusion. Note the step deformity at the 31 and 72 region



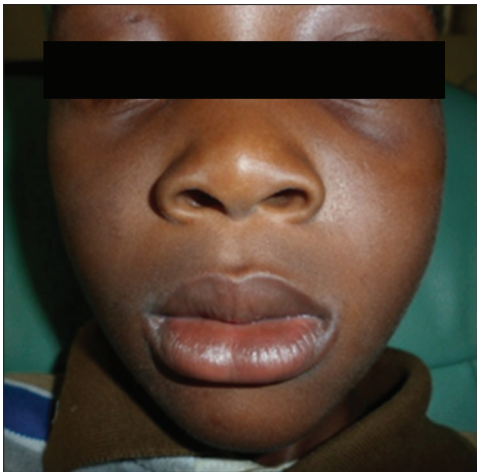**Figure 2:** Posteroanterior view of the skull revealing a symphysis fracture with displacement of the fracture segments



**Figure 3:** Clinical photograph showing reduced mandibular fracture with vacuum formed thermoplastic splint adapted and retained with circummandibular wiring bilaterally and in the center of the mandible



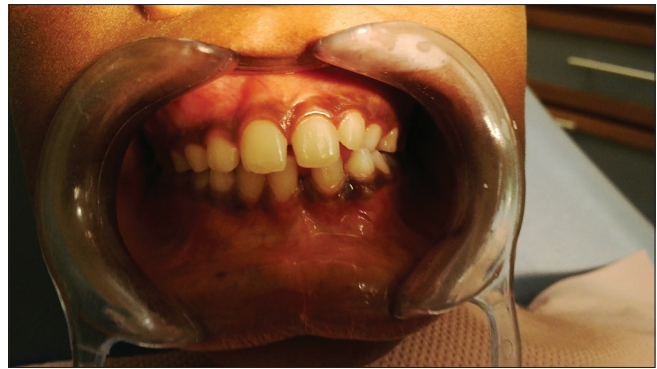**Figure 4:** Postoperative radiograph showing reduction and union of the fracture. Occlusion achieved was satisfactory



**Figure 5:** Postoperative clinical picture of the 6-year-old boy. No facial asymmetry observed

the cast to simulate the reduction that would be done clinically. An orthodontic thick thermoplastic forming sheet (2 mm thick) was adapted on the reduced cast to form a splint using the BioStar thermoplastic forming machine, and the splint was trimmed to fit the cast.

Under local anesthesia with sedation, the fibrous deposit along the symphyseal mandibular fracture line was surgically removed, and the fracture reduced manually and aligned by bi-digital pressure with the guidance of the occlusal plan. The surgical laceration along the fracture was sutured with 3-0 chromic catgut suture. The orthodontic vacuum formed thermoplastic splint was adapted onto the teeth of the reduced mandible and was retained with circum-mandibular wiring bilaterally and in the center of the mandible using 0.4 mm soft stainless steel wire [Figure 3]. Medication administered include Augmentin 375 mg (three times a day, 25 mg/kg) (Duocid, Pfizer, Lagos, Nigeria) and acetaminophen suspension (three times a day, 250 mg) (Calpol, Glaxo-Wellcome, Lagos, Nigeria) for 1 week. The patient was placed on soft diet and instructed to avoid physical activities. At weekly review, both healing and function were satisfactory. On the 3<sup>rd</sup> postoperative week and in the absence of mobility at the fracture site, the splint, and circum-mandibular wire were removed under local anesthesia. Postoperative recovery was uneventful with satisfactory occlusion achieved. Minor spacing noticeable in the incisor-canine region [Figures 4 and 5] had closed on the 2<sup>nd</sup> month follow-up. Further review monthly for 6 months revealed satisfactory occlusion with good masticatory efficiency and healing at the fracture site. At 3-year follow-up visit, the patient showed a healthy dentition in centric occlusion with no signs of ankylosis or disturbance of growth [Figure 6].



**Figure 6:** Intraoral picture of the patient at 3-year follow-up showing a maintained healthy dentition in centric occlusion. There was an uneventful healing

## DISCUSSION AND REVIEW OF LITERATURE

Pediatric facial fractures constitute 1–15% of all facial fractures;<sup>[5]</sup> parasymphiseal fractures are the second most common of mandibular fractures in children (27%), after condylar fractures.<sup>[5]</sup> Incidence rates of pediatric mandibular fractures increase with age,<sup>[6]</sup> A 2:1 male predominance has been reported for all mandibular fractures.<sup>[5,6]</sup>

Falls and sports injuries are the usual causes of mandibular fractures in children with bicycle and all-terrain vehicles accidents accounting for between 17% and 57%.<sup>[6]</sup> Motor vehicle collisions constitute the most obvious cause of serious facial trauma.<sup>[7]</sup> There is a male preponderance attributable partly to males risk-taking activities and more active sports.<sup>[7]</sup> Incidence is however reduced due to the protective anatomic feature of a child's face and the age while fracture fragments are usually minimally displaced due to high elasticity of the young bones and embedded tooth buds that hold the fragments together, flexible suture lines, and a high cancellous-to-cortical bone ratio.<sup>[6,7]</sup>

The imaging technique of value for mandibular trauma in children is a 3 mm thin-section computed tomography scan. Plain radiographs in young children are not as helpful due to the increased incidence of greenstick fractures, unerupted tooth buds obscuring fractures. The choice radiographic view that evaluates the mandible is the Panorex.<sup>[7]</sup>

The highly osteogenic potential of the pediatric mandible makes a high degree of precision unnecessary in its management. Timely management is essential to achieving an optimal outcome as bony fragments may become partially united in 4 days making fractures difficult to reduce by the 7<sup>th</sup> day.<sup>[8]</sup> Thus, timing of intervention must be within the first 48 h after the injury,<sup>[8]</sup> although individualized based on the age at presentation,



dentition status, the location of the fracture and degree of bony displacement, and functional limitations.<sup>[8]</sup> The outcome is determined by the effect that growth has on form and function.<sup>[8]</sup>

Management is aimed at establishing a functional occlusion while limiting any potential impact on normal growth,<sup>[9]</sup> and intervention ranges from observation to open reduction with internal fixation depending on the fracture pattern, the stage of dental development, and the skeletal age.<sup>[8]</sup> Opinion is divided in the treatment of the growing mandible between internal fixation techniques and closed reduction, intermaxillary fixation (IMF), and splints.<sup>[10]</sup> Deciduous teeth offer very little anchorage while only the first molars are adequate for circumferential wiring in mixed dentition stage.<sup>[10]</sup> In the absence of adequate teeth, immobilization with gunning splint or lingual splint can provide good reduced position while preventing any type of fibrous union.<sup>[11]</sup> The thermosetting plastic is a versatile technique that can be used for a wide range of ages in children. Thickness ranging from 1 mm to 4 mm helps in maintaining the occlusion in a reasonable relationship, providing adequate immobilization for fracture fragments and increased joint space to allow active mouth opening to avoid ankylosis.<sup>[12]</sup> Closed reduction is associated with difficulty in placement of wires on the primary teeth, loose anchorage system, danger of avulsion of the insufficiently stable deciduous teeth, and significant weight, and protein loss from dietary restriction.<sup>[12]</sup> Prefabricated acrylic splints are alternative to closed reduction. They are cost effective, easy to use, reduced operating time, minimally traumatic to adjacent anatomical structures, and comforting for young patients than IMF or open reduction techniques.<sup>[13]</sup> Despite a high initial investment of a vacuum-forming unit, vacuum-formed splints have the advantage of less laboratory time, noninvasiveness and maximum preservation of mandible and the developing tooth buds.<sup>[13]</sup> Suitability of open reduction and rigid internal fixation (ORIF) for children remain controversial. The advantages are outweighed by the undesirable effects of implanted hardware in the mandible of a growing child.<sup>[13]</sup> Though recent advances in ORIF have made it a fixation option for pediatric facial fractures with less side effects on the growing skeleton.<sup>[13]</sup> A recent Cochrane review of the relevant literature<sup>[14]</sup> reported insufficient evidence to support this. It is suggested that ORIF be used in children with great caution and only if other means of reduction and fixation are not attainable.<sup>[14]</sup> The treatment of pediatric mandibular fracture does not require the degree of precision required in adults because of the various degrees of self-correction while the high osteogenic potential

of the pediatric mandible is responsible for a low postoperative complication rate.<sup>[7,9]</sup> The main objective of treatment of the mandibular fracture in this reported case was to restore normal occlusion and provide the stability that supports fracture healing, allowing normal eating and drinking and restoration of esthetic in a young child. Six-month follow-up showed complete healing without any complications on the surrounding tissues, good alignment of teeth with no occlusal disharmony or temporomandibular joint problems. These clinical outcomes indicate that fabricated orthodontic thermoplastic vacuum formed splints for conservative treatment of pediatric mandibular fracture are cost-effective, easy to use, less time-consuming, and provide maximum stability during the healing period with minimal trauma to the adjacent anatomic structures. However, periodic long-term follow-up is absolutely essential for the early determination of possible growth disturbances.

Complications associated with pediatric trauma are not severe, except in severely comminuted fractures.<sup>[15]</sup> Malocclusion is rarely reported and is least associated with the use of closed treatment and IMF.

It has been suggested that pediatric mandibular body fractures be followed up on long-term basis postoperatively, with a proper record of facial growth pattern and mandibular movements.<sup>[15]</sup> Marked deformation of the crown and roots have been noticed in teeth in fracture line,<sup>[15]</sup> while long-term effect of fracture and implanted hardware fixation on tooth buds is difficult to predict.<sup>[15]</sup>

## CONCLUSION

The treatment of the fractured pediatric mandible represents a therapeutic challenge complicated by the dynamic nature of the developing mandible, the presence of tooth buds, and dental instability. Orthodontic thermoplastic splint are a novel, easy, and less time-consuming method of immobilizing pediatric mandibular fractures that can increase patient compliance and reduce stress to the child.

## Declaration of patient consent

The authors certify that they have obtained all appropriate patient consent forms. In the form the patient(s) has/have given his/her/their consent for his/her/their images and other clinical information to be reported in the journal. The patients understand that their names and initials will not be published and due efforts will be made to conceal their identity, but anonymity cannot be guaranteed.

## Financial support and sponsorship

Nil.

## Conflicts of interest

There are no conflicts of interest.

## REFERENCES

1. Zimmermann CE, Troulis MJ, Kaban LB. Pediatric facial fractures: Recent advances in prevention, diagnosis and management. *Int J Oral Maxillofac Surg* 2006;35:2-13.
2. Adeyemo WL, Iwegbu IO, Bello SA, Okoturo E, Olaitan AA, Ladeinde AL, *et al.* Management of mandibular fractures in a developing country: A review of 314 cases from two urban centers in Nigeria. *World J Surg* 2008;32:2631-5.
3. Khatri A, Kalra N. A conservative approach to pediatric mandibular fracture management: Outcome and advantages. *Indian J Dent Res* 2011;22:873-6.
4. Eppley BL. Use of resorbable plates and screws in pediatric facial fractures. *J Oral Maxillofac Surg* 2005;63:385-91.
5. Eskitascioglu T, Ozyazgan I, Coruh A, Gunay GK, Yuksel E. Retrospective analysis of two hundred thirty-five pediatric mandibular fracture cases. *Ann Plast Surg* 2009;63:522-30.
6. Kaban LB, Troulis JM. Facial trauma II. Dento alveolar injuries and mandibular fractures. In: *Pediatric Oral and Maxillofacial Surgery*. Philadelphia, Pennsylvania: Saunders; 2004. p. 441-61.
7. John B, John RR, Stalin A, Elango I. Management of mandibular body fractures in pediatric patients: A case report with review of literature. *Contemp Clin Dent* 2010;1:291-6.
8. Goth S, Sawatari Y, Peleg M. Management of pediatric mandible fractures. *J Craniofac Surg* 2012;23:47-56.
9. Sharma S, Vashistha A, Chugh A, Kumar D, Bihani U, Trehan M, *et al.* Pediatric mandibular fractures: A review. *Int J Clin Pediatr Dent* 2009;2:1-5.
10. Crean ST, Sivarajasingam V, Fardy MJ. Conservative approach in the management of mandibular fractures in the early dentition phase. A case report and review of the literature. *Int J Paediatr Dent* 2000;10:229-33.
11. Emmanuel DS, Ramkumar S, Deepak AP. Thermoformed splints in the management of pediatric mandibular fracture – A case report. *SRM Univ J Dent Sci* 2010;1:240-2.
12. Gawelin PJ, Thor AL. Conservative treatment of paediatric mandibular fracture by the use of orthodontic appliance and rubber elastics: Report of a case. *Dent Traumatol* 2005;21:57-9.
13. Kocabay C, Atac MS, Oner B, Gungor N. The conservative approach of pediatric mandibular fractures with prefabricated surgical splint: A case report. *Dent Traumatol* 2007;23:247-50.
14. Dorri M, Nasser M, Oliver R. Resorbable versus titanium plates for facial fractures. *Cochrane Database Syst Rev* 2009;1:CD007158.
15. Koenig WR, Olsson AB, Pensler JM. The fate of developing teeth in facial trauma: Tooth buds in the line of mandibular fractures in children. *Ann Plast Surg* 1994;32:503-5.

