

## Case Report

# Iliacus Abscess with Radiculopathy Mimicking Herniated Nucleus Pulposus: Additional Diagnostic Value of Magnetic Resonance Imaging

DH Kim, SH Woo, WJ Lee

Department of Emergency Medicine, Incheon St. Mary's Hospital, College of Medicine, The Catholic University of Korea, Republic of Korea

ABSTRACT

An iliacus abscess is an extremely rare cause of low back pain. With an iliacus abscess, the classical signs seen with a psoas abscess are frequently absent. Therefore, a timely diagnosis at the initial visit is difficult and inadequate treatment usually results in high mortality. Here, we report the case of 19-year-old man who presented with acute low back pain with radiculopathy and was ultimately diagnosed with an iliacus muscle abscess.

**KEYWORDS:** *Low back pain, Radiculopathy, Iliacus muscle, Abscess, Magnetic resonance imaging*

Acceptance Date: 02-05-2016

## INTRODUCTION

An iliacus abscess is an extremely rare cause of low back pain. A timely diagnosis at the initial visit is difficult and inadequate treatment usually results in high mortality. The classical signs seen with a psoas abscess are frequently absent with an iliacus abscess. The contrast-enhanced CT is acknowledged as the gold standard of imaging for diagnosis. However, MRI can provide additional information on potential sources of back pain and radiculopathy. This report aimed to present the case of iliacus abscess presenting with acute low back pain and radiculopathy.

## CASE REPORT

A 19-year-old man visited our emergency department with a chief complaint of acute low back pain radiating to the right thigh for 5 days. The pain was aggravated by movement and improved with rest. There were no associated symptoms, except dysuria. He was an undergraduate student and had no history of trauma or a contributing medical history. He denied the use of alcohol and tobacco and there was no fever or chills. He had no respiratory, abdominal, or neurologic symptoms. On physical examination, his vital signs were normal. There was no tenderness to palpation over the lumbar spine or bilateral paraspinal muscles. The strength and sensation of both lower extremities were normal. There were no pathological reflexes. The straight-leg-raising (SLR) test was positive and reproduced the back pain and radiating pain to the posterolateral right thigh,

corresponding to the L5/S1 dermatome. Laboratory testing showed an elevated white blood cell count ( $11.46 \times 10^3$  cells/ $\mu$ L), C-reactive protein (18.01 mg/L), and erythrocyte sedimentation rate (66 mm/h). The urinalysis was negative. A simple X-ray of the lumbosacral spine showed no bony abnormality.

Contrast-enhanced computed tomography (CT) of the abdomen-pelvis showed a  $2.0 \times 1.4$ -cm low-density nodular lesion with peripheral wall enhancement in the right iliacus muscle [Figure 1]. On magnetic resonance imaging (MRI), diffuse contrast enhancement was noted in the right erector spinae muscle, in the epidural space from L3 to the sacrum, and in the right iliacus muscle [Figure 2]. There was no disc protrusion or vertebral abnormality. With the impression of an abscess in the right iliacus muscle, he underwent surgical drainage of the abscess. During drainage, yellowish pus discharged from the iliacus muscle. Bacterial culture was positive for *Staphylococcus aureus*. Postoperatively, the patient was treated with intravenous vancomycin. He gradually recovered over a period of 3 days after operation and was discharged on the 4th hospital day in stable condition.

**Address for correspondence:** Dae Hee Kim, Clinical Associate Professor, Dongsuro, Bupyeong-gu, Incheon, Republic of Korea.

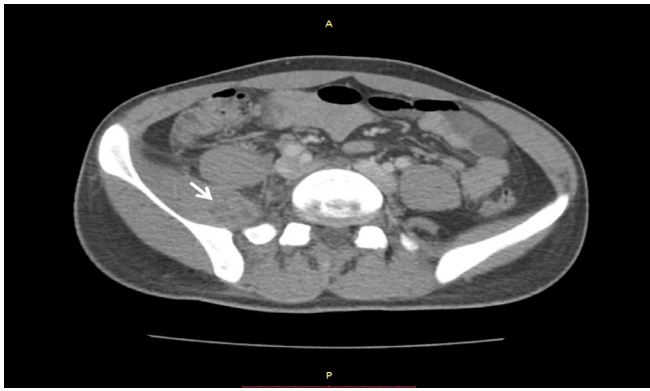
E-mail: [md.kim.daehee@gmail.com](mailto:md.kim.daehee@gmail.com)

This is an open access article distributed under the terms of the Creative Commons Attribution-Non Commercial-Share Alike 3.0 License, which allows others to remix, tweak, and build upon the work non-commercially, as long as the author is credited and the new creations are licensed under the identical terms.

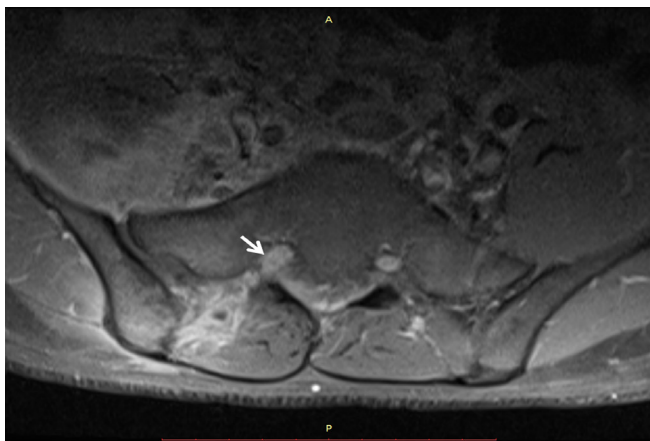
For reprints contact: [reprints@medknow.com](mailto:reprints@medknow.com)

**How to cite this article:** Kim DH, Woo SH, Lee WJ. Iliacus abscess with radiculopathy mimicking herniated nucleus pulposus: A additional diagnostic value of magnetic resonance imaging. *Niger J Clin Pract* 2017;20:392-3.

Access this article online	
Quick Response Code: 	Website: <a href="http://www.njcponline.com">www.njcponline.com</a>
	DOI:10.4103/1119-3077.201433



**Figure 1:** Contrast enhanced computed tomography of the abdomen-pelvis showed a right iliacus abscess (arrow).



**Figure 2:** Gadolinium-enhanced T1-weighted magnetic resonance imaging showed diffuse epidural enhancement (arrow).

## DISCUSSION

The iliopsoas group is a major factor in low back pain. However, abscess formation in this group of muscles is uncommon. Conventionally, iliacus abscesses have been classified as the same disease entity as psoas abscesses. However, the diagnosis of an iliacus abscess is more difficult because of the deeper location and the ambiguity of the symptoms.<sup>[1]</sup>

With an iliacus abscess, the clinical signs seen with a psoas abscess are frequently absent and radiculopathy is extremely rare. Approximately 30% of patients with a psoas abscess present with the classical triad of fever, back pain, and psoas spasm.<sup>[2]</sup> In addition, patients might also complain of malaise, weight loss, anorexia, nausea, and radiculopathy.<sup>3-5]</sup> However, in the case of iliacus abscess, radiculopathy is rare because of the anatomical location of iliacus muscle that does not abut directly on the lumbar vertebrae. By contrast, the psoas muscle is located along the lateral borders of the lumbar vertebrae, so radiculopathy can occur easily with mechanical compression of, or direct inflammatory spread to, the spinal nerve.

Our patient did not have fever at the time of presentation, but did have low back pain with radiculopathy. The SLR test was positive and generated pain radiating to the L5/S1 dermatome. Therefore, our initial impression was a non-inflammatory musculoskeletal disorder, such as a herniated nucleus pulposus. However, laboratory tests showed elevated neutrophil, CRP, and ESR levels and CT showed an abscess in the right iliacus muscle. Nevertheless, the mechanism of the radiculopathy was still unclear. MRI showed diffuse inflammatory spread to the right erector spinae muscle and epidural space. With a sensitivity of 90% and specificity of 80%, contrast-enhanced CT is acknowledged as the gold standard of imaging for diagnosing an iliopsoas abscess.<sup>[6]</sup> However, MRI can provide additional information on potential sources of back pain and radiculopathy.

Iliacus abscesses can be classified into primary and secondary types. The etiology of primary abscesses remains uncertain; age younger than 20 years, male sex, and low socioeconomic status are suggested risk factors.<sup>[3,5]</sup> Our patient had a primary abscess because he did not have any conditions associated with secondary infection.

A diagnosis at the initial visit is quite difficult and is frequently missed initially, as seen with our case. A delayed diagnosis and inadequate treatment of such abscesses usually cause high mortality.<sup>[4,7]</sup> Iliacus abscesses are associated with a significantly higher risk of prolonged morbidity than psoas abscesses.<sup>[1]</sup> Therefore, emergency physicians should consider an iliacus abscess in the differential diagnosis of patients complaining of acute low back pain with radiculopathy.

## Financial support and sponsorship

Nil.

## Conflict of interest

There are no conflicts of interest.

## REFERENCES

1. Kumar AS, Hickerton B, Smith I, Sinha A, Iliacus abscess: an entity to be differentiated from psoas abscess: a review of 15 cases. *Eur J Orthop Surg Traumatol* 2007;17:475-8.
2. C-H Chern, S-C Hu, W-F Kao, Tsai J, Yen D, C-H Lee, Psoas abscess: making an early diagnosis in the ED. *Am J Emerg Med* 1997;15:83-8.
3. Mallick I, Thoufeeq M, Rajendran T, Iliopsoas abscesses. *Postgrad Med J* 2004;80:459-62.
4. Thongngarm T, McMurray R, Primary psoas abscess. *Ann Rheum Dis* 2001;60:173.
5. Walsh TR, Reilly JR, Hanley E, Webster M, Peitzman A, Steed DL, Changing etiology of iliopsoas abscess. *Am J Surg* 1992;163:413-6.
6. Tomich EB, Della-Giustina D, Bilateral psoas abscess in the Emergency Department. *West J Emerg Med* 2009;10:288-91.
7. Gruenewald I, Abrahamson J, Cohen O, Psoas abscess: case report and review of the literature. *J Uro* 1992;147:1624-6.