

Case Report

A Retroperitoneal Extra-Renal Wilms' Tumour: A Case Report

S Wabada, AS Abubakar¹, AI Adamu², A Kabir³, LB Gana³

Paediatric Surgery Unit, Department of Surgery, ¹Department of Anaesthesia and intensive Care, ²Department of Histopathology, ³Department of Paediatric Medicine. University of Maiduguri Teaching Hospital, Maiduguri' Borno State, Nigeria.

Acceptance Date: 25-06-2016

ABSTRACT

Wilms' tumour originates predominantly in the renal tissue; in rare cases it can also arise from extra-renal sites accounting for 0.5-1% of cases of Wilms' tumours seen. A diagnosis of extra-renal Wilms' cannot be easily established with clinical and radiological features except when the histological facts are provided. Wilms' tumours arising from extra-renal sites may not be different in clinical features, protocol of treatment and outcome from a typical intra renal Wilms' tumour. A 2-year-old boy presented with an asymptomatic abdominal swelling for 3 months. Abdominal ultrasound and CT scans revealed an extra-renal mass. Intravenous urogram (IVU) showed prompt excretion bilaterally. Post excision histology of the tumour confirmed a Wilms' tumour.

KEYWORDS: Extra-renal, Wilms' tumour, retroperitoneum, triphasic

INTRODUCTION

Wilms' tumor is the second commonest retroperitoneal tumor in childhood after neuroblastoma and probably the commonly diagnosed abdominal tumor in infants and children in sub-Saharan Africa.^[1] It primarily arises in the kidney, but there have been reports of it arising from other extrarenal sites, in about 0.5–1% of all cases.^[2]

Wilms' tumor is referred extrarenal when both kidneys are normal and the tumors is not connected with them but bears a morphologic resemblance to primary intrarenal Wilms' tumor. Extrarenal Wilms' tumors commonly occur in the retroperitoneum, inguinal canal, scrotum, and vagina.

Other rare sites are the uterus, cervix, ovary, and presacral space.^[3] Occurrence of extrarenal Wilms' tumor is actually exceptional and can be difficult to diagnose preoperatively. Literature search (English) using PubMed, Medline, and Google searches revealed no fewer than 100 cases had been documented to date. This report is to add to this rare diagnosis of a retroperitoneal extrarenal Wilms' tumor.

CASE REPORT

A 2-year-old boy presented with 3 months complaint of a painless right lumbar swelling with no associated hematuria, constitutional symptoms, or symptoms from any other system. Examination revealed a healthy

looking boy, not pale, anicteric, with blood pressure of 100/70 mmHg. A well-defined nonballotable mass involving the whole right lumbar region extending to the mid abdomen and inferiorly to the right iliac fossa was palpated in the abdomen. The upper border of the mass could be palpated in the right hypochondrium, but separate from the liver which had a span of about 8 cm. The left kidney was not ballotable. There were no other associated congenital anomalies and rectal examination was unremarkable. His hematological parameters and serum biochemistry were within normal limits. The liver function test was normal and the α -fetoprotein was 2.5 ng/ml. His urine microscopy culture and sensitivity yielded no bacterial growth. Urinalysis was normal with a pH of 6.0. Ultrasound scan revealed a huge well-defined heterogenous mass in the right hypochondrium displacing the liver upward and the right kidney downward. Multiple cystic components were noted within it, the largest measured 9.47 × 11.62 cm. The right kidney has normal cortical and central sinus echoes. Computed tomography scan of the abdomen showed evidence of

Address for correspondence: Dr. Samuel Wabada, Paediatric Surgery Unit, Department of Surgery, University of Maiduguri Teaching Hospital, Borno State, Nigeria.
E-mail: wabzigu@yahoo.co.uk

This is an open access article distributed under the terms of the Creative Commons Attribution-Non Commercial-Share Alike 3.0 License, which allows others to remix, tweak, and build upon the work non-commercially, as long as the author is credited and the new creations are licensed under the identical terms.

For reprints contact: reprints@medknow.com

How to cite this article: Wabada S, Abubakar AS, Adamu AI, Kabir A, Gana LB. A retroperitoneal extra-renal wilms' tumour: A case report. Niger J Clin Pract 2017;20:388-91.

Access this article online

Quick Response Code:



Website: www.njcponline.com

DOI: 10.4103/1119-3077.201427

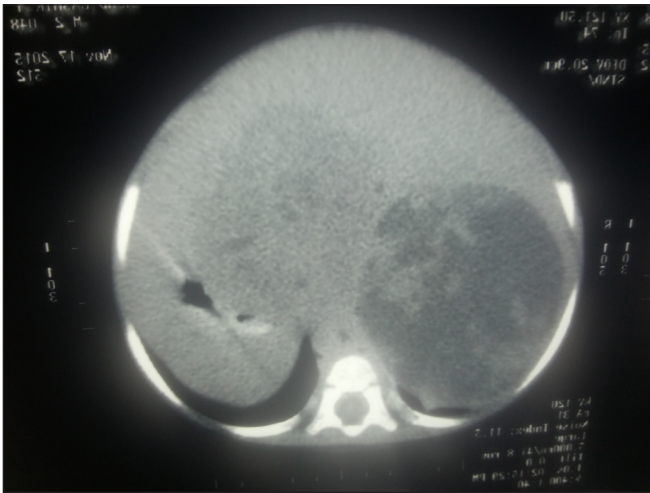

Figure 1: Computed tomography abdomen showing a retroperitoneal suprarenal hypodense mass

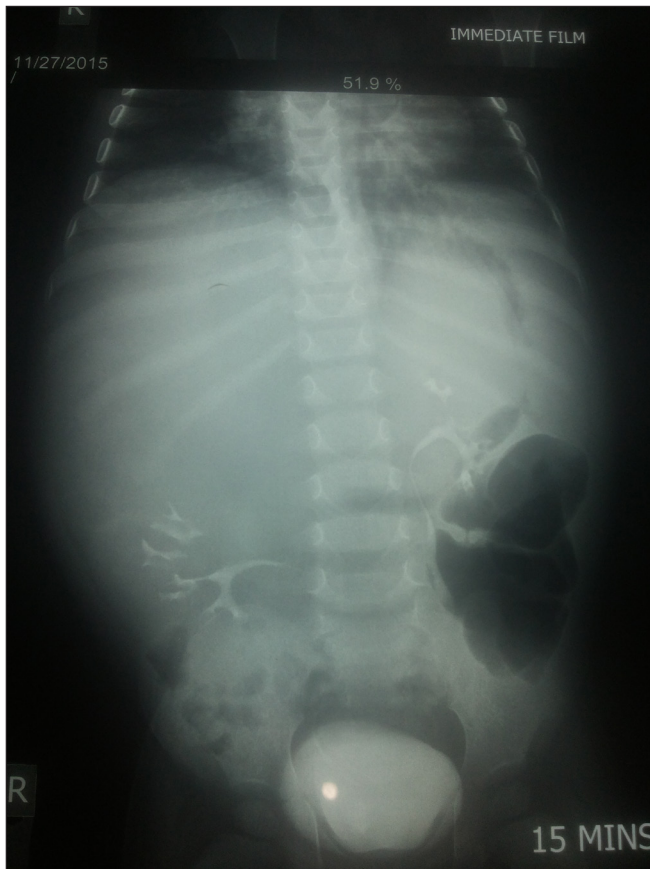

Figure 2: Intravenous urogram showing abnormal location of both kidneys, with more inferior displacement of the right kidney by the extrarenal. The outlined ureters and urinary bladder appear normal with prompt excretion of contrast bilaterally

downward displacement of middle and lower moiety of the right kidney by a huge hypodense soft tissue mass [Figure 1] without any evidence of obstruction of the right kidney. Intravenous urogram showed good and prompt excretion bilaterally by abnormally located

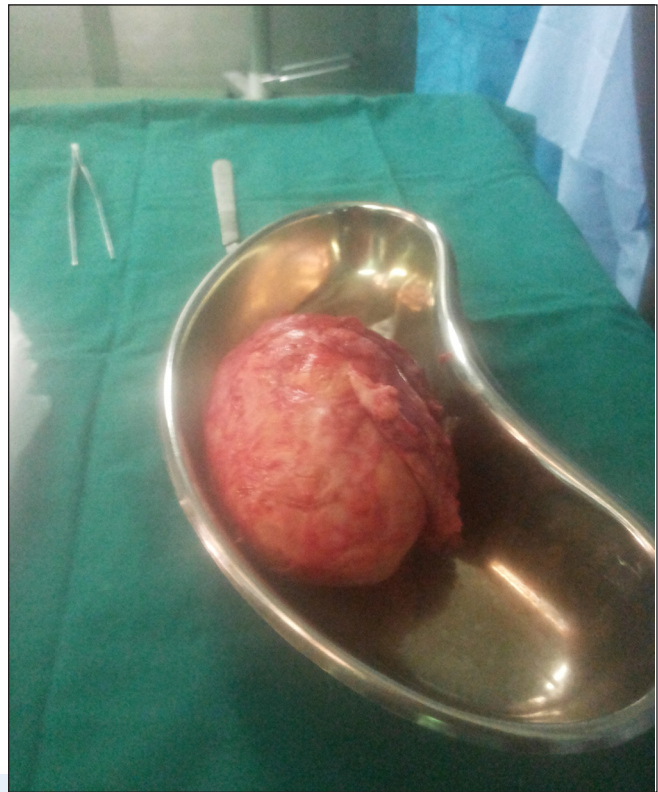

Figure 3: Post excision specimen of the extrarenal retroperitoneal tumor

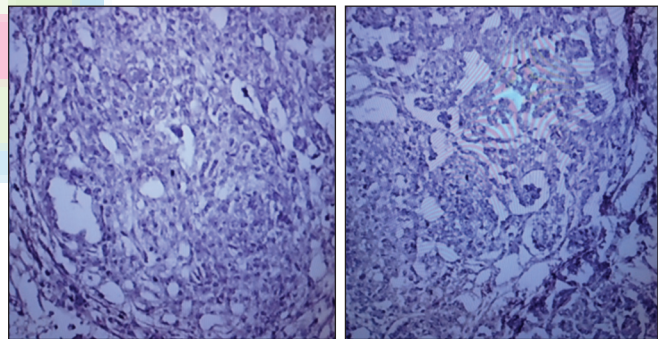


Figure 4: Microscopy of the tumour specimen. (a) Foci of extensive blastemal cells, (b) shows abortive glomerulus (black arrow).

kidneys [Figure 2]. The right kidney is at the level of L4–S1 vertebrae with a normal lateral and inferior borders, irregular medial and superior borders, while the left kidney is adjacent to L1–L3 vertebrae. The chest X-ray was unremarkable. Ultrasound-guided Tru-Cut biopsy of the mass revealed triphasic cells (blastemal, mesenchymal, and epithelial components) histological features consistent with classical intrarenal Wilms' tumor. Consent was obtained from the parents for surgery after discussing the diagnosis and the protocol of management with them. At laparotomy, the intraoperative findings were of a normal liver and normal left kidney. The right kidney was also normal but displaced downward by a huge retroperitoneal firm encapsulated extrarenal mass.

A solitary lymph node was found adjacent to the mass. The mass and the lymph node were removed *en bloc* [Figure 3].

Macroscopy revealed an irregular encapsulated mass weighing 300 g and measuring $9.5 \times 7 \times 7$ cm. Cut surface appeared grayish yellow with no identifiable renal tissue. The lymph node measured $2.5 \times 2 \times 1.5$ cm and the cut surface appeared yellowish.

Microscopy of both specimen (mass and lymph node) showed similar features. Sections showed a triphasic malignant neoplasm composed of blastemal, mesenchymal, and epithelial components consistent with nephroblastoma (Wilms' tumor) [Figure 4].

In retrospect the mass was staged as stage III extrarenal Wilms' tumor according to the Société Internationale d'Oncologie Pédiatrique (SIOP); mass has invaded its capsule and the adjoining para aortic lymph node was positive for neoplasm. The patient is currently on the 14th week of adjuvant chemotherapy comprising actinomycin D and vincristine. A follow-up ultrasound scan of the tumor bed 3-months after surgery, 10th week on adjuvant chemotherapy was unremarkable.

DISCUSSION

As with intrarenal Wilms' tumors in which most children present between 12 and 48 months with a mean age of diagnosis at 36 months, extrarenal Wilms' tumors can similarly present within same age group. Our patient was a boy who presented at 2 years of age, which is the approximate mean age of diagnosis of most Wilms' tumors.^[4]

Occasionally extrarenal Wilms' tumor has been diagnosed in both neonates and adults.^[5-8] A similar finding has also been observed with intrarenal Wilms' tumor.^[9,10] Wilms' tumour diagnosed in neonates and adults are often associated with unfavorable prognosis.^[11]

The exact embryonic origin of extrarenal Wilms' tumor is not certain,^[12] but three theories had been popularized. The first theory ascribed the origin of extrarenal Wilms' tumor to ectopic metanephric blastemal cells. This theory is supported by the persistence of nephrogenic anlage in the retroperitoneal area and other areas from the renal bed to the scrotum, but the presence of extrarenal Wilms' tumour cephalad to the kidney dispute this theory.^[13,14] The second theory was that of persistence of primitive mesodermal tissue. This theory is supported by the presence of primarily primitive mesodermal tissue in extrarenal Wilms' tumors in the vagina, cervix, and inguinal canal where mesonephric duct remnants could be found in line of the renal bed to the scrotum, while those Wilms' tumors unattached to the embryonic line of

renal origin might have arisen from totipotent germ cells and hence may consist of teratomatous tissues in addition to nephroblastic tissues.^[15] The third theory was based on the Connheim's cell rest theory which explained that persistent embryonal cells are likely to undergo malignant transformation at any point in time.

Apart from the classical presentation of painless abdominal swelling in this patient, he was otherwise healthy looking. This pattern of presentation is typical of a classical Wilms' tumour, hence, it could be difficult to assume the case presented was not a classical Wilms' tumor preoperatively considering the clinical presentation, location of the mass, and the age of the patient. Therefore, it is easy to confuse retroperitoneal extrarenal Wilms' tumor with classical Wilms' tumor based on clinical presentation alone, because clinical features can be similar to both of them. However, extrarenal Wilms' tumor located in the cervix, uterus, vagina, inguinal canal, scrotum, and mediastinum may present differently because of their locations.^[16]

Report had also shown evidence of teratoid, spinal dysraphism, and horse-shoe kidneys existing with extrarenal Wilms' tumor in the form of neoplastic and nonneoplastic associations.^[17] Similarly about 10–13% of intrarenal Wilms' tumor are associated with Beckwith–Wiedemann syndrome, aniridia, genitourinary anomalies, mental retardation syndrome, hemihypertrophy, hypospadias, and cryptorchidism.^[18] Although, neither of these syndromes was not present in patient, but it is significant to note that in the presence of any of these syndromes, children with abdominal mass should have immediate work-up for Wilms' tumor. Regarding genetic associations unlike with standard Wilms' tumor, only few cases of extrarenal Wilms' have been found to express the Wilms' tumor suppressor gene *WT1*.^[19]

The serum level of α -fetoprotein was less than 2.0 ng/dL in the patient we presented. α -protein is a common tumor marker in most pediatric embryonal tumors; elevated level of this protein is rare in classical Wilms' tumor except in the presence of a teratoid component. α -fetoprotein was helpful in excluding the differential diagnosis of retroperitoneal teratoma in the patient presented. Other differential diagnosis considered was neuroblastoma though not common in our, environment should still be considered as it can also be seen in the same age group as our patient. This condition often presents with pain from bony metastasis.^[20] The possibility that other embryonal tumors, such as embryonal rhabdomyosarcoma, Burkitt's lymphoma, hepatoblastoma, and mixed Mullerian tumors can also occur in the retroperitoneum apart from retroperitoneal extrarenal Wilms' should not be overlooked in the differential diagnosis of retroperitoneal tumors.

We routinely manage our patients with intrarenal tumors according to the SIOP protocol, except where the diagnosis is not clear preoperatively as in the case presented. The SIOP protocol is suitable for us because it reduces the risk of tumor rupture since most of the patients in the sub-region present with advanced disease. The patient had a classical Wilms' tumor (blastemal, epithelial, and embryonal cells were found in the resected mass) when histology was conducted postoperatively which further confirmed the initial preoperative histology.

Wilms' tumor has been histologically classified as low-risk, intermediate-risk, and high-risk. The significance of this histologic classification of Wilms' tumor based on risk stratification has been recognized by the SIOP study group because of its benefit of reducing extent of treatment for the favorable tumor. According to the SIOP protocol Wilms' tumors can be low-risk tumors if it is has become completely necrotic after chemotherapy, can be intermediate-risk tumour if it is triphasic (blastemal, epithelial, and embryonal cells) which may have a favorable outcome, this also include those with focal anaplasia; and can be high-risk tumor if only blastemal cells are found or there is diffuse anaplasia, other tumors, such as clear cell sarcoma and rhabdoid tumor of the kidney were present.^[21] Currently, the recommended principle of management for extrarenal Wilms' tumors is the same as for a standard Wilms' tumor protocol. We commenced our patient on adjuvant chemotherapy (actinomycin D and vincristine). The tumor was staged postoperatively as stage III (invasion beyond the tumor capsule with positive paraaortic lymph node) based on the SIOP staging system.

CONCLUSION

Though extrarenal Wilms' tumors can be difficult to diagnose preoperatively, but, it is not out of place to consider it in the evaluation of patients with an asymptomatic abdominal swelling since delay in establishing diagnosis can cause delay in initiating appropriate therapy.

Financial support and sponsorship

Nil.

Conflicts of interest

There are no conflicts of interest.

REFERENCES

- Ekenze SO, Heij HA, Youngson GG. Kidney tumours. In: Ameh EA, Bickler SW, Lakhoo K, Nwomeh BC, Poenaru D. editors. Paediatric Surgery: A Comprehensive Text for Africa 1st ed Seattle, WA: Global HELP Organisation; 2011. p. 610-13.
- Andrews PE, Kelalis PP, Haase GM. Extrarenal Wilms' tumor: results of the National Wilms' Tumor Study. *J Pediatr Surg* 1992;27:1181-84.
- Shamberger RC, Grosfeld JL, Azmy AF. Renal tumours. In: Carachi R, Grosfeld JL, Azmy AF. *The Surgery of Childhood Tumours*. 2nd ed. Verlag Berlin Heidelberg: Springer; 2008. pp. 171-99.
- Tagge EP, Thomas PB, Othersen HB Jr. In: Wilms' tumour. In: Grosfeld JL, O' Neill jr JA, Fonkalsrud EW, Coran AG. editors. *Paediatric Surgery*. 6th ed. Philadelphia: Mosby Elsevier; 2006. p. 465-86.
- Hussain S, Nizami S, Tareen F. Neonatal extra-renal Wilms' tumour. *J Pak Med Assoc* 2004;54:37-8.
- Koretz MJ, Wang S, Klein FA, Lawrence W. Extra renal adults Wilms' tumour. *Cancer* 1987;60:2484-88.
- Muc RS, Grayson W, Grobbelaar JJ. Adult extrarenal Wilms' tumor occurring in the uterus. *Arch Pathol Lab Med* 2001;125:1081-83.
- Kilton L, Mathews MJ, Cohen MH. Adult Wilms tumour: A report of prolonged survival and review of literature. *J Urol* 1980;124:1-5.
- Hrabovsky EE, Othersen HB Jr, deLorimier A, Kelalis P, Beckwith JB, Takashima J. Wilms' tumour in neonates: a report from the National Wilms' Tumor Study. *J Pediatr Surg* 1986;21:385-7.
- Wadhwa N, Mishra K, Agarwal S. Wilms' tumour in adults: a report of three cases. *Indian J Pathol Microbiol* 2005;48:235-8.
- Coppes MJ, Wilson PC, Weitzman S. Extrarenal Wilms' tumour: staging, treatment, and prognosis. *J Clin Oncol* 1991;9:167-74.
- Fernandes ET, Kumar M, Douglas EC, Wilimas J, Parham DM, Rao BN. Extrarenal Wilms'. *J Pediatr Surg* 1989;24:483-5.
- Cooke A, Deshpande AV, La Hei ER, Kellie S, Arbuckle S, Cummins G. Ectopic nephrogenic rests in children: the clinicosurgical implications. *J Pediatr Surg* 2009;44:e13-6.
- Ceccardeli FE, Beach PD. Multiple urogenital anomalies: propephric, mesonephric and metanephric kidney elements and persistent mullerian duct in an adult male. *J Urol* 1961;85:31-41.
- Tebbi K, Ragab AH, Ternberg JL, Vietti TJ. An extranal Wilms' tumour arising from a sacrococcygeal teratoma. *Clin Pediatr (Phila)* 1974;13:1019-21.
- Benatar B, Wright C, Cooper K. Primary extra renal Wilms' tumor of the uterus presenting as a cervical polyp. *Intl J Gynecol Pathol* 1998;17:277-80.
- Baskaran D. Extrarenal teratoid Wilms' tumour in association with Horseshoe kidney. *Indian J Surg* 2013;75:128-32.
- Ehrlich PF, Shamberger RC. Wilms' tumour. In: Coran AG, Adzick NS, Krummel TM, Laberge JM, Shamberger RC, Caldamone AA, editors. *Paediatric Surgery*. 7th ed. Philadelphia: Saunders Elsevier; 2012. p. 452-69.
- Roberts DJ, Haber D, Sklar J, Crum CP. Extrarenal Wilms' tumors. A study of their relationship with classical renal Wilms' tumor using expression of WT1 as a molecular marker. *Lad invest* 1993;68:528-36.
- Stiller CA, Parkin DM. Human cancer: international variations in the incidence of neuroblastoma. *Int J Cancer* 2006;52: 538-43.
- Vujanic GM, Sandstedt B, Harms D, Kesley A, Leuschner I, de Kraker J. Revised International Society of Paediatric Oncology (SIOP) working classification of renal tumours of childhood. *Med Pediatr Oncol* 2002;38:79-82.