

# Prosthetic rehabilitation of a patient with a resected right temporomandibular joint

M Dinçel, H Kocağaoglu<sup>1</sup>, HÖ Gümüş, H Albayrak

Department of Prosthodontics, Faculty of Dentistry, Erciyes University, Kayseri, <sup>1</sup>Department of Prosthodontics, Faculty of Dentistry, Pamukkale University, Denizli, Turkey

## Abstract

This case report presents the prosthodontic rehabilitation of a patient with a resected right mandible, caused by an accident. Right condyle, ramus, and the posterior part of ramus were affected by the accident. These structures were resected, and the mandible was positioned toward the surgical area and a facial asymmetry was occurred. The patient was treated with a bar-retained maxillary denture with a guide ramp and an implant-supported fixed mandibular prosthesis.

**Key words:** Bar-retained overdenture, dental implant, mandible resection

**Date of Acceptance:** 01-Oct-2015

## Introduction

The prosthodontic treatment of mandibular defects caused by malignant tumors or accidents is compelling for physicians due to the fact that these situations may lead to damage to the temporomandibular joint (TMJ), to speech, and to mastication and swallowing functions, and it can cause a retruded and a deviated mandible toward the resected area with movement.<sup>[1]</sup> In addition to these problems, changed mandibular movement, motor and sensory insufficiency of the mandible, facial asymmetry, and esthetic problems can occur because of missing continuity of the mandible.<sup>[1,2]</sup>

After surgery, due to changes in supporting tissues, the retention and stability of conventional prostheses are negatively affected. Therefore, dental treatments become

more difficult.<sup>[3]</sup> An implant-supported denture, such as a bar-retained denture, can be an effective solution for oral rehabilitation of these patients.<sup>[4,5]</sup>

The main aim of prosthodontic treatment is to retrain the muscles for a mandibular prosthesis and to achieve a centric relation. Because of the unbalanced relationship arising from the shortage of posterior support and vertical overlap, ensuring suitable mandibular positioning and a guidance appliance helps to build an interocclusal relationship is significant.<sup>[3]</sup> In literature, a mandibular or palatal prosthesis with a guide ramp is one of the methods for reducing mandibular deviation.<sup>[1,2,6]</sup>

This report describes the implant-supported prosthetic treatment of a patient with a palatal guidance ramp-positioning apparatus after mandibular resection caused by an accident.

### Address for correspondence:

Dr. H Kocağaoglu,  
Department of Prosthodontics, Faculty of Dentistry,  
Pamukkale University, Doktorlar Caddesi, Denizli, Turkey.  
E-mail: [hasankocaagaoglu@hotmail.com](mailto:hasankocaagaoglu@hotmail.com)

### Access this article online

#### Quick Response Code:



Website: [www.njcponline.com](http://www.njcponline.com)

DOI: 10.4103/1119-3077.181384

This is an open access article distributed under the terms of the Creative Commons Attribution-NonCommercial-ShareAlike 3.0 License, which allows others to remix, tweak, and build upon the work non-commercially, as long as the author is credited and the new creations are licensed under the identical terms.

**For reprints contact:** [reprints@medknow.com](mailto:reprints@medknow.com)

**How to cite this article:** Dinçel M, Kocağaoglu H, Gümüş HÖ, Albayrak H. Prosthetic rehabilitation of a patient with a resected right temporomandibular joint. *Niger J Clin Pract* 2017;20:252-5.

## Case Report

A 50-year-old male patient was referred to the Department of Prosthodontics, Faculty of Dentistry, Erciyes University, for prosthodontic rehabilitation. The history of the patient described the resection of the right TMJ and right ramus after a traffic accident 9 years earlier. He also lost all his maxillary teeth, all right mandibular premolars and molars, and all left mandibular molars. The patient had not used any prosthesis for 9 years. Because of the absence of his right TMJ, during the elevation of the mandible and closing of the mouth, the patient's mandible was deviating to the surgical area and was positioning abnormally. There was a facial asymmetry caused by the depression of the right corner of the mouth. The patient complained of not being able to masticate.

For a diagnostic cast, impressions of both jaws were taken with irreversible hydrocolloid material (Tulip, Cavex, Haarlem, Holland) using a stock tray (Inci Dental, Istanbul, Turkey). After the impressions, casts were obtained. To determine the maxillomandibular relationship, a centric bite record was taken. The prosthetic treatment plan was then carried out on the cast. An implant-supported, bar-retained maxillary overdenture, and an implant-supported fixed mandibular prosthesis were planned. The two canine and two premolar zones were suitable for implant treatment in both sides of the maxilla. Four dental implants (Implance, Istanbul, Turkey), (3.7 mm × 12 mm) were inserted in the left and right canine and premolar areas of the maxilla, and 2 dental implants (implance) were inserted in the left mandible, in the first and second molar regions (3.7 mm × 12 mm, and 4.3 mm × 12 mm, respectively) [Figures 1 and 2]. However, an implant in the right premolar region of the maxilla failed.

Prosthodontic treatment started after the completion of osseointegration. At the beginning of the prosthetic treatment process, the left mandibular premolars were prepared for a metal-ceramic restoration. For the maxillary prosthesis, bar

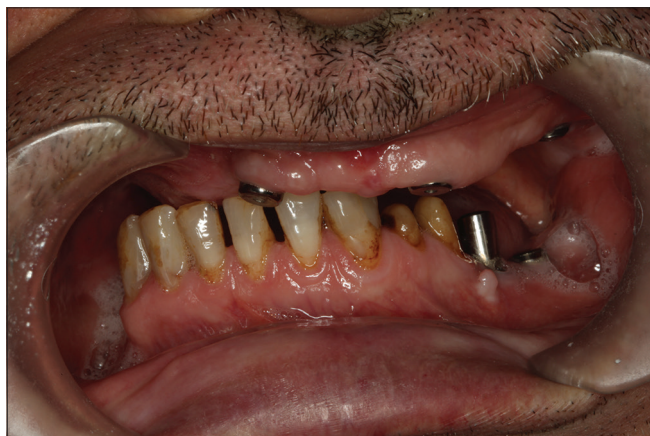impression copings were connected to the implants. Polyether impression material (Impregum Penta; 3M ESPE, California, USA) was then inserted into the tray, and the impression was taken using a closed-tray impression technique. For the mandible, healing abutment was removed from the implants, and impression transfer caps were placed on the implants. The impression was taken with polyether material.

After the impressions materials were polymerized, the impressions were removed from the mouth, and the impression copings were removed from the implants and were connected to the implant analogs and they were inserted into the impressions. For previously prepared mandibular premolar teeth, an impression was taken with irreversible hydrocolloid material to produce temporary restorations and then temporary crowns were cemented onto the left mandibular premolars (Cavex Temporary Cement, Haarlem, Holland).

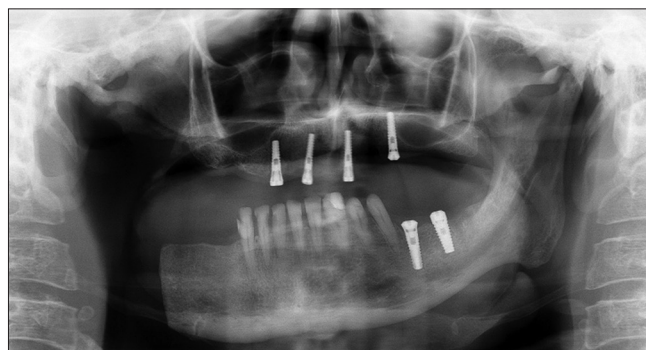
After the impression process, definitive casts were produced. To determine the occlusion vertical dimension, a centric bite record was taken, and the maxillomandibular relationship was recorded with the help of a face bow. The casts were then assembled on a semiadjustable articulator. On the definitive maxillary cast, bar attachments were inserted on each implant analog [Figure 3].

On the definitive mandibular cast, abutments were placed on the implants. After that, the standard laboratory producing process was continued. During elevation of the mandible, to make the mandible slide back to its normal position, a ramp was prepared on the palatal side of the left maxillary teeth. During elevation of the mandible, the left mandibular teeth touched this ramp first, finding their normal position in occlusion with the left maxillary teeth. While setting the teeth on the left side of the maxilla, the teeth were set in two lines. One line of teeth was on the palatal side for occlusion, and the other line was on the buccal side for soft tissue support and for esthetics [Figures 4 and 5].

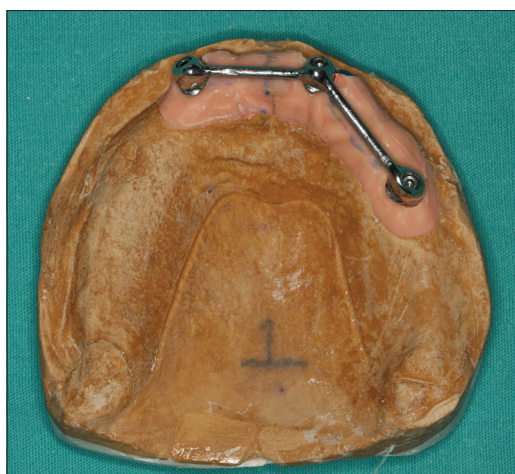The bar-retained maxillary implant-supported denture and fixed metal-ceramic mandibular prosthesis were then



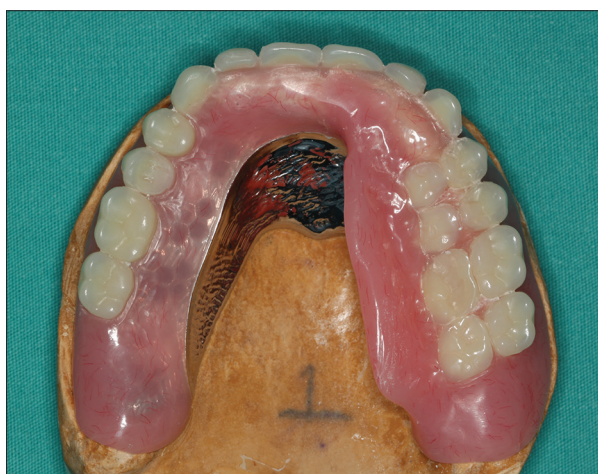**Figure 1:** Intra-oral view of the mandible positioned toward the surgical side



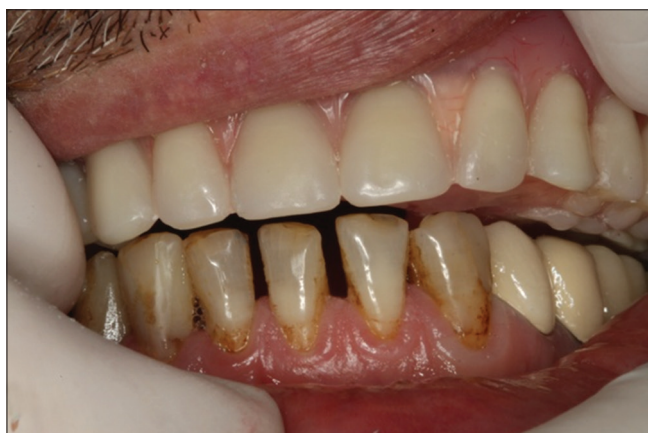**Figure 2:** Radiographic view of the resected mandible and implants



**Figure 3:** Bar and clips attachments



**Figure 4:** Definitive maxillary bar-retained overdenture



**Figure 5:** Occlusion with left maxillary and mandibular teeth

placed in the patient's mouth, and the patient's speech, the occlusion, and the soft tissue harmony of the prosthesis were appraised. Hygiene procedures were explained, and controls were performed at the 1<sup>st</sup> week and 1<sup>st</sup> month after delivery of the prosthesis. At the end of the 1<sup>st</sup> year, the patient was satisfied his prosthesis.

## Discussion

In this case, the bar-retained prosthodontic reconstruction with guide ramp of a patient who had a resected right condyle, ramus, and part of the corpus mandible as a result of a traffic accident 9 years ago was described.

Mandible resections have a negative effect on esthetic, function, speech, and mastication. Before resection, the treatment plan should be performed. In such patients, implant-supported prosthodontic treatments are effective treatments that can solve problems,<sup>[3]</sup> and esthetics and improved function can be achieved by implant-supported overdentures.<sup>[7]</sup> With implant therapy, the success of treatments has increased.<sup>[8]</sup>

The patient had received a surgical operation many years ago, and no prosthetic rehabilitation had been done. For this reason, it was not possible to reconstruct of esthetic and function on the first occasion. The mandible had placed toward the resected area. The muscles had remained in the same position for many years. As a result, ensuring the occlusion was very difficult.

Despite these disadvantages, the muscle structures were now a little closer to their normal positions, there was a more desirable maxillo-mandibular relationship, and the patients was satisfied with his prosthesis at the end of the 1<sup>st</sup> year.

Murat *et al.*<sup>[2]</sup> reported the prosthodontic treatment of a patient with a resected partial mandible caused by a tumor. They made a denture with a guide ramp similar to that in the current case and reported a significant improvement in the patient. Kurtulmus *et al.*<sup>[1]</sup> reported the rehabilitation of a patient with extensive mandibular resection caused by a tumor by achieving an appropriate interocclusal relation with a maxillary guidance ramp prosthesis. They made a maxillary partial removable denture with a ramp.

In order to provide an optimum maxillomandibular relationship, a guide ramp was placed onto the maxillary overdenture in the current case. In addition to this, a double line of acrylic teeth were placed on the left maxillary prosthesis. The internal teeth provided the occlusion, and the external teeth provided the esthetic and soft tissue support. The presentation of such a denture design has not previously been seen in literature.

No treatment was performed on the right mandible of this patient. Because the patient had economic problems, and due to the mandibular movement toward the surgical area, the occlusal relationship would not be provided on the right side. But at the end of 1<sup>st</sup> year, the patient did not want any treatment in that area, and he said that he was satisfied with his denture.

## Conclusion

During the 1<sup>st</sup> week after the delivery of the prosthesis, the patient complained about the difficulty in speaking and chewing because of limited space for his tongue. But after 4 weeks, with the shortening of the guide ramp, the patient was pleased with his prosthesis.

## Financial support and sponsorship

Nil.

## Conflicts of interest

There are no conflicts of interest.

## References

1. Kurtulmus H, Kumbuloglu O, Saygi T, User A. Management of lateral mandibular discontinuity by maxillary guidance. *Br J Oral Maxillofac Surg* 2008;46:123-5.
2. Murat S, Gurbuz A, Kamburoglu K. Rehabilitation of a patient with mandibular resection using osteointegrated implants: A case report. *J Oral Implantol* 2013;39:609-14.
3. Oelgiesser D, Levin L, Barak S, Schwartz-Arad D. Rehabilitation of an irradiated mandible after mandibular resection using implant/tooth-supported fixed prosthesis: A clinical report. *J Prosthet Dent* 2004;91:310-4.
4. Uludag B. Fabrication of a fractured mandibular bar-retained implant overdenture without implant-level impression making: A clinical report. *J Prosthodont* 2012;21:622-5.
5. Slot W, Raghoobar GM, van Dijk G, Meijer HJ. Attachment of clips in a bar-retained maxillary implant overdenture: A clinical report. *J Prosthet Dent* 2012;107:353-7.
6. Schneider RL, Taylor TD. Mandibular resection guidance prostheses: A literature review. *J Prosthet Dent* 1986;55:84-6.
7. de Santis D, Trevisiol L, Cucchi A, Canton LC, Nocini PF. Zygomatic and maxillary implants inserted by means of computer-assisted surgery in a patient with a cleft palate. *J Craniofac Surg* 2010;21:858-62.
8. Abarca M, Budzynski Y, Kovacs B, Malevez C. Multidisciplinary approach in the treatment of a patient with cleft lip and palate: A case report. *J Esthet Restor Dent* 2004;16:102-6.

