

CASE REPORT

Platelet-rich fibrin combined with synthetic nanocrystalline hydroxy apatite granules in the management of radicular cyst

K Pradeep, Adarsh Kudva¹, Vidya Narayanamoorthy, KM Cariappa¹, M Vidya Saraswathi

Departments of Conservative Dentistry and Endodontics and ¹Oral and Maxillofacial Surgery, Manipal College of Dental Sciences, Manipal, Karnataka, India

Abstract

Radicular cysts are inflammatory jaw cysts confined to the apices of teeth with infected and necrotic pulp. They arise from the epithelial residues in the periodontal ligament as a result of inflammation, following the death of pulp. The treatment of such lesions vary with regard to their sizes; the small cystic lesions heal after an endodontic therapy, but larger lesions, may require additional treatment. Apical surgery for radicular cysts generally involves apical root resection and sealing with endodontic material. This case report, describes the treatment of a cyst related to the maxillary central and lateral incisors using platelet rich fibrin along with synthetic nanocrystalline hydroxyapatite granules for the regeneration of lost tissues. A follow-up evaluation at 6 months and 1-year revealed a significant radiographic bone fill with satisfactory healing at the surgical site.

Key words: Hydroxyapatite granules, platelet rich fibrin, radicular lesion

Date of Acceptance: 20-Apr-2015

Introduction

Radicular cysts are common inflammatory cystic lesions that develop in the apical tissues as a consequence of an infected and necrotic pulp.^[1] Most of them are asymptomatic and are noticed when teeth with nonvital pulp are subjected to periapical radiographs. However, some patients may complain of a slowly progressive swelling. The radiographic appearances of most radicular cysts are round or pear shaped unilocular radiolucent lesions enclosing the periapical region of the affected tooth/teeth. The cyst may displace adjacent teeth or cause mild root resorption.^[2] Although in most cases small cystic lesions heal after endodontic therapy while, in larger lesions, additional treatment may be needed.^[3]

Traditional surgical approach to treating periapical defects include debridement of apical lesions along with reshaping of the surrounding bone, resection, and retro filling of root apex, where healing is almost always by repair.^[4] Repair is

defined as the healing of a wound by tissue that does not fully restore the architecture or the function of the part.^[5] Since, repair is not an ideal outcome of wound healing, newer approach such as regenerative procedures aimed to restoring lost tissue have been introduced. Regenerative therapies involving the use of osseous grafts and barrier membranes have been considered for optimal healing of the periapical lesions.^[6]

Porous hydroxyapatite (HA) has been used to fill the periodontal intrabony defects resulting in clinically acceptable response.^[5] There is evidence that porous HA bone grafts have excellent bone conductive properties, which promotes the outgrowth of osteogenic cells from existing bone surfaces into the adjacent bone material.^[6] Barrier membranes are an inert material that maintains a confined space, which is one of the key biological

Address for correspondence:

Dr. K Pradeep,
Department of Conservative Dentistry and Endodontics, Manipal College of Dental Sciences, Manipal - 576 104, Karnataka, India.
E-mail: endopradeep@gmail.com

Access this article online

Quick Response Code:



Website: www.njcponline.com

DOI: 10.4103/1119-3077.188711

requirements for bone regeneration.^[7] Platelet rich fibrin (PRF) is both a healing and a barrier biomaterial. As a healing material, it accelerates wound closure and mucosal healing due to fibrin bandage and growth factor release. As a barrier material, it avoids the early invagination of undesired cells, thereby behaving as a competitive barrier between desired and undesired cells.^[8] Hence, this case is being reported to provide additional scientific information related to the combined use of graft material and barrier membrane in the treatment of periapical lesions.

Case Report

A 32-year-old female patient visited the Department of Endodontics with a chief complaint of pain of 3 months duration in the premaxilla region. The pain was explained as dull and nonradiating in nature. The patient had no contributory medical condition. Dental history revealed that fixed restorations were provided for teeth in the premaxilla region 5 years prior. Clinical examination revealed an ill-fitting acrylic bridge in relation to teeth no. 11, 21, 22 and a dislodged acrylic crown in relation tooth no. 23 [Figure 1a]. Radiographic evaluation of the maxillary anterior teeth, revealed a large periapical unilocular radiolucency with sclerotic border in relation to teeth no. 11 and 21 [Figure 1b]. Further, the acrylic prostheses was removed to determine the vitality of teeth no. 11, 21, 22 and 23; they all presented negative response to the test [Figure 1c].

Teeth no. 11, 21 and 22 were nontender to percussion but grade II mobility was elicited. Based on the details obtained from the patient's history, clinical examination and investigations, a provisional diagnosis of infected radicular cysts in tooth no. 22 was made.

A treatment plan was constituted, in which the affected teeth would undergo root canal therapy followed by surgical intervention. However, prior to the commencement of treatment, the mobile teeth were splinted using a 24 gauge wire and composite resin [Figure 1c] to ensure stability during healing. The root canal treatment was performed teeth no. 11, 21, 22 and 23, using the step back technique until an apical size of no. 50 was obtained. Sodium hypochlorite solution (Novo Dental Product Pvt Ltd., Mumbai, India) of concentration 5.25% was used as canals irrigant during the biomechanical preparation. The root canal treatment was performed in three visits and calcium hydroxide paste with iodoform (Diapex plus, Diadent group International, South Korea) was used as intracanal medicament between appointments. The root canals were obturated using gutta percha (Dentsply Maillefer Ballaigues) and AH 26 (Dentsply DeTrey GmbH, Philadelphia, USA) by the cold lateral compaction technique [Figure 2a].

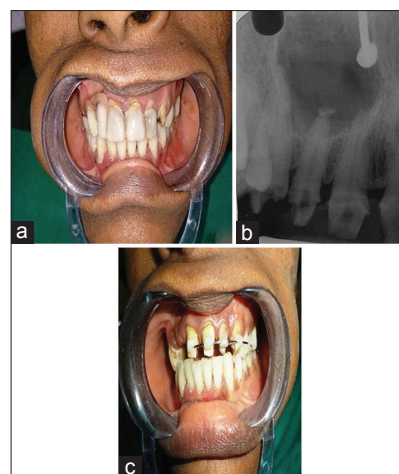


Figure 1: (a) Preoperative clinical picture. (b) preoperative, intra oral radiography. (c) Stabilization with splints

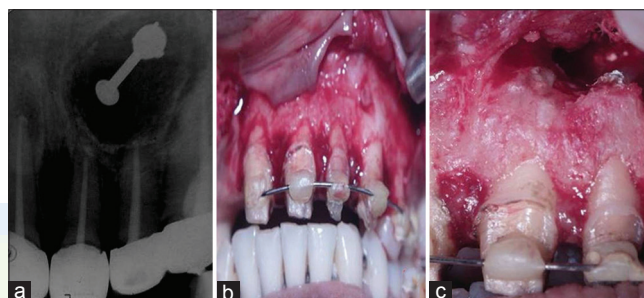


Figure 2: (a) Completion of root canal treatment. (b) Full thickness flap elevated. (c) Root end sealing completed using mineral trioxide aggregate

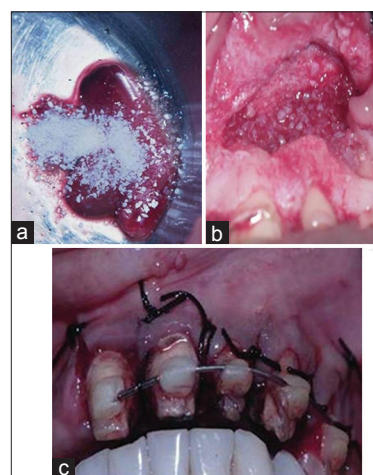


Figure 3: (a) Hydroxy apatite nano crystalline graft material mixed with platelet rich fibrin (PRF). (b) Hydroxy apatite nano crystalline graft material along with PRF by placing over the defect. (c) Sutures placed

The patient was scheduled for surgery at the following visit, prior to which a complete hemogram was done, with all the parameters within normal limits. The surgery was performed under aseptic conditions. Under local anaesthesia (1:2,00,000 adrenaline, Neon Lab, India),

a full thickness mucoperiosteal flap was reflected by a sulcular incision extending from Sdistal to tooth no. 11 to the distal aspect of tooth no. 23 [Figure 2b]. The defect was debrided and a large periapical cystic lesion was observed with complete loss of labial cortical plate. The enucleated cystic specimen was sent for histo-pathologic examination. Following which a no. 702 tapered fissure bur (SS White burs) was used to the root end of teeth no. 21 and 22. Gray mineral trioxide aggregate (MTA) (ProRoot MTA; Dentsply, Tulsa, OK, USA) was used as the root end filling material [Figure 2c].

Platelet rich fibrin was prepared in accordance with the protocol developed by Freymiller and Aghaloo^[9] from 20 mL of blood drawn from the patient's antecubital vein and centrifuged (REMI centrifuge machine Model R-8c) for 10 min under 3000 revolutions (approximately 400 g) per min to obtain the PRF.

Commercially available HA nanocrystal granules (Biograft HA, Nano, IFGL Bioceramics Ltd., India) were mixed with PRF and placed into the defect [Figure 3a and b]. The flap was approximated and sutured with a 3–0 black silk suture material (Sutures India Pvt. Ltd, Karnataka, India) [Figure 3c]. The patient was prescribed antibiotic (Augmentin – 625 mg BD for 5 days) along with anti-inflammatory (Combiflam Tab, Sanofi India TID for 5 days). The patient was also advised to use 0.2% chlorhexidine gluconate mouth rinse for a week. At recall appointment after 1-week the sutures were removed; revealing an uneventful healing process.

The patient was reviewed at 6 months and 1-year period during which there were no reports of pain, inflammation, or discomfort [Figure 4a]. The follow-up visits, included routine intraoral examinations and professional plaque control measures. Radiographic examination revealed satisfactory bone fill [Figure 4b and c]. The patient was

completely satisfied with the results of the treatment and is still on maintenance and recall schedule. The histopathology report confirmed the provisional diagnosis of an infected radicular cyst.

Discussion

The regeneration of bone after periapical surgery depends primary wound closure, angiogenesis of vessels, source of undifferentiated mesenchymal cells, space maintenance and stability of the wound.^[10] The most commonly used technique for regeneration involves the use of osseous grafts which aids in tissue or bone regeneration through a variety of mechanisms. HA has shown very good results with respect to periodontal and periapical bone regeneration. Literature review reported that a combination of HA and PRF resulted in greater pocket depth reduction, a gain in clinical attachment and better defect fill than PRF used alone.^[11] Thus, HA was selected, to enhance the effects of PRF by maintaining the space for tissue regeneration and osteoconductive effects in the bony defect area. Bone grafts alone without a blood clotting factor are unlikely to promote periapical wound healing.^[12] Biologically, blood clot is a better space filler than all bone grafting materials. A blood clot is the host's own biologic product which plays a major role in wound healing.^[13]

When PRF is used along with bone grafts, it offers several advantages like promoting wound healing, bone growth and maturation, graft stabilization, wound sealing, haemostasis and improving the handling properties of graft materials.^[13] The PRF is a concentrate of growth factors like platelet-derived growth factor (PDGF), transforming growth factor (TGF)-beta and insulin-like growth factor (IGF), which play a major role in wound healing.

In vivo application of PDGF increased bone regeneration in calvarial defects when a bio-absorbable membrane is used as a carrier.^[14] The growth factor TGF-stimulates bio-synthesis of type I collagen and induces deposition of bone matrix *in vitro*,^[15] but when applied with a biodegradable osteogenic material, bone growth around calvarial defects increased significantly.^[16] The IGF-I is synthesized and secreted by osteoblasts;^[17] stimulating bone formation by proliferation and differentiation.^[18] Since the surface of PRF membrane is smoother, it can cause superior proliferation of human cells, which enhances bone regeneration.^[19] The progressive polymerization mode of coagulation in PRF helps in the increased incorporation of the circulating cytokines into the fibrin meshes (intrinsic cytokines) which helps in wound healing by moderating the inflammation.^[20,21]

The advantages of PRF amongst others lies in its preparation; which is simple, easy, less time consuming and cost effective. As a by-product of patient's own blood,

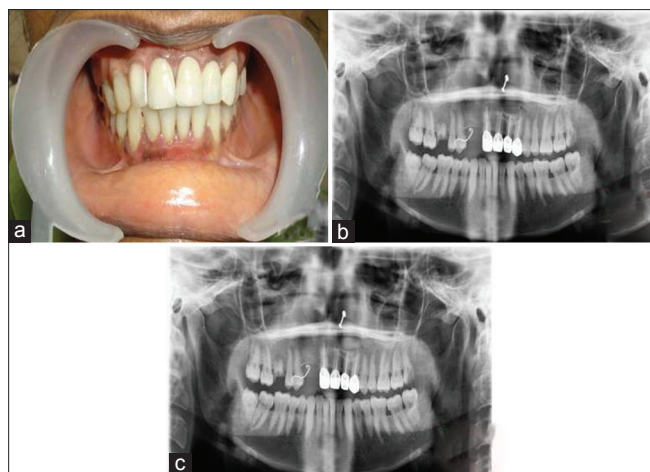


Figure 4: (a) Postoperative clinical picture. (b) 6 months follow-up orthopantomogram (OPG). (c) 1 year follow-up OPG

the chances of infectious diseases transmission are rare. It promotes a more efficient cell migration and proliferation. It also helps in haemostasis. The PRF prevents early invagination of undesired cells as interpositional material; eliminating the need for a separate barrier membrane at the time of closure.^[21] The PRF used in this case report has proven to be a favourable bone regeneration material along with an interpositional material. This eliminates the use of expensive bone grafts and barrier membranes, which makes the treatment cost for patients prohibitive. When compared to bone grafts, PRF has shown good results which enhance accelerate and organize bone regeneration.^[21]

References

- Sagit M, Guler S, Tasdemir A, Akf Somdas M. Large radicular cyst in the maxillary sinus. *J Craniofac Surg* 2011;22:e64-5.
- Shear M. Radicular and residual cysts. In: Bristol W, editor. *Cyst of the Oral Region*. 3rd ed. UK: John wright and son; 1992. p. 136-62.
- Martin SA. Conventional endodontic therapy of upper central incisor combined with cyst decompression: A case report. *J Endod* 2007;33:753-7.
- Bashutski JD, Wang HL. Periodontal and endodontic regeneration. *J Endod* 2009;35:753-7.
- American Academy of Periodontology. *Glossary of Periodontal Terms*. Chicago, Ill, USA: American Academy of Periodontology; 2001.
- Demiralp B, Keçeli HG, Muhtarogullar M, Serper A, Demiralp B, Eratalay K. Treatment of periapical inflammatory lesion with the combination of platelet-rich plasma and tricalcium phosphate: A case report. *J Endod* 2004;30:796-800.
- Carranza FA, Newman MG, Takei HH, Klokkevold PR. *Carranza's Clinical Periodontology*. 10th ed. Saunders, Elsevier publication St Louis Mo: Localized bone augmentation and implant site development; 2006. p. 1134.
- Del Corso M, Sammartino G, Dohan Ehrenfest DM. Re: Clinical evaluation of a modified coronally advanced flap alone or in combination with a platelet-rich fibrin membrane for the treatment of adjacent multiple gingival recessions: A 6-month study. *J Periodontol* 2009;80:1694-7.
- Freymler EG, Aghaloo TL. Platelet-rich plasma: Ready or not? *J Oral Maxillofac Surg* 2004;62:484-8.
- Boyapati L, Wang HL. The role of stress in periodontal disease and wound healing. *Periodontol* 2000 2007;44:195-210.
- Pradeep AR, Bajaj P, Rao NS, Agarwal E, Naik SB. Platelet-rich fibrin combined with a porous hydroxyapatite graft for the treatment of three-wall intrabony defects in chronic periodontitis: A randomized controlled clinical trial. *J Periodontol* 2012;83:1499-507.
- Laurell L, Gottlow J. Guided tissue regeneration update. *Int Dent J* 1998;48:386-98.
- Sunitha Raja V, Munirathnam Naidu E. Platelet-rich fibrin: Evolution of a second-generation platelet concentrate. *Indian J Dent Res* 2008;19:42-6.
- Chung CP, Kim DK, Park YJ, Nam KH, Lee SJ. Biological effects of drug-loaded biodegradable membranes for guided bone regeneration. *J Periodontol Res* 1997;32:172-5.
- Pfeilschifter J, Oechsner M, Naumann A, Gronwald RG, Minne HW, Ziegler R. Stimulation of bone matrix apposition *in vitro* by local growth factors: A comparison between insulin-like growth factor I, platelet-derived growth factor, and transforming growth factor beta. *Endocrinology* 1990;127:69-75.
- Arnaud E, Morieux C, Wybier M, de Vernejoul MC. Potentiation of transforming growth factor (TGF-beta 1) by natural coral and fibrin in a rabbit cranioplasty model. *Calcif Tissue Int* 1994;54:493-8.
- Hock JM, Centrella M, Canalis E. Insulin-like growth factor I has independent effects on bone matrix formation and cell replication. *Endocrinology* 1988;122:254-60.
- Baker NL, Carlo Russo V, Bernard O, D'Ercole AJ, Werther GA. Interactions between bcl-2 and the IGF system control apoptosis in the developing mouse brain. *Brain Res Dev Brain Res* 1999;118:109-18.
- Gassling V, Douglas T, Warnke PH, Açil Y, Wiltfang J, Becker ST. Platelet-rich fibrin membranes as scaffolds for periosteal tissue engineering. *Clin Oral Implants Res* 2010;21:543-9.
- Dohan DM, Choukroun J, Diss A, Dohan SL, Dohan AJ, Mouhyi J, *et al.* Platelet-rich fibrin (PRF): A second-generation platelet concentrate. Part III: Leucocyte activation: A new feature for platelet concentrates? *Oral Surg Oral Med Oral Pathol Oral Radiol Endod* 2006;101:e51-5.
- Toffler M, Toscano N, Holtzclaw D, Corso MD, Dohan Ehrenfest DM. Introducing Choukron's platelet rich fibrin (PRF) to the reconstructive surgery. *Milieu J Implant Adv Clin Dent* 2009;1:21-30.

How to cite this article: Pradeep K, Kudva A, Narayanamoorthy V, Cariappa KM, Saraswathi MV. Platelet-rich fibrin combined with synthetic nanocrystalline hydroxy apatite granules in the management of radicular cyst. *Niger J Clin Pract* 2016;19:688-91.

Source of Support: Nil, **Conflict of Interest:** None declared.