

# Giant pubertal prolactinoma: Complete resolution following short term cabergoline treatment

A Oguz, D Tuzun, M Sahin, K Gul

Department of Endocrinology and Metabolism, Faculty of Medicine, Kahramanmaras Sutcu Imam University, Kahramanmaras, Turkey

## Abstract

Prolactinomas are the most common pituitary tumors but rarely seen in adolescent males. There is no indication for surgery both in micro- and macro-adenomas unless an urgent treatment is necessary. First line treatment is always medical with dopamine agonists. In this report, we presented a patient with pubertal arrest and giant prolactinoma that disappeared in a short time with cabergoline treatment.

**Key words:** Cabergoline, giant prolactinoma, pubertal arrest

**Date of Acceptance:** 06-Apr-2016

## Introduction

Prolactinomas are the most common pituitary tumors and constitute about 40% of all pituitary adenomas. Microadenomas are more common than macroadenomas and are more frequent among women. However, giant prolactinomas are rare tumors and more common among men.<sup>[1]</sup> Pituitary tumors are classified as “giant adenoma” if they are larger than 4 cm.<sup>[2]</sup> It is difficult to remove the giant tumors surgically, and biochemical cure rarely occurs.<sup>[3,4]</sup> Dopamine agonists are the preferred treatments for prolactinomas and surgery should only be preferred if there is resistance or intolerance to the drug therapy or if there is vision loss or advanced invasion.<sup>[1]</sup> The treatment should be started with a dopamine agonist regardless of the size of the adenoma in cases with macroprolactinoma.<sup>[5]</sup>

Hyperprolactinemia may cause impotence and hypogonadism in adult men, and rarely leads to pubertal arrest and delayed puberty among adolescents.<sup>[6]</sup>

In this report, we present a case with a giant prolactinoma admitted to our clinic with the symptom of pubertal arrest that disappeared in a short time with dopamine agonist therapy primarily.

## Case Report

A 19-year-old male admitted to the endocrinology clinic 9 months ago with the complaints of headache, short stature, and delayed development of his secondary sex characteristics. In his physical examination at the time of admission, his height was 158 cm (<3<sup>rd</sup> percentile), weight was 61.9 kg (97<sup>th</sup> percentile), body mass index was 23.9 kg/m<sup>2</sup>, axillary-pubic hair growth was at tanner stage 1, right and left testis volume of 8 mL, and penis size was 6.5 cm. In laboratory examinations, hyperprolactinemia (>200 ng/mL), hypogonadotropic hypogonadism,

### Address for correspondence:

Dr. A Oguz,  
Kayseri Road 10 km Avsar Campus. Kahramanmaras Sutcu Imam University, 46100, Kahramanmaras, Turkey.  
E-mail: aytenoguz@windowslive.com

### Access this article online

#### Quick Response Code:



Website: [www.njcponline.com](http://www.njcponline.com)

DOI: 10.4103/1119-3077.188693

This is an open access article distributed under the terms of the Creative Commons Attribution-NonCommercial-ShareAlike 3.0 License, which allows others to remix, tweak, and build upon the work non-commercially, as long as the author is credited and the new creations are licensed under the identical terms.

**For reprints contact:** [reprints@medknow.com](mailto:reprints@medknow.com)

**How to cite this article:** Oguz A, Tuzun D, Sahin M, Gul K. Giant pubertal prolactinoma: Complete resolution following short term cabergoline treatment. *Niger J Clin Pract* 2016;19:685-7.

**Table 1: The results of the endocrine tests at baseline and follow-up**

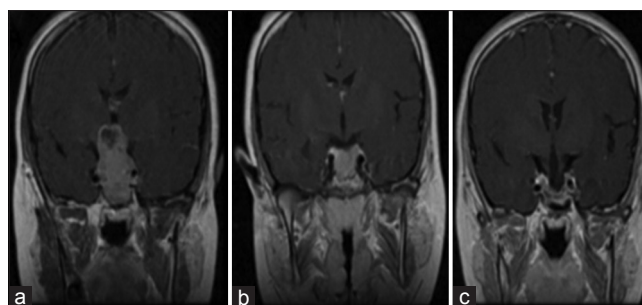
Parameters	Baseline	3 <sup>rd</sup> month	9 <sup>th</sup> month	Normal reference range
TSH	2.9	1.62	0.53	0.4-4.2 uIU/mL
FT4	0.73	1.12	1.09	0.8-2.7 ng/dL
Cortisol	18.2	15.3	9.95	<20 µg/dL
Prolactin	>200	19	7.2	3-23.2 ng/mL
FSH	0.87	2.7	2.2	1-15 mIU/mL
LH	0.61	1.2	2.1	1-18 mIU/mL
Total testosterone	13.05	283	417.68	280-1100 ng/dL
Growth hormone	0.29	0.6	0.29	1-16 ng/mL
IGF-1	73.6	210	240	202-433 ng/dL

TSH=Thyroid stimulating hormone; FT4=Free thyroxine; FSH=Follicle-stimulating hormone; LH=Luteinizing hormone; IGF-1=Insulin-like growth factor-1

and secondary hypothyroid were detected [Table 1]. In the pituitary magnetic resonance imaging (MRI); macroadenoma, 40 mm × 26 mm × 23 mm in size in the pituitary region, filling the suprasellar cistern, and invading the optic chiasm, sphenoid, and cavernous sinus [Figure 1a] was observed. The visual field examination revealed a defect in the nasal part. The patient was informed about apoplexy and dopamine agonist therapy (0.5 mg/week) was started for prolactinoma and thyroid hormone therapy (100 mcg/day) for secondary hypothyroidism. The dose of the dopamine agonist was increased by 0.5 mg/week, reaching 2 mg/week. In the 3<sup>rd</sup> month control visit, the patient's height was 161.5 cm (<3<sup>rd</sup> percentile); axillary-pubic hair growth at tanner stage 2, right and left testis volume of 10 mL, and penis size of 6.5 cm. In addition, it was observed that prolactin and total testosterone levels were normalized and the macroadenoma in the pituitary region observed in the pituitary MRI had regressed to 21 mm × 15 mm × 22 mm in size [Figure 1b]. At the 9<sup>th</sup> month control visit, the patient, who was continuing dopamine agonist therapy, was observed to have a height of 165 cm (3<sup>rd</sup> percentile), right and left testis volume of 18 mL, penis size of 12 cm, axillary pubic hair growth at tanner stage 3, normal biochemical parameters, and the macroadenoma in the pituitary MRI had disappeared completely [Figure 1c]. There were no vision defects detected in the visual field examination. The patient is still being followed at our clinic and is continuing dopamine agonist therapy.

## Discussion

Prolactinomas are the most common pituitary adenomas and are often observed in women. On the other hand, giant prolactinomas are rare and invasive pituitary tumors and are often observed in men.<sup>[2]</sup> We presented a male with a giant prolactinoma of 4 cm in size, consistent with



**Figure 1:** (a) The pituitary magnetic resonance image at the time of diagnosis of the case, (b) after 3 months under cabergoline treatment. (c) After 9 months under cabergoline treatment

those published in the literature. In dopamine agonist resistant patients, surgical debulking can be performed to these tumors, either to prevent pituitary apoplexy or to ensure rapid optic decompression and to improve vision.<sup>[7]</sup> However, surgical resection is difficult in giant tumor cases due to the suprasellar, parasellar, and infrasellar extension of the tumor and biochemical cure is rare even if the tumor is fully removed. Many patients continue with drug therapy following surgery.<sup>[4,8]</sup> Besides, the possibility of developing hypopituitarism post-operatively should also be considered in giant adenoma cases. Currently, surgical interventions in prolactinoma cases are recommended only in cases resistance to dopamine agonists.<sup>[9]</sup>

Long-acting dopamine agonists normalize the prolactin levels in micro- and macro-adenomas with high efficiency in both males and females.<sup>[1,10]</sup> Numerous studies demonstrated that dopamine agonist therapy is an effective and safe treatment method for male patients with giant prolactinoma. Shimon *et al.* started cabergoline therapy as the initial treatment to 10 of the 12 patients with giant prolactinoma, where 83% had successfully suppressed prolactin levels, 90% had significant reduction in tumor size, 89% had improvements in visual field, and 67% had improvements in gonadal dysfunction.<sup>[1]</sup> Gillam *et al.* normalized prolactin levels of the 49 (65%) patients with giant prolactinoma on dopamine agonist therapy (bromocriptine or cabergoline) in their study.<sup>[9]</sup> The mean cabergoline dose in these studies varied between 1.5 mg/week to 3.5 mg/week. In cases with giant prolactinoma, higher doses than the conventional were often needed for biochemical and clinical responses.<sup>[11]</sup> In the light of literature, cabergoline therapy was started as the initial treatment despite the presence of the giant prolactinoma and visual field defect. Prolactin and testosterone levels were normalized with the dose of 2 mg/week cabergoline. Improvement in visual field and reduction in tumor size were seen. In cases with macroprolactinomas, cabergoline dose should be slowly increased until the effective dose is reached. The goal of slow dose titration is to minimize the rare side effects of high-dose cabergoline therapy such as cerebrospinal fluid leak,<sup>[12]</sup> herniation of tumor to chiasm, and pituitary

apoplexy. In order to prevent the potential side effects of cabergoline therapy, we reached the effective dose of 2 mg/week by increasing the initial dose of 0.5 mg/week by 0.5 mg each week.

Symptoms of prolactinoma may vary depending on the age and sex of the patient. While it may cause hypogonadism, loss of libido, infertility, erectile dysfunction, and gynecomastia in adult males,<sup>[13,14]</sup> also it can rarely cause delayed puberty, pubertal arrest, or short stature in children and adolescents.<sup>[6]</sup> The case presented here had the initial symptoms of short stature and pubertal arrest. The main cause of hyperprolactinemia-related hypogonadism is gonadotropin releasing hormone (GnRH) inhibition. However, it can be observed in cases with giant prolactinomas due to the pressure of the tumor as well. Somatotroph and gonadotroph cells are most susceptible pituitary cells to damage due to sellar compression.<sup>[15]</sup> We believe that hypogonadism causing pubertal arrest can occur by the effect of the compression of the tumor and also with the inhibition of GnRH due to hyperprolactinemia. This is based on our observation of improvement in hypogonadism in addition to tumor regression and prolactin normalization following dopamine agonist therapy.

Giant prolactinomas are rarely observed tumors in adolescents. Nevertheless, it should be considered in cases presenting with short stature and pubertal arrest. As in microprolactinomas, dopamine agonists should be the first line treatment in giant prolactinomas, too. In adolescent males, due to the difficulties in removing the tumor surgically and the risk of hypopituitarism, we believe that the first line treatment should be dopamine agonist therapy regardless of the size of the adenoma.

**Financial support and sponsorship**  
Nil.

## Conflicts of interest

There are no conflicts of interest.

## References

1. Shimon I, Benbassat C, Hadani M. Effectiveness of long-term cabergoline treatment for giant prolactinoma: Study of 12 men. *Eur J Endocrinol* 2007;156:225-31.
2. Shrivastava RK, Arginteanu MS, King WA, Post KD. Giant prolactinomas: Clinical management and long-term follow up. *J Neurosurg* 2002;97:299-306.
3. Serri O, Rasio E, Beauregard H, Hardy J, Somma M. Recurrence of hyperprolactinemia after selective transsphenoidal adenectomy in women with prolactinoma. *N Engl J Med* 1983;309:280-3.
4. Ciric I, Mikhael M, Stafford T, Lawson L, Garces R. Transsphenoidal microsurgery of pituitary macroadenomas with long-term follow-up results. *J Neurosurg* 1983;59:395-401.
5. Melmed S, Casanueva FF, Hoffman AR, Kleinberg DL, Montori VM, Schlechte JA, *et al.* Diagnosis and treatment of hyperprolactinemia: An endocrine society clinical practice guideline. *J Clin Endocrinol Metab* 2011;96:273-88.
6. Kamel N, Uysal AR, Cesur V, Erdogan G, Baskal N. Normal growth and pubertal development during bromocriptine therapy in two patients with prolactinoma. *Endocr J* 1995;42:581-6.
7. Molitch ME. Dopamine resistance of prolactinomas. *Pituitary* 2003;6:19-27.
8. Davis JR, Sheppard MC, Heath DA. Giant invasive prolactinoma: A case report and review of nine further cases. *Q J Med* 1990;74:227-38.
9. Gillam MP, Molitch ME, Lombardi G, Colao A. Advances in the treatment of prolactinomas. *Endocr Rev* 2006;27:485-534.
10. Colao A, Vitale G, Cappabianca P, Briganti F, Ciccarelli A, De Rosa M, *et al.* Outcome of cabergoline treatment in men with prolactinoma: Effects of a 24-month treatment on prolactin levels, tumor mass, recovery of pituitary function, and semen analysis. *J Clin Endocrinol Metab* 2004;89:1704-11.
11. Bevan JS, Webster J, Burke CW, Scanlon MF. Dopamine agonists and pituitary tumor shrinkage. *Endocr Rev* 1992;13:220-40.
12. Leong KS, Foy PM, Swift AC, Atkin SL, Hadden DR, MacFarlane IA. CSF rhinorrhoea following treatment with dopamine agonists for massive invasive prolactinomas. *Clin Endocrinol (Oxf)* 2000;52:43-9.
13. Carter JN, Tyson JE, Tolis G, Van Vliet S, Faiman C, Friesen HG. Prolactin-screening tumors and hypogonadism in 22 men. *N Engl J Med* 1978;299:847-52.
14. Segal S, Yaffe H, Laufer N, Ben-David M. Male hyperprolactinemia: Effects on fertility. *Fertil Steril* 1979;32:556-61.
15. Salenave S, Trabado S, Maione L, Brailly-Tabard S, Young J. Male acquired hypogonadotropic hypogonadism: Diagnosis and treatment. *Ann Endocrinol (Paris)* 2012;73:141-6.