

Simultaneous oroantral communication closure, sinus-lifting, and particulate bone grafting and immediate dental implant perforation

MI Kara, S Yanik¹, F Sari², C Buyukkurt³

Department of Oral and Maxillofacial Surgery, Faculty of Dentistry, Izmir Katip Çelebi University, ³Department of Oral and Maxillofacial Surgery, Faculty of Dentistry, Şifa University, Izmir; Departments of ¹Oral and Maxillofacial Surgery and ²Prosthodontics, Faculty of Dentistry, Gaziantep University, Gaziantep, Turkey

Abstract

The aim of this paper is to introduce an alternative technique for the treatment of oroantral communication (OAC). Closure of OAC, reconstruction of the posterior maxilla by sinus-lifting procedure with a particulate xenograft, and implant insertion were performed in the same operation. A lateral antral approach was used in the sinus elevations. The sinus membranes were elevated gently around the perforation area, and then a barrier membrane was used to close the perforation. Care was taken not to extend the perforation. Next, the maxillary sinus was filled with a particulate xenograft, and an implant was inserted simultaneously. Forty-seven and 40 months of clinical and radiographic follow-up revealed healthy and functional implants in the teeth area.

Key words: Immediate implant, membrane perforation, oroantral communication, sinus-lift

Date of Acceptance: 10-Oct-2015

Introduction

Oroantral communication (OAC) is described as a connection between the oral cavity and the maxillary sinus.^[1,2] Previously, OAC and oroantral fistula (OAF) repair using different techniques such as the buccal or palatal mucosa, buccal fat pad, and closure biocompatible materials were generally sufficient for conventional prosthetic treatment. However, these techniques cannot support the bone required for rehabilitation of the posterior maxilla with dental implants, and they require sinus-lifting procedures

long after the OAC or OAF closure. This method can lead to problems for patients facing a prolonged treatment period and several operations.^[1-4]

To provide alternative methods, we present herein two case reports using the following techniques: Simultaneous OAC or OAF closure and sinus floor augmentation for further chin implant surgery;^[4] zygomatic bone^[1] or anterior iliac crest grafts;^[3] and immediate insertion of a dental implant into an internally repaired and sinus-lifted site.^[2] In addition to these protocols, we present two new techniques: Reconstruction of the posterior maxilla with simultaneous sinus-lift and particulate bone grafting, and implant insertion in the presence of an OAC.

Address for correspondence:

Dr. S Yanik,
Department of Oral and Maxillofacial Surgery, Faculty of Dentistry,
Gaziantep University, P.K. 27310 Şehitkamil, Gaziantep, Turkey.
E-mail: saimyanik@hotmail.com

Access this article online

Quick Response Code: 	Website: www.njcponline.com
	DOI: 10.4103/1119-3077.183300
	PMID: 27251977

This is an open access article distributed under the terms of the Creative Commons Attribution-NonCommercial-ShareAlike 3.0 License, which allows others to remix, tweak, and build upon the work non-commercially, as long as the author is credited and the new creations are licensed under the identical terms.

For reprints contact: reprints@medknow.com

How to cite this article: Kara MI, Yanik S, Sari F, Buyukkurt C. Simultaneous oroantral communication closure, sinus-lifting, and particulate bone grafting and immediate dental implant perforation. Niger J Clin Pract 2016;19:556-8.

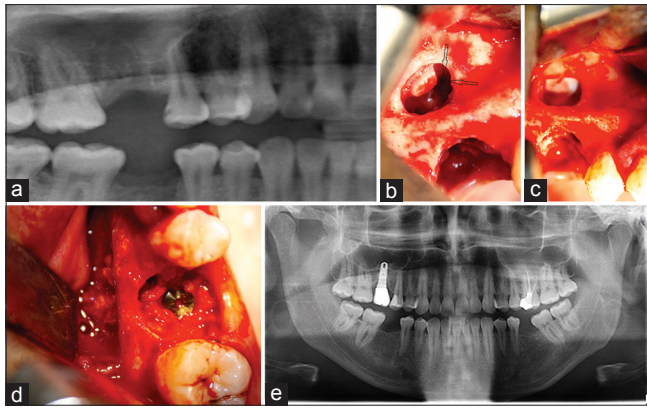


Figure 1: (a) Panoramic radiographic appearance of extraction tooth socket of Case 1, (b) Sinus mucosa was gently reflected without increasing membrane perforation (arrow), (c) Resorbable collagen membrane was placed on the perforation site, (d) The floor of the sinus was grafted with a particulate xenograft and an implant was placed, (e) Panoramic radiographic view, 47 months after surgery

Case Reports

Case 1

A 27-year-old man was referred to our clinic for implant-supported restoration. A clinical examination revealed significant crown destruction, and radiolucency was observed around the roots related to the sinus. After achieving local anesthesia, the tooth was traumatically luxated and removed without deformation of the external socket walls or interdental septa [Figure 1a]. A sinus perforation was noted at the tooth socket; while carrying out the Valsalva maneuver, it was found that the air exited via the extraction socket. Therefore, we decided to perform maxillary sinus augmentation, OAC closure, and implant installation in the same operation.

Additional local anesthesia was administered, and a trapezoidal buccal mucoperiosteal advancement flap was created. The flap was elevated, and a buccal window was created in the lateral wall of the maxillary sinus. During the operation, the sinus membrane was elevated gently around the perforation area; care was taken not to extend the perforation [Figure 1b]. A barrier membrane was used to close the perforation [Figure 1c]. Next, the particulate graft material was inserted into the space between the maxillary alveolar process and the sinus mucosa. The implant was performed simultaneously [Figure 1d].

The patient was monitored weekly for the first postoperative month and monthly for the following 6 months to identify any complications, such as acute or chronic sinusitis or graft contamination. A clinical and radiographic follow-up at 47 months revealed a healthy and functional implant in the area of tooth number 16 [Figure 1e]. There was no radiographic evidence of bone loss or clinical signs

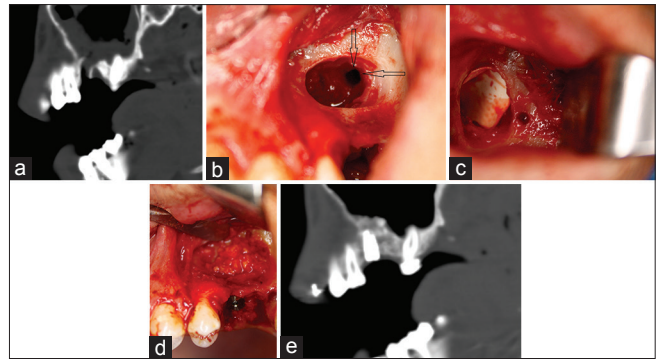


Figure 2: (a) Radiographic appearance of extraction tooth socket of Case 2, (b) Sinus membrane was elevated carefully around the perforation area, (c) A barrier membrane was used to close the perforation, (d) The particulate graft and a dental implant was performed simultaneously, (e) Postoperative computed tomographic appearance, 40 months after surgery

of mobility or suppuration, and the maxillary sinus were healthy.

Case 2

A 22-year-old male patient was referred to our clinic by the patient's general dental practitioner due to OAC caused by the extraction of the upper first left molar. The Valsalva maneuver was positive, and the radiologic findings showed a radiolucent image located in the alveolar bone between the second upper left premolar and the left upper right molar [Figure 2a]. Closure of the communication was planned, along with augmentation of the maxillary sinus and placement of an endosseous dental implant.

The same protocol was performed on the same day as the first case [Figure 2b-d]. A clinical and radiographic follow-up at 40 months revealed a healthy and functional implant in the area of tooth number 26 [Figure 2e]. There was no radiographic evidence of bone loss or clinical signs of mobility or suppuration. No complications related to the maxillary sinus were observed during the follow-up period.

Discussion

One of the major problems with repairing OACs and OAFs with only soft tissue coverage techniques, especially in large bone defects, is that they cannot meet the requirement of complex hard tissue (bone) when further implant rehabilitation is considered.^[2] In addition, the possible fusion of the oral mucosa and sinus membrane leads to an impossible elevation of the Schneiderian membrane without tearing it.^[5]

The drawbacks associated with the surgical closure of OACs and OAFs with only soft tissue techniques has resulted in the development of several alternative treatment modalities by some researchers, including third molar transplantation,

hydroxyapatite blocks, bioabsorbable root analog, and the bone sandwich technique. Intraoral or extraoral autogenous bone grafts are also preferred by some practitioners.^[1-3,6]

To facilitate subsequent dental implant operations, researchers have described simultaneous OAC or OAF closure and sinus floor augmentation.^[1-4,7] Pernerrocha-Diago^[8] reported a case, wherein the communication was closed by means of a bone graft harvested from the wall of the sinus (zygomatic bone). Ogunsalu *et al.*^[2] described a new sandwich technique for bone regeneration in the sinus floor area after the unintentional creation of an OAC, in order to eventually place an endosseous implant.

Numerous surgical procedures^[1,8,9] to cope with membrane perforations were demonstrated in literature such as the use of a fibrin adhesive, suturing, bioabsorbable membrane, and block graft. Although treatment is not, generally, necessary for small perforations, using a resorbable collagen membrane is recommended perforations between 5 and 10 mm. Whereas, autogenous bone block graft is recommended to use in larger perforations (perforation size >10 mm). Because of membrane perforations were not exceed 10 mm, and considering drawbacks of autogenous bone block graft, and bone blocks may require fixed with miniplates or bone screws, we did not prefer to use bone block, and we used resorbable collagen membrane for repairing membrane perforations.

Conclusion

These case reports demonstrated that simultaneous OAC closure, sinus-lifting, and implant insertion using particulate graft material can be performed during the same operation. This technique offers some advantages, including the elimination of further surgery and a shorter total treatment time. Complications related to autogenous grafts, such as limited availability, the need for a second surgical procedure, postoperative morbidity, high surgery costs, prolonged pain,

and possible neural damage in the donor site, are eliminated. However, this method might also present some drawbacks, such as the need for sufficient alveolar bone for primary implant stability and vestibuloplasty due to a sliding buccal flap. To conclude, we expect that these cases present a useful technique for reconstructing the posterior maxilla with simultaneous lift and bone grafting, as well as implant insertion, in the presence of OAC.

Financial support and sponsorship

Nil.

Conflicts of interest

There are no conflicts of interest.

References

1. Lee BK. One-stage operation of large oroantral fistula closure, sinus lifting, and autogenous bone grafting for dental implant installation. *Oral Surg Oral Med Oral Pathol Oral Radiol Endod* 2008;105:707-13.
2. Doobrow JH, Leite RS, Hirsch HZ. Concomitant oroantral communication repair and immediate implant placement: A five-year case report. *Implant Dent* 2008;17:176-81.
3. Ogunsalu C. Dental implant therapy in the treatment of an oroantral communication after exodontia. *Implant Dent* 2005;14:232-6.
4. Punwutikorn J, Waikakul A, Pairuchvej V. Clinically significant oroantral communications – A study of incidence and site. *Int J Oral Maxillofac Surg* 1994;23:19-21.
5. Visscher SH, van Minnen B, Bos RR. Closure of oroantral communications using biodegradable polyurethane foam: A feasibility study. *J Oral Maxillofac Surg* 2010;68:281-6.
6. Ahmed MS, Askar NA. Combined bony closure of oroantral fistula and sinus lift with mandibular bone grafts for subsequent dental implant placement. *Oral Surg Oral Med Oral Pathol Oral Radiol Endod* 2011;111:e8-14.
7. Cortes D, Martinez-Conde R, Uribarri A, Eguia del Valle A, Lopez J, Aguirre JM. Simultaneous oral antral fistula closure and sinus floor augmentation to facilitate dental implant placement or orthodontics. *J Oral Maxillofac Surg* 2010;68:1148-51.
8. Peñarrocha-Diago M, García B, Gomez D, Balaguer J. Zygomatic bone graft for oral-antral communication closure and implant placement. *J Oral Implantol* 2007;33:305-9.
9. Kara MI, Kirmali O, Ay S. Clinical evaluation of lateral and osteotome techniques for sinus floor elevation in the presence of an antral pseudocyst. *Int J Oral Maxillofac Implants* 2012;27:1205-10.