

Progressive myelopathy, a consequence of intra-thecal chemotherapy: Case report and review of the literature

BF Chukwu, IF Ukekwe¹, OU Ezenwosu, CO Ani², AN Ikefuna, IJ Emodi

Departments of Pediatrics and ¹Pathology, University of Nigeria, Enugu Campus, ²Department of Radiology, Enugu State University Teaching Hospital, Enugu, Nigeria

Abstract

Intra-thecal chemotherapy is a recognized therapy for hematological malignancies such as acute lymphoblastic leukemia (ALL). Despite the advantage of these drugs in treating or preventing central nervous system disease, they are not without complications. The authors describe a 12-year-old girl with ALL, who developed progressive myelopathy following intra-thecal administration of cytosine arabinoside. Initial presentation was urine and fecal retention that progressed to paraplegia, and finally encephalopathy. magnetic resonance imaging of the neuroaxis showed T2-weighted foci of increased signal intensity within the substance of the cervical cord indicative of myelopathy. Physicians should be wary of this rare complication of intra-thecal chemotherapy.

Key words: Cytosine arabinoside, intra-thecal, myelopathy

Date of Acceptance: 09-Sep-2014

Introduction

Systemic and intra-thecal chemotherapy are used in the treatment and prophylaxis of hematological cancers such as acute lymphoblastic leukemia (ALL) as well as some solid tumors such as Burkitt's lymphoma. Drugs used for intra-thecal therapy are methotrexate (MTX), cytosine arabinoside, and/or corticosteroid singly or in combination.^[1]

However, intra-thecal chemotherapy is not without adverse effects. Effects on the brain include acute, subacute or chronic encephalopathy, seizures, headache and chemical meningitis.^[1] Focal neurologic features such as hemiparesis, aphasia and cortical blindness may also be isolated features.^[2] In the spinal cord, progressive myelopathy is a rare, but devastating side-effect of intra-thecal chemotherapy.^[3]

The onset of these adverse events may range from few hours to several weeks and may occur following one or more doses of the drugs^[4] even at standard doses.^[5]

Address for correspondence:

Dr. BF Chukwu,
Department of Pediatrics, University of Nigeria,
Enugu Campus, Enugu, Nigeria.
E-mail: barth.chukwu@unn.edu.ng

The authors present a 12-year-old girl who developed progressive myelopathy after 4 weeks of commencement of intra-thecal cytosine arabinoside.

Case Report

A 12-year-old female was referred to our center with a 6 weeks history of fever, generalized body weakness, pallor, weight loss and recurrent blood transfusion of 5 weeks duration. Significant findings on examination were a moderate pallor, pyrexia (37.9°C), generalized lymphadenopathy and massive hepato-splenomegaly. Her weight was 40 kg and height, 153 cm. She was subsequently diagnosed of ALL type 1, from peripheral blood film and bone marrow film analysis.

She was admitted, stabilized and commenced on remission induction chemotherapy using the National Guideline

Access this article online

Quick Response Code:



Website: www.njcponline.com

DOI: 10.4103/1119-3077.151806

PMID: 25772933

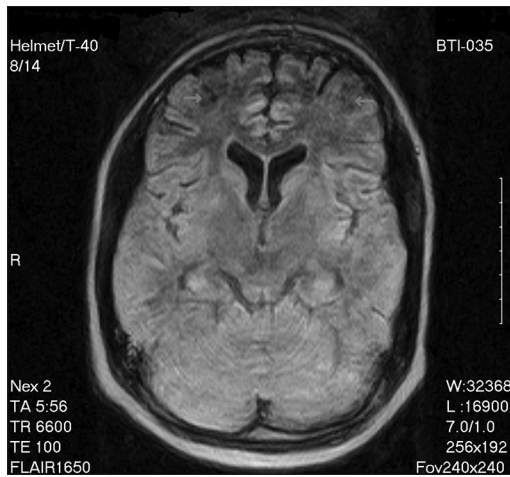


Figure 1: Magnetic resonance images of patient’s neuroaxis

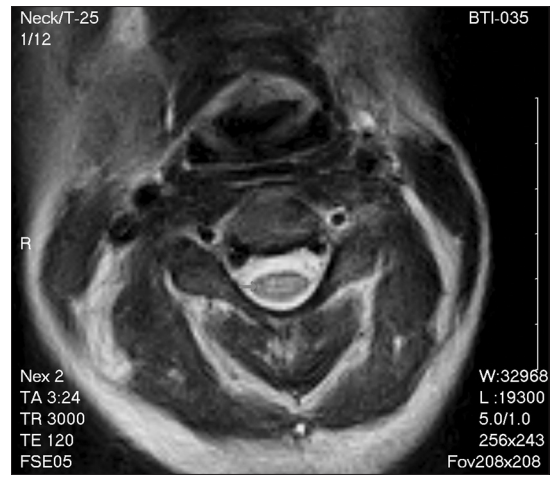

Figure 2: Axial FLAIR cranial images showing increased white matter signal low intensity in frontal lobes (white arrow)

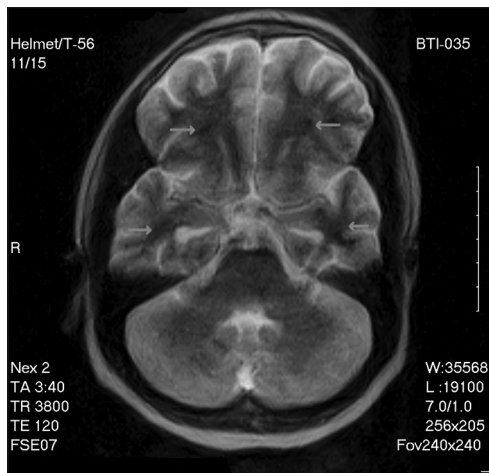


Figure 3: White matter signal hypointensity on axial FSE T2-W (white arrows)

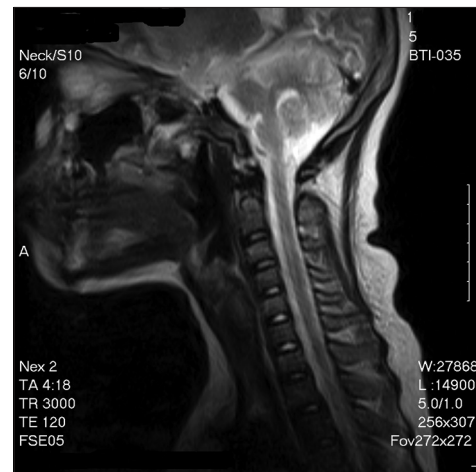

Figure 4: Sagittal FSE T2-W cervical spine image showing signal heterogeneity of the cord substance (red arrows)

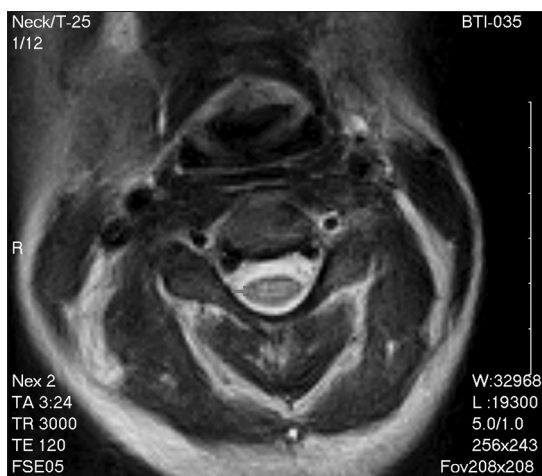

Figure 5: Axial FSE T2-W cervical spine image showing signal heterogeneity of the cord substance (red arrows)

Protocol consisting of intravenous cyclophosphamide, vincristine (oncovin), cytosine arabinoside and oral prednisolone at appropriate doses, as well as weekly

prophylactic intra-thecal cytosine arabinoside.^[6] Cerebrospinal fluid (CSF) was evaluated prior to this period and did not contain blasts at the inception of intra-thecal therapy. She was also commenced on antibacterial, antiviral and antifungal prophylaxis. She responded adequately to therapy with bone marrow remission achieved by the 4th week of systemic therapy. She gained significant weight (2.5 kg) and was discharged home and booked for further courses of chemotherapy.

However, following her 4th intra-thecal therapy, she began to complain of urine and fecal retention. The 5th course of intra-thecal therapy was given 1-week after, using 50 mg of cytosine arabinoside and 25 mg of hydrocortisone. Further chemotherapy was withdrawn for 2 months because of low hematological indices. Patient was receiving “filgrastin” a granulocyte colony stimulating factor, “Astymin” a micronutrient supplement and also continued prophylactic antibiotic, antifungal and antiviral agents during this period. However, when she presented for the next cycle of therapy, she complained of weakness and tingling sensation in the

lower limbs and was found to have flaccid paraplegia, although sensation was not affected. Subsequent intra-theal therapy was suspended, and radiological evaluation of the neuroaxis was done using BTI 0.35 Tesla magnetic resonance imaging (MRI). Fast spin echo T2-weighted and fluid attenuation inversion recovery sequences showed diffuse low signal intensity within the white matter area of the frontal and temporal lobes. Images of the cervical spine revealed subtle alteration in cord signal with presence of multiple scattered high signal foci within the cord on T2-weighted images and corresponding hypointense foci on T1-weighted images. T2-weighted gradient recalled echo images confirmed the signal changes in the spinal cord.

The MRI findings suggested myelopathy which would either be chemotherapy-induced or due to ascending myelitis. Figures 1-5 show the magnetic resonance images of patient's neuroaxis. She was immediately commenced on oral dexamethasone since CSF analysis did not reveal any features of inflammation nor metastasis, and there was no history or clinical features suggestive of viral infection.

Her condition continued to deteriorate and by the 1st week of the 3rd month, she became quadriplegic, with the loss of neck control and subsequently by the end of the month, she had generalized convulsions with labored breathing and died a few days later. We could not do postmortem examination because parents refused to give consent.

Discussion

Intra-theal chemotherapy is used for therapeutic or prophylactic treatment of hematological malignancies such as ALL or lymphomas such as Burkitt's lymphoma.^[7] These malignancies are known to have sanctuary sites in the central nervous system (CNS)^[8] and therefore, if no measure is instituted to treat or prevent CNS involvement, can result in severe adverse consequences. However, intra-theal chemotherapy is not without adverse events.

Myelopathy following intra-theal chemotherapy (especially from MTX and cytosine arabinoside, [Ara-C]) is a rare but devastating complication. Progressive myelopathy may occur with intra-theal MTX, Ara-C, steroids as single drugs or in combination of two or three drugs (triple therapy).^[9]

The risk factors include extensive meningeal disease, CNS irradiation, childhood and old age.^[10] Other risk factors include the dose of the cytotoxic drug, diluents used during administration and frequency of administration.

Our patient did not have any features of meningeal disease clinically, or in the CSF cytology nor did she receive any CNS irradiation. Her age (adolescent) also did not impose

any risk as she is closer to adulthood physiologically. The dose and frequency of drug administration were according to the National guideline for cancer chemotherapy.^[6]

The pathology identified was that of necrotizing myelopathy whose symptoms may start as bladder or rectal dysfunction and progress from paraplegia through quadriplegia to encephalopathy. Our patient's symptoms started as urinary and fecal retention and progressed from paraplegia through quadriplegia with loss of neck control and eventually involved the brain stem resulting in labored breathing with subsequent cerebral involvement that resulted in generalized seizures. There may be no sensory loss as noted in our patient and case series by Bay *et al.*^[4]

The onset of myelopathy may be after a few hours to several weeks and may occur after first or many doses of intra-theal administration of the drugs.^[11] From the case, series of six patients reported by Bay *et al.*,^[4] all the patients developed bladder and rectal sphincter dysfunction within 12 h of administration of intra-theal therapy.

There are no pathognomonic MRI features of chemotherapy-induced myelopathy. Some authors have reported areas of diminished signal intensity in the spinal cord^[11] while others like Lu *et al.*^[12] have reported areas of signal hyperintensity as seen in our patient. Lu *et al.*^[12] noted their findings to be similar to findings in subacute combined degeneration of the cord due to Vitamin B12 deficiency. It is, therefore, imperative that serum Vitamin B12 assay be done to exclude Vitamin B12 deficiency as a differential diagnosis. We did not assay Vitamin B12 in our patient because of lack of this facility, although our patient's blood film did not show macrocytic erythrocytes. Patients who are receiving MTX should also have their folate level assayed because MTX therapy leads to lack of folate derivatives used as methyl transferase cofactor, resulting in reduced methyl transferase activity and reduced S-adenosylmethionine level. S-adenosylmethionine is the only methyl donor in the CNS and reduction in its level will lead to an elevated level of homocysteine that is toxic to neural cells. Our patient did not receive MTX either systemically or intra-theally.

Myelopathy due to intra-theal chemotherapy may be reversible or progressive, which subsequently leads to encephalopathy and death.^[13] There is still no treatment for chemotherapy-induced myelopathy, although report by Ackerman *et al.*^[14] noted a partial response in a 54-year-old woman with severe MTX induced myelopathy after substituting MTX with S-adenosylmethionine, folic acid, cyanocobalamin and methionine. Jakobson *et al.*^[15] have also reported response to CSF exchange in two children who were accidentally given overdose of intra-theal MTX while

Finkelstein *et al.*^[16] reported the success of CSF exchange and use of intra-thecal leucovorin and dexamethasone in the emergency treatment of intra-thecal MTX overdose in a 34-year-old man with aggressive diffuse malignant lymphoma.

Conclusion

Chemotherapy with cytosine arabinoside can cause spinal cord dysfunction in children with ALL and should be kept in mind as a causative factor in bladder and rectal sphincter dysfunction in patients receiving intra-thecal chemotherapy. Pediatric oncologists and other health workers charged with care of cancer patients should be aware of this rare, but devastating complication of intra-thecal cytosine arabinoside and should be able to recognize it as early as possible. More research is required in developing appropriate therapy to treat this life-threatening complication that is hitherto unreported in our environment.

References

1. Kwong YL, Yeung DY, Chan JC. Intrathecal chemotherapy for hematologic malignancies: Drugs and toxicities. *Ann Hematol* 2009;88:193-201.
2. Martino RL, Benson AB 3rd, Merritt JA, Brown JJ, Lesser JR. Transient neurologic dysfunction following moderate-dose methotrexate for undifferentiated lymphoma. *Cancer* 1984;54:2003-5.
3. Beretta F, Sanna P, Ghielmini M, Marini G, Cavalli F. Paraplegia following intrathecal chemotherapy. *Schweiz Med Wochenschr* 1996;126:1107-11.
4. Bay A, Oner AF, Etlik O, Yilmaz C, Caksen H. Myelopathy due to intrathecal chemotherapy: Report of six cases. *J Pediatr Hematol Oncol* 2005;27:270-2.
5. Ozön A, Topaloglu H, Cila A, Günay M, Cetin M. Acute ascending myelitis and encephalopathy after intrathecal cytosine arabinoside and methotrexate in an adolescent boy with acute lymphoblastic leukemia. *Brain Dev* 1994;16:246-8.
6. FMOH. National Guideline on Cancer Chemotherapy. 2009. pg. 7-9.
7. Moser AM, Adamson PC, Gillespie AJ, Poplack DG, Balis FM. Intraventricular concentration times time (C x T) methotrexate and cytarabine for patients with recurrent meningeal leukemia and lymphoma. *Cancer* 1999;85:511-6.
8. David GT, Bleyer A. The leukemias. In Behrman RE, Kliegman RM, Jenson HB, Stanton BF, editors. *Nelson Textbook of Pediatrics*. Philadelphia: Saunders Elsevier; 2007. p. 459.1
9. Schlegel U. Central nervous system toxicity of chemotherapy. *Eur Assoc Neurooncol Mag* 2011;1:25.
10. Resar LM, Phillips PC, Kastan MB, Leventhal BG, Bowman PW, Civin CI. Acute neurotoxicity after intrathecal cytosine arabinoside in two adolescents with acute lymphoblastic leukemia of B-cell type. *Cancer* 1993;71:117-23.
11. McLean DR, Clink HM, Ernst P, Coates R, al Kawi MZ, Bohlega S, *et al.* Myelopathy after intrathecal chemotherapy. A case report with unique magnetic resonance imaging changes. *Cancer* 1994;73:3037-40.
12. Lu CH, Yao M, Liu HM, Chen YF. MR findings of intrathecal chemotherapy-related myelopathy in two cases: Mimicker of subacute combined degeneration. *J Neuroimaging* 2007;17:184-7.
13. von der Weid NX, de Crousaz H, Beck D, Deonna T, Miklossy J, Janzer RC. Acute fatal myeloencephalopathy after combined intrathecal chemotherapy in a child with acute lymphoblastic leukemia. *Med Pediatr Oncol* 1991;19:192-8.
14. Ackermann R, Semmler A, Maurer GD, Hattingen E, Fornoff F, Steinbach JP, *et al.* Methotrexate-induced myelopathy responsive to substitution of multiple folate metabolites. *J Neurooncol* 2010;97:425-7.
15. Jakobson AM, Kreuger A, Mortimer O, Henningsson S, Seidel H, Moe PJ. Cerebrospinal fluid exchange after intrathecal methotrexate overdose. A report of two cases. *Acta Paediatr* 1992;81:359-61.
16. Finkelstein Y, Zevin S, Heyd J, Bentur Y, Zigelman Y, Hersch M. Emergency treatment of life-threatening intrathecal methotrexate overdose. *Neurotoxicology* 2004;25:407-10.

How to cite this article: Chukwu BF, Ukekwe IF, Ezenwosu OU, Ani CO, Ikefuna AN, Emodi IJ. Progressive myelopathy, a consequence of intrathecal chemotherapy: Case report and review of the literature. *Niger J Clin Pract* 2015;18:432-5.

Source of Support: Nil, **Conflict of Interest:** None declared.