

## GASTROINTESTINAL INJURIES FOLLOWING BLUNT ABDOMINAL TRAUMA IN CHILDREN.

\*LB Chirdan, \*AF Uba, \*\*OO Chirdan

*Departments of \*Surgery, and \*\*Community Health, Jos University Teaching Hospital, Jos, Nigeria.*

### ABSTRACT

**Purpose:** Gastrointestinal (GI) injuries in children following blunt abdominal trauma is rare; early diagnosis and treatment is important for good outcome. The purpose of this report is to describe the management problems encountered in children with GI injuries following blunt abdominal trauma.

**Patients and Methods:** From January 1996 June 2006, 168 children were treated at our centre for abdominal trauma. Twenty three had GI injuries, 19 were due to blunt trauma while four were due to penetrating trauma. We retrospectively reviewed the clinical data of the 19 children that had GI injuries as a result of blunt abdominal trauma to document the presentation, clinical features, diagnosis and outcome.

**Results:** There were 19 patients, 14 were boys, and five were girls. The median age at presentation was nine years (range 1.5 15 years). Road traffic accident was responsible for injuries in 10, fall from heights in six and assault in two children. In one child the cause of injury was not recorded. Most children presented late and at presentation over 80% had abdominal signs. Diagnosis was mainly by physical examination supported by plain abdominal x-ray in 15 children. All 19 children had laparotomy. There were a total of 23 injuries. Gastric and duodenal injuries accounted for one each. Most of the injuries were in the jejunum and ileum (10 perforations, two contusions with one mesenteric haematoma and one mesenteric tear). There was one caecal perforation and six colonic injuries, one of which was associated with intraperitoneal rectal injury. Five children had other associated injuries (three splenic injuries, one renal injury, one bladder contusion associated with long bone fractures and one severe closed head injury). Treatment included segmental resection with end to end anastomosis, wedge resection with anastomosis, exteriorizations stomas, simple excision of the perforation and closure in two layers (gastric perforation). The total mortality was four (21.1%), two of them due to associated injuries.

**Conclusion:** Gastrointestinal injuries due to blunt abdominal trauma pose a management challenge. Management based on decisions from serial clinical examinations and simple tests without recourse to advance imaging techniques may suffice.

**Key Words:** Gastrointestinal injury, Blunt abdominal trauma, children. (Accepted 3 April 2007)

### INTRODUCTION

GI injuries due to blunt trauma in children still poses a diagnostic and management challenge because objective evaluation of the abdomen by noninvasive imaging modalities or diagnostic peritoneal lavage (DPL) has not proven reliable in the diagnosis of bowel injuries in children<sup>1-4</sup>. The management problems in the developing world are further compounded by late presentation and financial constraints<sup>5</sup>. The purpose of this report is to describe our experience with gastrointestinal injuries following blunt abdominal trauma in children and to stress the main diagnostic and management challenges faced in our centre. An algorithm for the management of suspected gastrointestinal injuries in children following blunt abdominal trauma based on clinical examinations and simple laboratory test is proposed.

### PATIENTS AND METHODS

In the period January 1996-June 2006, 19 children were managed for gastrointestinal injuries from blunt abdominal trauma at the Jos University Teaching Hospital. During the same period 118 were managed for blunt abdominal trauma.

### RESULTS

The age and sex distribution of the 19 children are shown in table 1. The median age was nine years (range 1.5-15 years). Fourteen were boys and five were girls. Road traffic accident (RTA) was the cause of gastrointestinal injury in 10 children. Six children sustained injuries due to fall from mango tree. Two children were involved in assault during civil disturbances while in one child the cause of the injury was not documented.

The main presenting features are summarized in table 2. Five children presented within 24 hours of injury, nine presented within 72 hours while the remaining five presented after three days of injury. One was

---

Correspondence: Dr L. B Chirdan  
Email:lohfab@yahoo.com

referred four days after injury.

All the children had abdominal pain and tenderness. Abdominal distension and vomiting was present in 12 children at the time of presentation. Five children were in shock due to associated injuries. A plain abdominal radiograph was done in 15 children. Free peritoneal fluid was present in four; the others have non-specific features such as dilated bowel with fluid levels. Ten children had ultrasound scan of the abdomen after resuscitation. In four there was free peritoneal fluid. None had a Computed Tomography scan as this was unavailable. Four children had diagnostic peritoneal lavage (DPL). In two DPL was positive while in the other two, the result was inconclusive.

A management workup of the children included an immediate resuscitation with intravenous fluid, nil per oral, urethral catheterization and broad spectrum antibiotics and surgery after adequate resuscitation. There were a total of 23 gastrointestinal injuries in the 19 children. The site of injury was stomach (1), duodenum (1), jejunioleal (12), large bowel (caecum 1, colon/rectum 7).

Five children had other associated intra-abdominal organ injuries ( Splenic injury in three, renal injury in one and bladder contusion in one). Three children had associated retroperitoneal haematoma, three had head injury and two had long bone fractures.

All the 19 children had laparotomy 8 hrs 3 days after presentation.

The gastric perforation was about 2cm long close to the greater curvature. The perforation was debrided and closed in layers. One child had a duodenal contusion that was associated with pancreatic injury. The duodenum and pancreas were left undisturbed as there was no retroperitoneal haematoma around the duodenum. Ten children had jejunioleal injury. Eight of them had perforations, three were multiple (one of them had grade III splenic injury) so segmental bowel resection with end to end anastomosis was done and total splenectomy in one of them; five had single perforation for which wedge resection with anastomosis was done. Two children had contusion of the small bowel in association with mesenteric haematoma and grade IV splenic injury in one and longitudinal mesenteric tear in the other. The mesenteric tear was repaired and total splenectomy for grade IV splenic injury was done. One child had a caecal perforation for which a tube caecostomy was done. Six children had colonic injury. In four the injury was on the descending colon for which exteriorization was done and the ends brought out as stomas. The stomas were closed after three months in two patients; the other two children died shortly after operation. Two children had

sigmoid colon injuries, one of them associated with intraperitoneal rectal injury. In one the perforation was closed primarily while in the other child with associated rectal injury, sigmoid divided colostomy was done and stoma closed after four months.

Post-operative complications included four superficial wound dehiscence, two with atelectasis and two with post-operative adhesive intestinal obstruction that were managed non-operatively. Four children died, two had colonic perforation, one had small bowel perforation and head injury and the other child had small bowel injury with associated grade IV splenic injury.

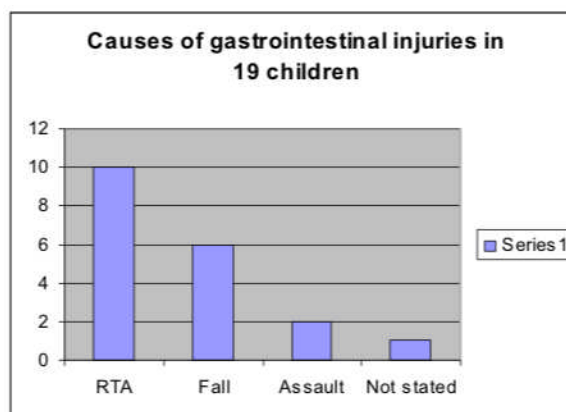
**Table 1: Age And Sex Distribution Of 19 Children With Gastrointestinal Injury From Blunt Abdominal Trauma**

	Boys	Girls	Total
>1	-	-	-
1-4 years	3	-	3
5-9 years	6	4	10
10 – 15 years	5	1	6
<b>Total</b>	<b>14</b>	<b>5</b>	<b>19</b>

**Table 2: Clinical Features At Initial Presentation Of 19 Children With Gastrointestinal Injuries Due To Blunt Abdominal Trauma**

Feature	No
Abdominal pain	19
Abdominal tenderness	19
Abdominal distention	12
Vomiting	12
Pallor	8
Fever	7
Shock	5
Abdominal bruises	1
Haematemesis	1

**Fig 1: Causes Of Gastrointestinal Injuries In 19 Children**



RTA= Road Traffic Accident

## DISCUSSION

Trauma is becoming a major killer of children in developing countries as infection and malnutrition are being controlled<sup>6</sup>. Blunt trauma is the more common mechanism of injury in children and GI injuries though uncommon poses difficult diagnostic challenges. Initial clinical evaluation may not identify these injuries and repeated examination is necessary. CT imaging has become the mainstay for diagnosis in blunt abdominal trauma especially in children with DPL playing a secondary role<sup>7,8</sup>. Imaging has made the diagnosis of solid abdominal organ injury (liver, spleen, kidney, and pancreas) accurate and allowed development of non operative management in the majority of children. Non operative management of these injuries is not only appropriate but is also safe. Although most children with solid organ injuries do not have associated intestinal injury, the diagnosis of gastrointestinal tract injury in this setting can be very difficult<sup>9</sup>. The diagnosis of bowel injury in blunt abdominal trauma without associated solid organ injury, but with associated extremity, central nervous system, and other injuries in children is also difficult. This has focused attention on developing more reliable objective criteria for the diagnosis of hollow viscus injury to avoid delays and potential increases in morbidity and mortality.

In this report, GI injuries were seen in 16% of children with blunt abdominal trauma. Most series reported 1.4% - 10%<sup>10-13</sup>, though in Zaria, Northern Nigeria, 23% of children with blunt abdominal trauma have gastrointestinal injuries<sup>5</sup>. Most of our patients were involved in Road Traffic Accidents but falls from heights accounted for a significant number of injuries. Other forms of injuries like bicycle handle injuries and sports injuries are rare in our environment compared to other reports<sup>10</sup>. This may be due to the fact that few of our children are involved in recreational activities like bicycle riding and sports. Due to vague features on presentation, diagnosis of GI injuries may be delayed<sup>11,13</sup>, however meticulous serial physical examination of these children on presentation is imperative to making a decision on them<sup>14</sup>. Moreover, serial examinations may reveal abdominal signs especially in perforations. In our setting where presentation to tertiary health care facilities is late, most of them usually have abdominal signs at presentation as in this report and other reports<sup>5,13</sup>. DPL done in four patients was positive in two. DPL is mainly used to diagnose intraperitoneal haematoma in children with blunt trauma, and is unreliable in the diagnosis of bowel injuries in children<sup>7,8</sup>. In our setting where patients present late, the diagnostic yield of DPL may be high.

Of 15 children that had plain abdominal radiograph at presentation in this report the radiograph showed free peritoneal air in only four. This is similar to other reports where pneumoperitoneum is not easily demonstrated on plain abdominal radiograph in this group of patients<sup>5, 10, 13</sup>. Abdominal USS has been available in our centre since early to mid 1990s and has been used since then for the evaluation of patients with abdominal trauma that are haemodynamically stable. The major drawback of USS is that it is non-specific in the evaluation of children with blunt abdominal trauma<sup>15</sup>; however it could show evidence of peritoneal fluid collection. The mortality in this report is 21.1%, two of them directly due to associated injuries while two could be attributable to delayed presentation. More so in some of them abdominal bruising as in one of the patients in this report may indicate severe injury. The implication of these findings especially for developing countries with limited diagnostic facilities and most often delayed presentation is that children with gastrointestinal injuries, especially those with bowel perforations can be diagnosed and laparotomy performed without resort to advanced imaging techniques which are unavailable in most centres. The management of gastrointestinal injuries in children due to blunt abdominal trauma poses a major challenge to clinicians especially those practicing in developing countries. A high index of suspicion is needed to make early diagnosis if the high morbidity and mortality are to be avoided.

## REFERENCES

1. **Bensard DD, Beaver BL, Besner GE, Cooney DR.** Small bowel injury in children after blunt abdominal trauma: is diagnostic delay important? *J Trauma.* 1996;41:476-483.
2. **Moss RL, Musemeche CA.** Clinical judgment is superior to diagnostic tests in the management of pediatric small bowel injury. *J Pediatr Surg.* 1996;31:1178-1182
3. **Sherck JP, Oakes DD.** Intestinal injuries missed by computed tomography. *J Trauma.* 1990;30:1-7.
4. **Schimpl G, Schmidt B, Sauer H.** Isolated bowel injury in blunt trauma in childhood. *Eur J Pediatr Surg.* 1992;2:341-344
5. **Ameh EA, Nmadu PT.** Gastrointestinal injuries from Blunt Abdominal Trauma in Children. *E Afr Med J* 2004;81:194-197

6. **Nordberg E.** Injuries in Africa: a review. *East Afr Med J*, 1994;71:339-345
7. **Ulman I, Avanoglu A, Ozcan C, Demircan M, Ozok G, Erdener A.** Gastrointestinal perforations in children: a continuing challenge to nonoperative treatment of blunt abdominal trauma. *J Trauma*. 1996;41:110-113
8. **Jamieson DH, Babyn PS, Pearl R.** Imaging gastrointestinal perforation in pediatric blunt abdominal trauma. *Pediatr Radiol*. 1996;26:188-194.
9. **Nance ML, Peden GW, Shapiro MB, Kamder DR, Rotondo MF, Schwab CW.** Solid viscus injury predicts major hollow viscus injury in blunt abdominal trauma. *J Trauma*. 1997;43:618-623
10. **Ciftci AO, Tanyel FC, Salman, AB, Buyukpamukcu N, Hicsonmez A.** Gastrointestinal tract perforation due to blunt abdominal trauma. *Pediatr Surg Int* 1998;13:259-264
11. **Brown RA, Bass GH, Rode H, Miller AJW, Cywes S.** Gastrointestinal tract perforation in children due to blunt abdominal trauma. *Br J Surg* 1992;79:522-524
12. **Galifer RB, Forgues D, Mourregot A, Guibal MP, Allal H, Mekki M, Rizet D.** Blunt Traumatic injuries of the Gastrointestinal and Biliary Tract in Childhood. Analysis of 16 cases *Eur J Pediatr Surg* 2001;11:230-234
13. **Canty TH Sr, Canty TG Jr, Brown C.** Injuries of the gastrointestinal tract from blunt abdominal trauma in children: a 12 year experience at a designated trauma centre. *J Trauma* 1999;46:234-240.
14. **Jerby BL, Attorri RJ, Morton D JR.** Blunt intestinal injury in children: the role of physical examination. *J Pediatr Surg* 1997;32:580-584.
15. **Holmes JF, Brant WE, Bond WF, Sokolove PE, Kuppermann N:** Emergency department ultrasonography in the evaluation of hypotensive and normotensive children with blunt abdominal trauma. *J Pediatr Surg*, 2001;36:968-973.