

POST-PARTUM INFARCTION OF AN AXILLARY BREAST CASE REPORT

S N C Anyanwu, J C Orakwe, U Ezomike
Ace Specialist Hospital, Onitsha, Nigeria

ABSTRACT

We present a case of post-partum infarction in an axillary Breast. We believe arterial insufficiency in the enlarging breast associated with pregnancy might have contributed

infiltration with few lymphocytes, plasma cells and macrophages. There were also mammary duct ectasia and periductal fibrosis.

INTRODUCTION

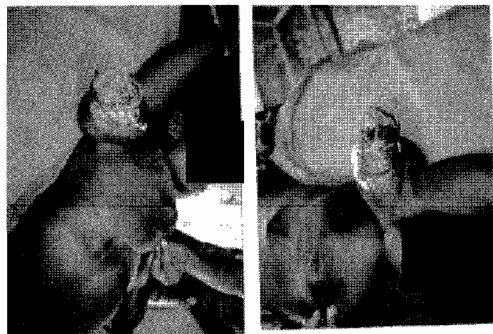
Pregnancy-induced infarction of the breast is a rare event^{1,2}. The few reports available have been on normally located breast tissue, or in fibroadenomas spontaneously³, or following aspiration⁴. Whereas axillary breasts may not be uncommon in the population spontaneous infarction affecting it is quite rare. We report a case of spontaneous post-partum infarction affecting an axillary breast

Key words: axillary breast, post-partum, infarction

CASE REPORT

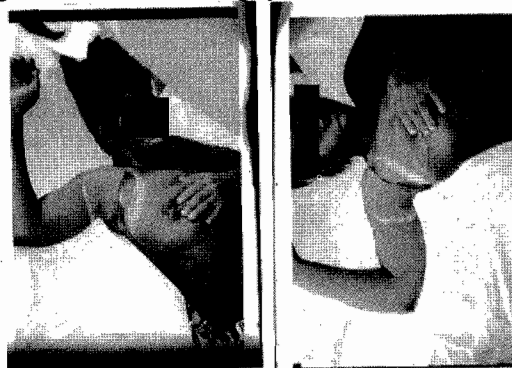S.O, a 31-year old, para-2, married lady was brought into the hospital in October, 2002 with a right axillary mass of 7 months duration. The mass had rapidly increased in size as her 2nd pregnancy progressed until it fungated through the skin in the immediate post-partum period. She had no similar complaints in her first pregnancy and resolutely denied presence of any axillary mass before the second pregnancy.

Figure 1: Pre-operative pictures



Examination revealed an otherwise healthy lady with a pendulous 19 X 18 cm fowl-smelling mass in the right axilla clearly separate from the right breast [fig 1,2]. The mass was firm, fairly mobile and ulcerated through the skin in the medial aspect [but not attached to the skin edge], and was free of attachment to deeper structures. An initial diagnosis of ulcerated cystosarcoma phylloides in an axillary breast was made. At surgery the mass was necrotic distally and was superficial to the subjacent clavipectoral fascia. Large draining veins contained thrombi. Post-operatively a wound infection healed rapidly. Histology revealed ulcerated breast tissue with disruption of normal lobular Architecture, massive eosinophilic

Figure 2 : one week after surgery



DISCUSSION

The axillary tail of Spence, probably occurring in a larger population of women than currently reported remains quiescent in high proportion. Occasionally the axillary breast tissue enlarges markedly during pregnancy or lactation⁵ and may become symptomatic with pain and engorgement as reported by Viera⁶. In a normally situated breast pregnancy-induced infarction of the breast have been postulated to result from organizing vascular thrombi². The case reported with venous thrombi may fit this model but it is difficult to exclude spontaneous arterial insufficiency as the enlarging breast tissue overgrew its blood supply. The reasons for occurrence in a second pregnancy instead of first are unknown. Excluding carcinoma pre-operatively in this patient was relatively easy on clinical grounds as despite the fungation the mass was never attached to skin. Physicians should bear in mind these uncommon presentations in patient care.

REFERENCES

1. Jimenez JF, Ryals RO, Cohen C. Spontaneous breast infarction associated with pregnancy presenting as a palpable mass. *J. Surg. Oncol.* 1986; 32 (3): 174-8
2. Lucey JJ. Spontaneous infarction of the breast. *J Clin. Pathol.* 1975; 28(12): 937-43
3. Matias-Guiu X, Calabuig R, Badia F, Serra J, La Calle J P. Spontaneous infarcts in fibroadenomas of the breast. *Curr. Surg.* 1988; 45 (4): 277-9
4. Dashpande KM, Dashpande AH, Raut WK, Lele VR, Bobhate SK. Diagnostic difficulties in spontaneous infarction of a fibroadenoma: case report. *Diagn. Cytopathol.* 2002; 26(1): 26-8

Correspondence: Prof S N C Anyanwu
Email :sncanyanwu@yahoo.com

5. **Bhattacharaya P.** Pregnancy with huge bilateral hypertrophic axillary tail of the breast: Case report. Br. J Obstet. Gynaecol. 1983; 90 (9) 874-5
6. **Viera AJ.** Breast-feeding with ectopic axillary breast Tissue. Mayo Clin. Proc. 1999; 74(10): 1021-2