

## PARASITIC LEIOMYOMA: A DIAGNOSTIC DILEMMA. A CASE REPORT

\* I Okoro \*\*N.Ododo, \*\*\*R Egejuru

Departments of \*Surgery, \*\*Obstetrics and Gynaecology and \*\*\*Pathology  
Imo State University Teaching Hospital, Umuna Orlu, Federal Medical Centre Owerri  
Imo State, Nigeria

### ABSTRACT

Leiomyomata (uterine fibroids) are the most common tumours of the female pelvis. Presentation of most cases of fibroids are usually straightforward making diagnosis and management easy. However, when they undergo various kinds of pathologic changes, they pose both diagnostic and management difficulties.

This article presents a rare case of a large degenerated parasitic leiomyoma in the peritoneal cavity deriving its blood supply from the omentum and attached to a normal looking uterus by a narrow avascular stalk. Ultrasound, x-ray and physical examination did not help with the diagnosis. It was at laparotomy that the diagnosis was made and later confirmed by histological examination.

**Key words:** Parasitic leiomyoma, pathologic changes, uterus, recurrence. (Accepted 25 October 2006)

### INTRODUCTION

Leiomyomata (uterine fibroids) are the most common tumours of the female pelvis<sup>1</sup>. About 20% of all women have one or more leiomyomata present in the uterus at death<sup>1</sup>. When a subserous fibroid becomes adherent to other structures, especially the omentum they obtain their blood supply from such structures and the uterine pedicle either disappears completely or becomes avascular. The tumour becomes known as "parasitic or ectopic leiomyoma"<sup>2,3</sup>. When this occurs the presentation is no longer as straightforward as that of the fibroid that is still attached to the uterus<sup>4</sup>. Imaging studies such as Magnetic Resonance Imaging (MRI) and Ultrasonography aid in the diagnosis of uterine fibroids, but in some circumstances such as the case presented they can be misleading or may not help to ascertain the diagnosis<sup>4</sup>. In the developing countries, especially in centers that lack trained personnel, but have imaging equipment such as ultrasound machines, the quality of result from such people could be misleading, thereby making accurate diagnosis difficult. A case report of a large degenerated parasitic fibroid that was not diagnosed correctly because of its peculiarities is hereby presented.

### CASE REPORT

A 34-year old woman, para 2, all alive, presented to the surgical outpatient clinic of the General Hospital Owerri, In Nov 2004 with a six-year history of

in size since the onset. This was associated with early fullness during feeding and weight loss. She was having normal and regular menstrual cycles, the last being in October 2004. There was no associated vaginal discharge, no respiratory difficulties and gastrointestinal symptoms. She had had myometomy ten years before presentation (1994). She had an attempted laparotomy 1 year earlier in Lagos but was closed back because of adhesions and lack of courage on the part of the surgeon to continue with the surgery. Physical examination revealed a chronically ill-looking wasted patient. Her vital signs were normal and the chest clear.

The abdomen was grossly distended and shiny extending to the xiphisternum. Multiple masses were felt all over the abdomen. Some of the masses were firm and some cystic, no tenderness was elicited. Other organs could not be felt.

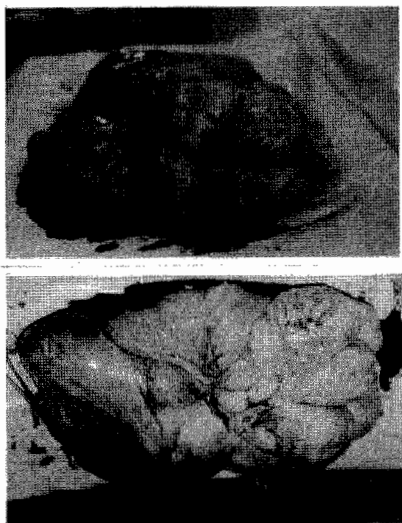
There was no ascites. The haemoglobin concentration was 10.6gm, white cell count, chest x-ray and urinalysis were all normal. Abdomino pelvic ultrasound was reported as "massive network of cystic-like spongy meshwork involving the entire peritoneal area. The uterus, ovaries, spleen, liver and pancreas are all normal". A working diagnosis of a mesenteric mass was made based on the above ultrasound report.

At laparotomy a multi-lobulated mass densely adherent to the anterior abdominal wall and omentum was seen. It derived its blood supply from the omentum

---

Correspondences: Dr I Okoro  
Email clarif2002@yahoo.com.

Figure 1: Shows the excised huge multilobulated mass. Some areas are cystic while others are fleshy.




It was attached to the fundus of a normal looking uterus by a thin avascular stalk. The intestines were pushed to the upper half of the abdomen. All other organs including the ovaries were normal. The mass was completely excised and weighed 7.2 kg. She made an uneventful recovery. The histological report read thus:

**Macroscopy:** Specimen consists of a huge multilobulated mass measuring 26x23x17cm Cut section shows grayish fleshy surface with peripheral cystic spaces containing gelatinous material. Also observed are foci of calcifications.

**Microscopy:** Representative histological sections show closely packed interlacing bundles of smooth muscle fibers with foci of cystic and hyaline degeneration consistent with Leiomyoma with degenerative changes.

Figure 2: Histological section showing closely packed interlacing bundles of smooth muscles fibres with foci of cystic and hyaline degeneration consistent with Leiomyoma with degenerative changes



## DISCUSSION:

Leiomyomata are a major cause of visit to the gynaecologist<sup>1</sup> and in most cases the diagnosis is straightforward but when they undergo pathological changes they pose diagnostic and management difficulties<sup>4</sup>. Our patient falls into the latter group. When a subserous leiomyoma outgrows its blood supply from the uterus it acquires new blood supply from the structures it is adherent to. Such structures include the omentum (as in this case), common iliac artery<sup>5</sup> and inferior mesenteric artery<sup>6</sup>. Its connection with the uterus is severely attenuated or completely severed. It is now known as "parasitic leiomyoma". In most reported cases of parasitic leiomyoma the diagnosis was made at surgery. Zaitoon<sup>7</sup> reported a case of retroperitoneal parasitic leiomyoma causing ureteric obstruction. At surgery it was found to be a parasitic fibroid. Some cases will require histological or immunohistochemical studies to confirm the diagnosis<sup>6</sup>.

Therefore, even though parasitic leiomyomata are rare tumours, they should be included in the differential diagnosis of pelvic or abdominal tumours in female subjects<sup>8</sup>. Furthermore, when the parasitic fibroid attains a large size it might outgrow its new blood supply and undergo further pathologic changes known as degeneration. The common types of degeneration are hyaline, cystic, mucoid and red<sup>9</sup>. In the case presented the degeneration was cystic in some areas and hyaline in others. Calcification was also observed.

Another important problem identified in this presentation is recurrent fibroid. Our patient had recurrence of fibroid within five years of the initial operation. This suggests the possibility that some tiny seedlings were not removed at the first operation or there was maintained stimulus to regrowth<sup>10,11</sup>. Thus surgeons should endeavour to be meticulous in removing all fibroids seen at the initial myomectomy no matter how small these fibroids are. This will drastically reduce the incidence of fibroid recurrence.

## REFERENCES

1. Theodoros A, Konstantinos D, Kalliopi P. Cystic degenerated angioleiomyoma mimicking ovarian pathology. *Acta Obstet Gynaecol Scand.*2001;80:863-865.
2. Pinkerton JHM, Stewart DB. Uterine fibroid. In Lawson JB, Sterwart DB(eds). *Obstetrics and Gynaecology in the Tropics and Developing countires.* London. Arnold Ltd,1983:385-397.

3. **Murase E, Siegelman ES, Outwafer EK, et al.** Uterine Leiomyomas; histopathological features, MR Imaging findings, differential diagnosis and treatment. *Radiographics* 1999; 19; 1179-97.
4. **Yarwood RL, Arroyo E.** Cystic degeneration of a uterine leiomyoma masquerading as a post-menopausal ovarian cyst. A case report. *J. Reprod. Med.* 1999;44(7):649-52
5. **Phupong V, Darojn D, Ultchaswadi P.** Parasitic Leiomyoma:a case report of an unusual tumour and literature review. *J.Med Assoc Thai.* 2003;86(10):986-90.
6. **Odofin O, Nasir N, Satyadas T, et al.** An unusual case of ectopic or "parasitic" leiomyoma excised by laparoscopic surgery. *Int. Surg.*2004;89(3): 161-3.
7. **Zaitoon MM.** retroperitoneal parasitic leiomyoma. *J. Urol* 1986;135(1) 130-1
8. **Buhimschi CS, Marvel RP.** Degenerated uterine leiomyoma mimicking a haematoma associated with gas formation. *Int. J. Gynaecol Obstet.* 2001;73;271-273.
9. **Finkler NJ, Friedman AJ.** Uterine Corpus. In **Ryan KJ.** Berkowitz RS, Barbieri R(eds). *Gynaecology: principles and practice.* 5<sup>th</sup> edition. Chicago. Year Book Medical Publishers. 1990:201-205.
10. **Whitefield CR.** Benign tumours of the uterus. In Whitefield CR (ed). *Dewhursts Textbook of Obstetrics and Gynaecology for Postgraduates.* 4<sup>th</sup> edition. Oxford Blackwell Science. 1995:738-46.
11. **Vollen hoven BJ, Lawrence AS, Healy DL.** Uterine fibroids: A clinical review. *Brit J. Obstet Gynaecol* 1990;97:285-298