

## ANEURYSMAL BONE CYST: A PRIMARY OR SECONDARY LESION?

B.D.O Saheeb, M.A Ojo, O.N Obuekwe

*Department of Oral And Maxillofacial Surgery and Pathology University of Benin Teaching Hospital,  
Benin City, Nigeria.*

### ABSTRACT

**Objectives:** To emphasize the origin of aneurysmal bone cyst as “primary” or “secondary” to other lesions of the jaws and 2. Report two cases of the cyst that illustrate its controversial origin in the hope that it will add to the literature on the subject in Africa..

**Report:** Two cases of aneurysmal bone cyst occurring in the mandible and maxilla are reported. One of the cysts that occurred in a 13-year-old was a primary lesion while the other in a 5-year-old was associated with a cementifying fibroma.

**Method:** The diagnoses of both lesions were confirmed by biopsy. The lesion that occurred in the 13-year-old was treated by curettage while the other in the 5-year-old was treated by excision under general anaesthesia respectively.

**Result:** While the lesion in the 13-year-old was haemorrhagic with 'welling up' of blood, the second lesion though haemorrhagic was not associated with this phenomenon. Both patients were transfused with 2 pints and 1 pint of blood respectively. There has not been recurrence of the lesions after two years post operatively.

**Conclusion:** Aneurysmal bone cyst can arise as a primary lesion or associated with a fibro-osseous lesion as demonstrated by these two cases. There is a need to serially section biopsy specimens of the cyst to detect co-existing lesions.

**Keywords:** Aneurysmal bone cyst, primary, secondary, lesion.

*(Accepted 27 November 2006)*

### INTRODUCTION

The aneurysmal bone cyst (ABC) is an uncommon lesion of the jaws, which is commonly found in children and young adults. It accounts for 1-2% of primary bone tumours biopsied.<sup>1</sup> It was Jaffe and Lichtenstein<sup>2</sup> who first recognised it as a distinct clinicopathologic entity in 1942 and suggested the term “Aneurysmal bone cyst”. Some authorities<sup>3</sup> believe that these authors first described it in 1950 while others<sup>4,5</sup> thought the first reported case of the cyst was by Bernier and Bhasker<sup>6</sup> in 1958

Since the cyst was recognised, a body of information has accumulated describing the clinical and histopathological as well as the pathogenesis of the cyst. Only few cases of “true” ABC are documented<sup>5</sup>. Some authors<sup>3,7,8</sup> have reported the hybrid nature of the cyst tending to arise in some pre-existing lesions. The lack of consensus surrounding the proper documentation of these cysts appears to hamper the ability to draw conclusions from available data<sup>4</sup>. ABC

occurs more frequently in the mandible than in the maxilla<sup>5,9,10</sup> with no significant predilection for either sex<sup>11</sup> although some authors<sup>5</sup> have recorded a higher number of affected females than males. It may rapidly expand the bone with pain and tenderness as uncommon features. The body and ramus of the mandible appear to be favoured sites. About 60-70 cases of the cyst have been reported in the jaws so far.<sup>1</sup> The study of this lesion is not common in West Africa and only four cases have been reported in Nigeria.<sup>12</sup> We report two cases of ABC occurring at the angle and ascending ramus of the mandible, and the other, at the primary palate in males under 20 years of age to: 1.emphasize the origin of the cyst as “primary” or “secondary” to other lesions of the jaws and 2 report two cases of the cyst that illustrate its controversial origin in the hope that it will add to the literature on the subject in Africa.

### CASE REPORT 1

A 13-year-old male was referred to the oral and maxillofacial surgery clinic of the University of Benin Teaching Hospital, Benin City, Nigeria with a swelling on the left side of the angle of the mandible of 2 year.

---

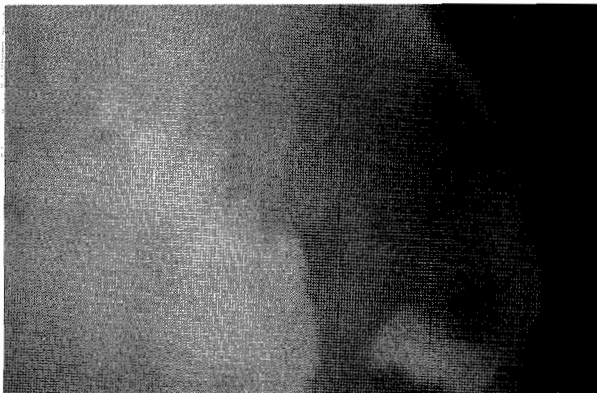
Correspondence: Dr B.D.O Saheeb  
Email: dauda2000@yaoo.com

duration. The patient claimed that the swelling developed gradually and it was painless and did not disturb oral functions. There was no history of trauma. There was no disturbance of hearing and parotid gland function. As the swelling progressively enlarged, the mother took patient to seek treatment in an herbal home. There was no relevant medical and family history.

On clinical examination, there was a firm, non-tender swelling on the left lower jaw, which extended from the ramus and angle of the mandible to the parasymphiseal region. It had a well-defined border and measured 8 cm x 11 cm. Intra-orally, there was no ulceration of the mucosa and the teeth were intact. A tentative diagnosis of central giant cell granuloma was made with aneurysmal bone cyst, ameloblastic fibroma and fibrous dysplasia considered as differential diagnoses.

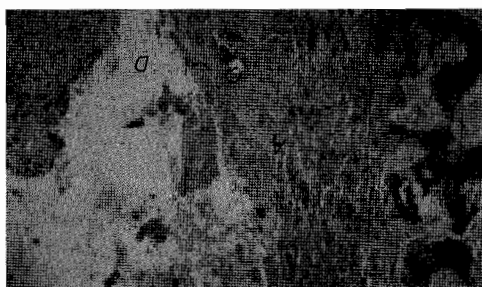Radiograph of lesion showed an osteolytic multilocular lesion expanding the cortex (figure 1).

**Figure 1: The radiograph of case one showing ballooning of the cortex, some radiopaque materials and multilocularity.**




There were some radiopaque masses scattered in the radiolucent areas. Aspiration of the cyst yielded dark blood. An intra-oral biopsy was taken from the lesion for histopathological examination. The histology report showed cellular fibrous connective tissue stroma with large blood filled spaces. There were areas of osteoid formation and focal collections of foreign body giant cells in the fibrous connective tissue wall (Figures 2 a and b).

**Figure 2A: (a) Low power. (A) fibrocellular connective tissue (B) osteoid formation (C) vascular spaces (D) cystic lumen (H & E x 128).**



**Figure 2B: (b). High power. (A) Giant cells (B) osteoid formation (C) fibrocellular connective tissue (H&Ex512)**



No evidence of neoplastic change. These features are consistent with that of aneurysmal bone cyst.

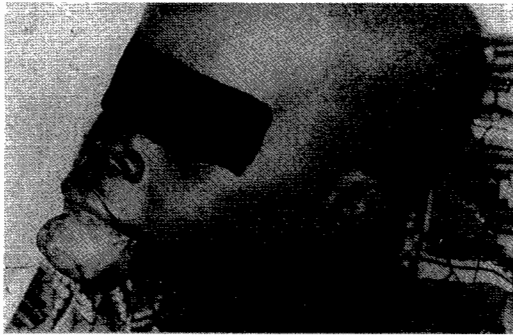The patient was operated upon under a general anaesthesia with oro-tracheal intubation and a haemoglobin concentration of 13.2 g/dl. An extra-oral incision was made at the right angle of the mandible extending for about 7 cm to completely expose the lesion. There was no difficulty in penetrating the cortex. On penetrating the cortex, there was a milk coloured gritty material in a cavity filled with blood. As the gritty material was carefully curetted, there was "welling-up" of blood into the cavity. Bleeding was prolonged for about one hour after the curettage. The patient was transfused with 2 pints of blood. He made an uneventful recovery. The second histology report confirmed aneurysmal bone cyst with features consistent with the first report. Review appointments have not shown any recurrence after 2 years of treatment.

## CASE REPORT 2

A 5-year-old male was seen at the oral and maxillofacial surgery clinic with a swelling in the primary palate. The mother noticed a slow growing swelling about a year earlier. She claimed there was no history of trauma to the region. The past medical and family history was not significant.

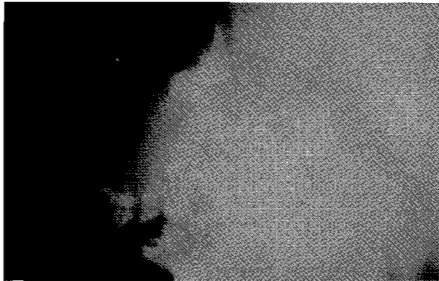
On clinical examination, a lesion in the primary palate measuring about 1 cm x 1 cm was obvious. The lesion was ulcerated and haemorrhagic and extended from 13 to 23. It was not protruding in the mouth at the initial visit. A tentative diagnosis of a dental cyst was made with periapical cemental dysplasia and fibrous dysplasia considered as differential diagnoses. A biopsy of the lesion was arranged but the mother declined the procedure and she disappeared with the patient. Nine months later, the patient was brought to the clinic with a day old history of bleeding from the mouth following repeated trauma from feeding. On clinical examination, the swelling had increased in size and was now 3 cm x 5 cm and protruding from the mouth (figure 3). It was traumatised by the lower teeth and was bleeding. A lateral skull radiograph was taken and showed a radiolucent area associated with the apices of the

**Figure 3 : Case 2. Protrusion of the lesion through the mouth. Photograph taken at second visit.**



Lateral and central incisor teeth (figure 4).

**Figure 4 Radiograph showing disruption for he dentition**

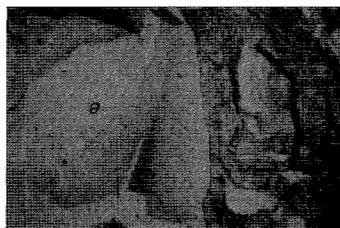

This radiolucency also involved the unerupted teeth with the resultant disruption of the dentition. An excisional biopsy was carried out under general anaesthesia and with a haemoglobin concentration of 10 gm/dl. An intraoral incision was made from upper right canine to upper left canine. The resulting defect was haemorrhagic although there was no difficulty in controlling the haemorrhage. The patient was transfused with one pint of blood. The resultant cavity was packed with gauze soaked in tincture of benzoin chloride. The mucosa was closed in layers with black silk suture.


Serial sectioning of the specimen was carried out for thorough histological examination. The histology report revealed a cellular fibro-vascular connective tissue stroma with ovoid or curvilinear trabeculae of cementoid tissue. Associated with this, is a cystic cavity lined by loose fibrous connective tissue with extravasated red blood cells. Some foreign body giant cells are scattered in the loose stroma. The histology is consistent with that of a cementifying fibroma with aneurysmal bone cyst degeneration there has not been any recurrence of the lesion after 2 years of treatment.

(Figures 5 [a-c]).

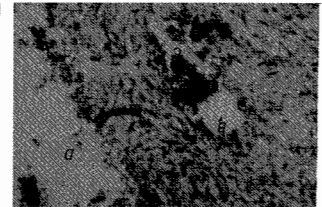
**Figures 5A:**  
(A) cementifying fibroma  
(B) cystic degeneration



**Figures 5B:**  
(A) Fibrocellular connective tissue (B) different shapes of cementoid material.



**Figures 5C (A)**  
Fibrocellular connective tissue (B) vascular space (C) giant cells (D) cystic cavity



## DISCUSSION

The ABC of the jaws is an uncertain lesion with controversy surrounding its aetiology and pathogenesis. Some authorities<sup>11</sup> recognise that trauma may play a significant role in its development but there is little evidence to support it.<sup>5</sup> None of the lesions in our patients was preceded by trauma.

The concept that ABC can arise from a pre-existing bone lesion has been widely embraced and undoubtedly, there is good evidence to sustain it.<sup>3,5</sup>

Bieseker et al<sup>13</sup> suggested the development of ABC in a pre-existing lesion. El Deeb et al<sup>8</sup> reviewed the literature in 1980 and found that of the 53 cases of ABC, 21 were associated with a pre-existing lesion of bone. A body of opinion has recognized that there exist an unrelated antecedent primary lesion of bone, which is thought to initiate a vascular malformation resulting in a secondary lesion or ABC.<sup>14</sup> The characterization of the cyst by replacement of bone with spongy fibro-osseous tissues and a locally destructive multicystic lesion filled with blood is attributed to circulatory disturbance that leads to locally increased venous pressure.<sup>15</sup> Case 2 occurred in a cementifying fibroma and tend to confirm the observation of many authorities.<sup>5</sup>

The high vascularity of the lesion was demonstrated in case 1 where a constant "welling up" of blood was observed. Other authors did not encounter a similar experience in their patient and thought that their lesion may belong to the so-called "low pressure group" of ABC.<sup>16</sup> However, the observation in case 1 was different from that of case 2 as the "welling up" of blood was not observed even though the lesion was haemorrhagic. The "welling up" of blood is a phenomenon, which is encountered in some cases and described by some authorities<sup>11</sup> and could be regarded as a feature of a "primary ABC." The lesions exhibiting this feature may be termed "true" aneurysmal bone cysts. Case 1 falls into this category because of its characteristic features while the second case, which is associated with a cementifying fibroma lend support to the view that the cyst can arise from a pre-existing lesion and such lesions could be regarded as "secondary ABC."

Many theories have been propounded to explain the vascular nature of the lesion. The view that the cyst

results from a vascular disturbance in the form of sudden occlusion or the development of an arterio-venous shunt, gained some popularity among a number of investigators.<sup>5</sup> The formation of ABC de novo is not in doubt but the frequency with which it is associated with giant cell granuloma, fibrous dysplasia and cementifying fibroma of the jaws tend to suggest an exaggerated vascular malformation in these lesions. The treatment of ABC is curettage with or without bone grafting and local resection. El-Deeb et al<sup>8</sup> in their literature review found this mode of treatment most commonly reported. Some have used simple curettage supplemented with the introduction of liquid nitrogen into the cavity<sup>4</sup> with apparent success. Other forms of treatment, which are less popular, are radiotherapy,<sup>13</sup> and cryotherapy. The potential for development of osteosarcoma makes the former mode of treatment less favoured. Recurrence rate appears high and varies between 21% to 50%<sup>11,8</sup> and some authors have attributed this to the mode of treatment stressing that simple curettage is associated with high recurrence.<sup>14</sup> We have not encountered any recurrence in any of the two cases after two years of surgery and follow up. In conclusion, the ABC may arise de novo as a primary lesion of the jaws or as a secondary lesion in a pre-existing lesion as demonstrated by these two cases. The reason it commonly arises from a fibro-osseous lesion is not properly understood and the need to carry out serial sectioning of biopsy specimens of the lesion is advisable in order to detect co-existing lesions.

#### REFERENCES

1. **Perrotti V, Rubini C, Fioroni M, Piattelli A.** Solid aneurysmal bone cyst of the mandible. *Int J Pediatr Otorhinolaryngol* 2004; 68: 1339-1344.
2. **Jaffe HL, Liechtenstein L.** Solitary unicameral bone cyst. *Arch Surg.* 1942; 46:1004-1025
3. **Robin PD.** Aneurysmal bone cyst: A hybrid lesion? *Br J Oral Maxillofac Surg.* 1985; 23:220-226.
4. **Toljanic JA, Lechewski E, Huvos AG, Strong EW, Schweiger JW.** Aneurysmal bone cysts of the Jaws: A case study and review of the literature. *Oral Surg, Oral Med, Oral Pathol* 1987; 64: 72-77.
5. **Shear M.** Aneurysmal bone cyst In: *Cysts of the jaws* (3<sup>rd</sup> Ed), 1992, Wright, Oxford PP 179-186.
6. **Bernier JL, Bhaskar SN.** Aneurysmal bone cyst of the mandible. *Oral Surg, Oral Med, Oral Pathol* 1958; 11:1018 1029.
7. **Levy WM, Miller AS, Bonak Darpour A, Aegerter E.** Aneurysmal bone cyst secondary to other osseous lesions. *Am J Clin Pathol* 1975; 63: 1 7.
8. **EL Deeb M, Sedano HO, Waite DE.** 1. Aneurysmal bone cyst of the jaws: Report of a case associated with fibrous dysplasia, and review of Literature. *Int J Oral Surg.* 1980; 9:301-311.
9. **Boyd RC.** Aneurysmal bone cysts of the jaws. *Br J Oral Surg.* 1978 1979; 16: 248 253.
10. **Kershisnik M, Batsakis JG.** Aneurysmal Bone cyst of the jaws. *Ann Otorhinolaryngol* 1994; 103: 164-165.
11. **Shafer WG, Hine NK, Levy B N (eds).** Text book of Oral Pathology. (4<sup>th</sup> Ed) 1974 Philadelphia, London Saunders PP 138 140.
12. **Iyogun CO.** Aneurysmal bone cyst of the mandible: report of 4 cases and review of the literature. *Cent Afri J Med* 1987; 30: 230 237.
13. **Biesecker JL, Marcove RC, Huvos AG, Mike V.** Aneurysmal bone cyst: a clinico pathologic study of 66 cases. *Cancer* 1970; 26: 615 625.
14. **Regezi JA, Sciubba JJ (Eds).** Aneurysmal bone cyst. In: *Oral Pathology. Clinico-pathologic Correlations* (3<sup>rd</sup> Ed), Saunders W B 1999; PP 309- 310.
15. **Sanchez AP, DiazLopez EO, Rojas SK, Neri HA, Valle PL, Pine SS.** Aneurysmal bone cyst of the maxilla. *J Craniofac Surg* 2004; 15: 1029-1033
16. **Newman L.** Aneurysmal bone cyst a lesion in the mandibular ramus. *Br J Oral Maxillofac Surg.* 1987; 25:74 78.