

BILATERAL BENIGN PHYLLODES TUMOUR IN A NULLIPAROUS WOMAN: A CASE REPORT AND REVIEW OF LITERATURE

* E.R Ezeome, **O.C Okafor, *C.E Nwajiobi, * C.C Osuagwu

Departments of *Surgery and ** Pathology, , University of Nigeria Teaching Hospital PMB 01129, Enugu, Nigeria

ABSTRACT

Cystosarcoma Phyllodes is an uncommon disease of the breast with variable clinical behaviour. Its incidence is reported as 1% of all breast tumours. The occurrence of bilateral disease is very rare. In this communication, we present a case of metachronous bilateral benign cystosarcoma phyllodes presenting in a 24year old nulliparous lady. She had right breast mastectomy after two recurrences following local excision. The left breast lesion developed one year after the treatment of the right lesion, again she had to be treated with mastectomy after 2 recurrences. This case unlike most reported cases of bilateral Phyllodes tumour occurred in a nulliparous lady. The problems of diagnosis, clinical behaviour and management are discussed.

Key words: Breast sarcoma, Cystosarcoma phyllodes, Bilateral, Benign (Accepted 7 April 2006)

INTRODUCTION

Cystosarcoma phyllodes is a rare breast tumour. It constitutes only 1% of all mammary tumours and 2.5% of mammary fibroepithelial lesions.^{1,2} It has been classified as benign, borderline or frankly malignant based on the criteria proposed by Azzopardi and Salvadori.¹ The median age of presentation is 45 years.¹ It often grows rapidly to attain great size. The occurrence of phyllodes tumour in both breasts in a lady is exceedingly rare.^{2,5} The purpose of presenting this case is not only its bilateral nature but also unlike most reported cases, both tumours were benign and occurred in a nulliparous lady outside pregnancy and lactation which are the known conditions that accelerate rapid progression of phyllodes tumour.

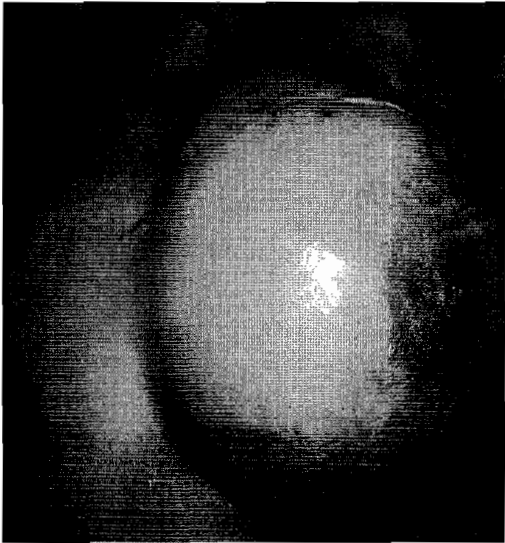Case Report

Mrs O.I was a 24year old newly married nulliparous Nigerian lady who presented at our General Surgical outpatient clinic in 1999 with a 6 months history of a painless right breast lump. The lump had progressively increased in size with no features of malignancy. There was no associated pain, nipple discharge or other lumps in the breast. She had excision biopsy of the lump during which a 8 x 6 x 4cm mass was removed. The histology report of the specimen came out as benign cystosarcoma phyllodes. The patient was counseled on the biological behaviour of the tumour

And the need for a wide excision. She however defaulted from treatment and was seen 4 months later with a recurrent tumour in that same breast. The tumour had now progressed to involve about three quarters of the whole breast. There were no systemic features of malignancy. She was counseled on total mastectomy but she declined the offer. She was referred to another consultant in the unit who agreed to offer her a simple excision. A simple excision of the mass was done at which a 16x16cm mass involving all breast quadrants was removed. The histology report of the tumour came out as giant fibroadenoma. Five months after the second surgery, she presented again with a recurrent lump in the same breast with no features of metastasis. This time she consented to simple mastectomy. At surgery, the findings were a 12 x 10 cm fungating mass adherent to the pectoralis major muscle with enlarged freely mobile level 1 axillary node. A level 1 axillary sampling was done at the surgery. Histology report (figure 1) confirmed the tumour to be benign cystosarcoma phyllodes with no lymph node metastasis.

A year after the simple mastectomy, the patient presented in the outpatient clinic with a left breast lump, which was painless, and progressively increasing in size. There were no features of systemic disease. The mass on examination measured 3x4cm, was firm, freely mobile and there was no palpable axillary lymph node enlargement. There was no clinical evidence of recurrence on the right side. An excision biopsy of the tumour was done and histology report came out as fibroadenoma.

One year after the biopsy, she was seen again in the out patient clinic with a recurrent left breast mass involving at least two quadrants of the left breast. A repeat excision of the mass confirmed it to be benign phyllodes tumour. She was counseled on the options of wide excision with whatever was left of the breast or a simple mastectomy. She defaulted from treatment and was seen 8 months later with 25 x 30cm mass that had taken over the whole breast, with shiny edematous skin, dark necrotic skin patches, retracted nipple, peau d'orange and dilated superficial veins [picture].




The ipsilateral lymph nodes were palpably enlarged. A left simple mastectomy with axillary lymph node sampling was done. Histology of the tumour was again reported as benign phyllodes tumour with no axillary lymph node involvement (figure 2). She was counseled on breast reconstruction but declined the offer. She has been on follow up in the out patient department for past 20 months after the left breast mastectomy. At the last visit in February 2006, she has had her first baby and there were no evidence of metastatic disease.

Figure 1: Histology slide of right breast tumour done in 2000. Note the leaf-like structure within an empty cystic cavity. This structure is lined by two layers of epithelial cells and contains hypercellular stroma in the core



Figure 2: Histology slide of left breast tumour done in 2004



DISCUSSION

Bilateral cystosarcoma phyllodes (CSP) is very rare. Pandit et al reported the 7th case in world literature in 1985.² Since then 6 more cases have been reported.³⁻⁸ Most of the reported cases have a malignant form of the disease in at least one side of the breast. Our patient has benign disease in both breasts. We are convinced that we are dealing with two different primaries because all the histologies done on every specimen from each side showed benign disease. We have followed this lady now for more nearly 2 years after completion of all treatment. So far, there is no evidence of any systemic disease. Most reported cases of bilateral phyllodes tumour have occurred in young women in association with pregnancy or lactation.^{2,5} The association between pregnancy and phyllodes tumour has been discussed by many authors.^{2,5,9} Lactation has been proposed as a precipitating factor in the metamorphosis of bilateral phyllodes tumour,² while the role of female hormones remains unclear.⁹ This was not the case with this our patient who is nulliparous and has just got married at the time of initial diagnosis and second primary tumour. Our patient was 24 years old at the time of presentation. Phyllodes tumours commonly occur in the 4th and 5th decades.¹ The young age of our nulliparous patient and the bilateral nature suggest a stimulus outside the usual ones of pregnancy and lactation as driving the occurrence of this tumour in this patient. An unusual expression or sensitivity to estrogen and progesterone may account for these. The histology of the tumour from each breast of this patient was reported as fibroadenoma on one occasion each. This illustrates the difficulty in differentiating the two lesions. Many authors have discussed the relationship between fibroadenoma and phyllodes tumour.^{1,10,11}

While some argue and have shown evidence to prove that phyllodes tumour can develop from fibroadenoma,¹⁰ the current thinking is that they are two different disease entities with different histological appearance, clinical behaviour and therefore different treatment approaches.^{1,11} Both can coexist in the same breast.¹ The differentiation of giant fibroadenoma from phyllodes tumour still remains a problem. The clinical features of phyllodes tumour do not differ from those of giant fibroadenoma. Differentiation from phyllodes tumour is made only on histology. Even this may be difficult as shown by this our case. Both fibroadenoma and phyllodes tumour are tumours of mixed epithelial and connective tissue elements. The epithelial elements in both are benign. When the connective tissue (fibrous stroma) is bland, it is called fibroadenoma but when it is abnormal, it is called phyllodes tumour.¹¹ The degree of histological tissue abnormality of the fibrous tissue element determines whether it is benign or malignant CSP. About 2-45% of phyllodes tumour are classified as malignant.¹ Local clinical behaviour and appearance of the tumour do not follow the histological picture. Benign lesions can be locally aggressive while skin ulceration, and pseudorange may appear in large tumours but they are no evidence of malignancy.¹ The natural history of CSP is that of local recurrence if excision is done without a wide margin (1-2cm) of normal tissue. The recurrent nature of this case is due to the fact that the lady never had a definitive conservation surgery of wide excision. This was due to her default from treatment after the biopsy of the right breast tumour and also the wrong histological diagnosis of the initial biopsy of the left tumour. The need for adequate patient education in these cases especially when it occurs in very young patients can never be overemphasized. The best chance for cure with wide excision is optimized at the first time when the tumour is still small. With each subsequent recurrence, the tumour can and do transform into a more aggressive one.¹ Indeed our findings during mastectomy of both sides in this patient made us to worry that the tumour had by then become frankly malignant but the histological reports have been otherwise. Appropriate treatment for CSP has been extensively discussed. It has now emerged that even for frankly malignant cases, adequate treatment should be wide local excision with a tumour free margin of at least 1-2cm.¹

Mastectomies are now reserved for large tumours or those who for some reasons, adequate margin could not be achieved at conservative surgery. More of the malignant cases are likely to have mastectomy in view of their more aggressive nature.

REFERENCES

1. **Parker SJ, Harris SA.** Phyllodes tumour. *Postgrad Med J* 2001; 77:428-435
2. **Pandit AA, Vora IM, Shenoy SG, Gurjar AM.** Bilateral phyllodes with osteogenic sarcomatous stroma: a case report with a review of literature. *J Postgrad Med* 1985 31(4): 215-216
3. **Ball AB, Fisher C.** Bilateral malignant phyllodes tumour. *J Surg Oncol* 1991; 46: 67-69
4. **Keelan PA, Myers JL, Wold LE, Katzmann JA, Gibney DJ.** Phyllodes tumour: clinicopathologic review of 60 patients and flow cytometric analysis in 30 patients. *Human Pathol* 1992; 23: 1048-1054
5. **Mrad K, Driss M, Manley M, Roimchane KB.** Bilateral cystosarcoma phyllodes of the breast: a case report of malignant form with contralateral benign form. *Ann Diagnostic Pathol* 2000 Dec, 4(6): 370-372
6. **Grimmes MM.** Cystosarcoma phyllodes of the breast: histologic features, flow cytometric analysis and clinical correlations. *Mod Pathol* 1992; 5: 232-239
7. **Rowell MD, Perry RR, Hsiu JG, et al.** Phyllodes tumour. *Am J Surg* 1993; 165: 376-379
8. **Murad TM, Hines JR, Beal J, et al.** Histopathological and clinical correlations of cystosarcoma phyllodes. *Arch Pathol Lab Med* 1988; 112: 752-756

9. **Way JC, Culham BA.** Phyllodes tumour in pregnancy: a case report. *Can J Surg* 1998; 41: 407 - 409
10. **Curran BC and Dodge OG.** Sarcoma of the breast with particular reference to its origin from fibroadenoma. *J Clin Pathol* 1962; 15: 1 16
11. **Noms HJ and Taylor HB.** Relationship of histological features to behaviour of cystosarcoma phyllodes- analysis of ninety four cases. *Cancer* 1967; 20: 2090 2099