

Reattachment of dehydrated tooth fragments: Two case reports

FÖ Bozkurt, B Demir¹, E Erkan²

Departments of Restorative Dentistry, ¹Periodontology and ²Endodontics, School of Dentistry, Istanbul Medipol University, Istanbul, Turkey

Abstract

Anterior crown fractures are the most common type of injury in dental trauma. The ideal treatment is to reattach the fragments as quickly as possible following intraoral and radiographic examination, but sometimes delayed treatment appointments are necessary because of uninformed patients/parents or multidisciplinary cases included endodontically and periodontically. Delayed reattachment may lead to unesthetic results because of the dehydration of fragments. The purpose of this study was to present 1-year follow-ups of reattachment of dehydrated fragments using dentin bondings and flowable composites in two different cases. The color of the dehydrated fragments was natural in the control appointments and 1-year follow-ups show harmonious integration of color, form and texture after the reattachment of the original piece of tooth. Restoration of the tooth by reattaching the original fragment is the best way of treatment in esthetic, conservative and economic point of view.

Key words: Dehydrated, tooth fractures, tooth injuries

Date of Acceptance: 14-Jul-2014

Introduction

One of the problems frequently encountered in dental practice is trauma that can damage hard and soft tissues of the oral cavity. Anterior crown fractures are commonplace in children and adolescents and may affect up to 25% of this patient population.^[1] Anterior teeth, especially maxillary incisors, are affected more than mandibular teeth because of their position in the dental arch.^[2] With the importance to the person's physical appearance, crown fractures of anterior teeth requires immediate treatment solutions.^[3,4]

Although newer formulations of composite resins offer us a large variety of products with optical properties such as translucency, opacity, different enamel and dentin colors, there is, however, no synthetic restorative material that can replace the natural tooth structure better than itself.^[3] When it is present, reattaching the original fragment is the best way of treatment in esthetic, conservative and economic point of view.

Address for correspondence:

Dr. Funda Öztürk Bozkurt,
Department of Restorative Dentistry, School of Dentistry, Istanbul Medipol University, Atatürk Bulvarı No: 27, Unkapani, 34083, Fatih-Istanbul, Turkey.
E-mail: fbozkurt@medipol.edu.tr

The concept of reattachment began in 1964 by Chosack and Eidelman.^[5] In the following years, various techniques have been described and due to the developments in adhesive technology reattachment treatment became very simple and successful.^[4] Clinical trials and long-term follow-up have reported that reattachment using modern dentine bonding agents or adhesive luting systems may achieve functional and aesthetic success for up to 7 years.^[1]

The ideal treatment is to reattach the fragments as quickly as possible following intraoral and radiographic examination, but sometimes delayed treatment appointments are necessary because of uninformed patients/parents or multidisciplinary cases included endodontically or periodontically. Delayed reattachment may lead to unaesthetic results because of the dehydration of fragments.^[1] The purpose of this study was to present 1-year follow-ups of reattachment of dehydrated

Access this article online

Quick Response Code:



Website: www.njcponline.com

DOI: 10.4103/1119-3077.147004

PMID: *****

fragments by using dentin bonding and flowable composites in two different cases.

Case Reports

Case 1

A 21-year-old female patient referred our faculty clinic with a complaint of broken tooth 2 days before [Figure 1]. In the extraoral examination, the injury of soft tissue was obvious with one suture in the lower lip. Intraoral examination revealed that the crown of maxillary left lateral incisor (22) was fractured and at the palatal region there was a mobile tiny piece of tooth fractured vertically without displacement. There was no pulp exposure, and the tooth was sensitive at cold pulp testing performed by chloroethyl refrigerant spray (IGS Aerosols GmbH, Wehr, Germany). There was no root fracture observed in the intraoral periapical radiograph. A written informed consent was obtained from the patient before the treatment. Past medical history was reviewed, and there was no remarkable report. The palatal gingiva was elevated by a flap surgery, and the mobile root fragment was removed. After checking the fracture lines, etch and dry adhesive (S³ Bond Plus, Kuraray, Japan) was applied to the tooth and the fragment with a brush by scrubbing for 20 s. The adhesive was air thinned and light-cured (Elipar Free Light, 3M ESPE, AG, Germany) for 20 s. Flowable composite (Filtek™ Ultimate, 3M ESPE, USA) was placed over the fracture area on the tooth, and the fragment was placed over. The excess material was removed before light-curing for 40 s. In order to reduce sensitivity and protect the pulp, light-cured glass ionomer liner (Glass Liner, WP Dental, Germany) was placed over the exposed dentin of the crown. A second appointment was scheduled for the direct restoration of the tooth by composite resin since the patient didn't have the broken fragment. However in the next appointment, the patient came with the broken piece which was recovered at the site of the injury and kept in dry conditions. A 2% chlorhexidine

digluconate (Cavity Cleanser, Bisco, USA) solution was used for disinfection of the fragment. The glass ionomer lining, which was placed for protection, was removed carefully with an explorer. The fragment was dehydrated but fitted perfectly to the remaining tooth and hence the treatment plan of choice was to reattach the fragment. The tooth fragment was bonded by the same manner as the root piece with the only exception of selective etching of enamel margins of the tooth and fragment for 10 s. The occlusion was checked and adjusted then finishing and polishing steps were completed by abrasive disks (Sof-Lex™ Finishing and Polishing Systems, 3M ESPE, USA) and rubber cups (Jiffy® Polishers, Ultradent, USA) [Figure 2a]. The patient was told to avoid exerting heavy function with her tooth and to follow regular home care procedures relative to oral hygiene.

In the control appointment (2-weeks later) the color of the reattached fragment was acceptable, and the form of the tooth was aesthetic with its original shape [Figure 2b].

In the 1-year follow-up, the tooth showed a marginal discoloration, which was easily removed by polishing [Figure 3a and b] but, unfortunately, there was a radiolucent area at the apex and the tooth was nonvital in cold pulp test, so an endodontic treatment was performed by using ProTaper Ni-Ti Rotary System (Dentsply Malleiffer) and obturated with an AH 26 sealer (Dentsply; DeTrey, Konstanz, Germany) and gutta-percha by lateral compaction technique [Figure 4a and b].

Case 2

A healthy 11-year-old female patient referred for an aesthetic restoration of a fractured maxillary right central incisor (11) [Figure 5]. Dental history revealed that the tooth was fractured 1 month prior to presentation because of a bicycle accident. Her first dentist applied a root canal

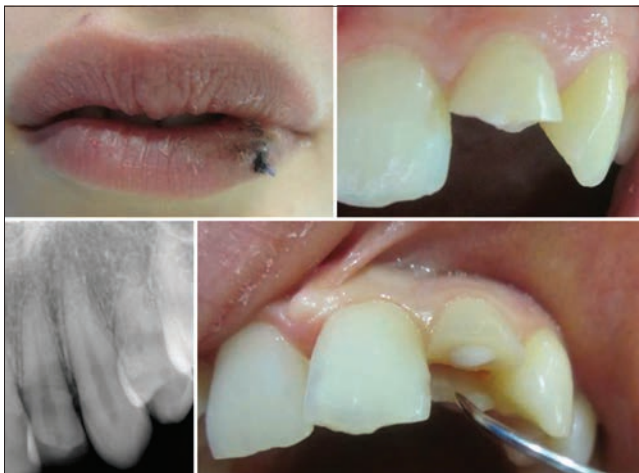

Figure 1: Images of injury of a fractured maxillary left lateral incisor

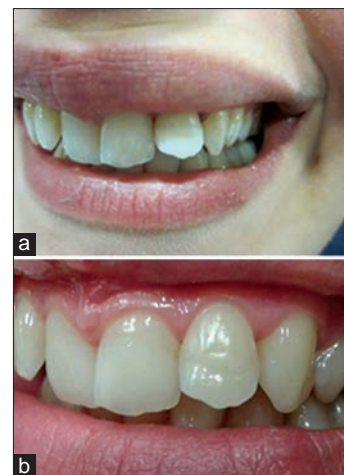

Figure 2: Postoperative images (a) immediately after reattachment showing color difference because of dehydration (b) harmonious integration of color in 2 weeks control

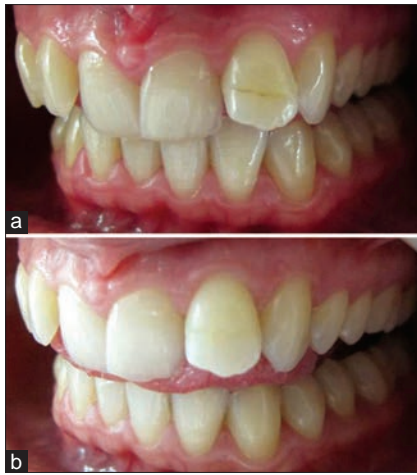

Figure 3: One year follow-up (a) marginal discoloration (b) easily removed by polishing

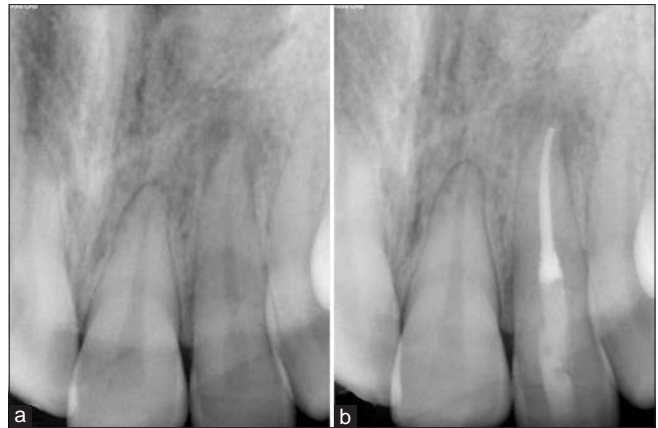


Figure 4: (a) Radiograph of 1-year follow-up showing radiolucency at the apex area (b) radiograph after endodontic treatment

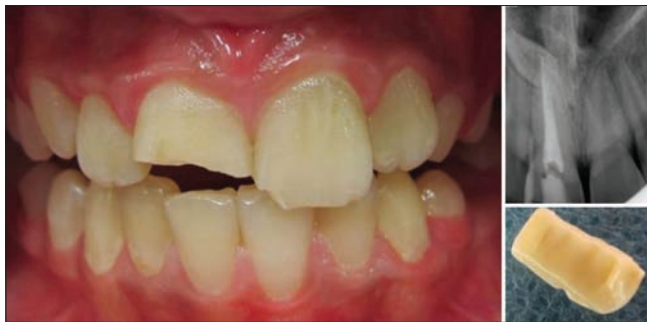

Figure 5: Preoperative images of a fractured maxillary right central incisor

treatment and suggested a temporary composite restoration until a crown restoration at the age of 18 for better clinical results. The parents hesitated for a final crown restoration and referred our university clinics in order to find a remedy. As they were informed about the treatment alternatives of a fractured tooth, her mother gave us the dehydrated fragment she kept with her ever since the accident. The fragment was placed in 2% chlorhexidine digluconate solution for disinfection and tried intraorally to check for proper positioning and fit with the fractured coronal structure. A written informed consent was signed by the patient's mother as the guardian before the treatment. Following clinical and radiographic examination, the endodontic treatment was found to be successful but a horizontally located mesiodense in the apex area was noticed. Since the lamina dura surrounding roots of both teeth could be detected separately, the mesiodense was followed-up closely for future recalls. The fragment and the tooth were acid etched for 30 s with 37% phosphoric acid gel, rinsed for 30 s and gently air dried. A one-bottle etch and rinse adhesive (Adper Single Bond 2, 3M ESPE, USA) was applied with a brush for 20 s and carefully air thinned. Flowable composite was placed over the fracture area on the tooth, and the fragment was placed over. The excess material was removed before light-curing for 40 s from labial and

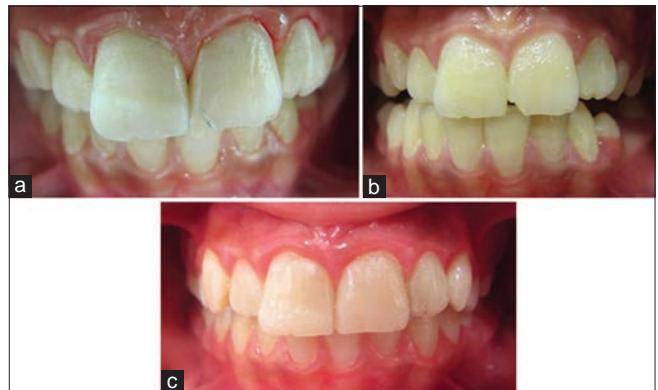

Figure 6: Postoperative images (a) immediately after reattachment showing dehydration (b) acceptable color in 2 weeks control (c) 1-year follow-up

palatal surfaces. After occlusion adjustment finishing and polishing steps were completed by the same manner as in case 1. The patient was told to avoid exerting heavy function with her tooth and to follow regular home care procedures relative to oral hygiene.

In the control appointment (2 weeks later), the color of the fragment was found to be acceptable by rehydrating [Figure 6a] and the broken part of the left central incisor was restored by a nanohybrid resin (Filtek™ Z550, 3M ESPE, USA) [Figure 6b]. The final 1-year postoperative results reflected the harmonious integration of color, form and texture after the reattachment of the original piece of tooth [Figure 6c].

Discussion

Reattachment of fractured fragment is an excellent approach for the treatment of coronal fractures.^[1-4] The prognosis for re-attached crown fragments is good and continues to improve with the increasing bond strengths achievable with dentine bonding agents.^[6]

Sometimes the fractured fragment is dehydrated because of being kept in the tissue. In these two cases, the fragments were intact, but dehydrated for being kept in dry conditions for more than 2 weeks. The fragments were unesthetic because of dehydration in the first trial but both the patients preferred to use their own tooth piece instead of a direct composite restoration.

Reis *et al.* reported different fracture strength for several reattaching techniques^[7] but in these two cases there was no special preparation for the tooth or the fragment.

All traumatic dental injuries need to be followed-up over time.^[8,9] Endodontic treatment of teeth with uncomplicated crown fractures is usually unnecessary unless pulp necrosis and infection develop subsequent to the injury, but the pulps in traumatized teeth can become necrotic and infected even a number of years subsequent to an injury.^[9] Here in the first case, the radiographic examination in 1-year recall showed a radiolucent area at the apex and vitality test revealed that the tooth was nonvital, so the endodontic treatment of the tooth was performed 1-year after injury. The reattachment of dehydrated tooth fragments by bonding technique is a simple and satisfactory treatment for crown fractures.

References

1. Murchison DF, Burke FJ, Worthington RB. Incisal edge reattachment: Indications for use and clinical technique. *Br Dent J* 1999;186:614-9.
2. Castro JC, Poi WR, Manfrin TM, Zina LG. Analysis of the crown fractures and crown-root fractures due to dental trauma assisted by the Integrated Clinic from 1992 to 2002. *Dent Traumatol* 2005;21:121-6.
3. Terry DA. Adhesive reattachment of a tooth fragment: The biological restoration. *Pract Proced Aesthet Dent* 2003;15:403-9.
4. Macedo GV, Diaz PI, De O Fernandes CA, Ritter AV. Reattachment of anterior teeth fragments: A conservative approach. *J Esthet Restor Dent* 2008;20:5-18.
5. Chosack A, Eidelman E. Rehabilitation of a fractured incisor using the patient's natural crown: Case report. *J Dent Child* 1964;31:19-21.
6. Farik B, Munksgaard EC, Andreasen JO, Kreiborg S. Fractured teeth bonded with dentin adhesives with and without unfilled resin. *Dent Traumatol* 2002;18:66-9.
7. Reis A, Franci C, Loguercio AD, Carrilho MR, Rodrigues Filho LE. Re-attachment of anterior fractured teeth: Fracture strength using different techniques. *Oper Dent* 2001;26:287-94.
8. Moule AJ, Moule CA. The endodontic management of traumatized permanent anterior teeth: A review. *Aust Dent J* 2007;52:S122-37.
9. International Association of Dental Traumatology. Available from: <http://www.iadt-dentaltrauma.org>. [Last accessed on 2013 Aug 15].

How to cite this article: Bozkurt FO, Demir B, Erkan E. Reattachment of dehydrated tooth fragments: Two case reports. *Niger J Clin Pract* 2015;18:140-3.

Source of Support: Nil, **Conflict of Interest:** None declared.