

GIANT CALCULUS IN THE MOUTH OF A PARTIALLY EDENTULOUS WOMAN, (CASE REPORT)

J.O. Taiwo, B. Shodeinde*

*Department of Preventive Dentistry, College of Medicine, University of Ibadan, *University College Hospital, Ibadan.*

ABSTRACT

Objective:- This case report is to create awareness of the presence of giant calculus in the mouth, the possible causes and its prevention.

Report:- This describes the oral condition of a partially edentulous woman with a giant calculus in the mouth. It highlights the effect of such an enormous calculus in the oral cavity.

Conclusion:- Such gross calculus formation could have resulted from oral hygiene neglect, facilitated by the anatomical position of teeth 18 and 46 as well as lack of use of these teeth for mastication. The importance of plaque control in maintenance of oral health and in the prevention of calculus formation cannot be over emphasized. Even though chemotherapeutic agents are available, effective mechanical plaque removal still remains the best method to achieve this purpose.

KEY WORDS:- Calculus, Juvenile, periodontitis, Plaque, Prevention

INTRODUCTION

Calculus is calcified plaque and its formation is always preceded by plaque formation with initial crystals forming in the intermicrobial matrix of plaque, in close proximity with bacteria¹. Calculus consist of 70-90% inorganic material of which approximately 60% are in crystalline form². Of the four common crystalline forms of calculus, (hydroxyapatite, whitlockite, brushite and octacalcium phosphate) brushite tends to be more common in supragingival calculus whilst whitlockite is found particularly in subgingival calculus². The in-organic component of calculus consist predominantly of proteins and carbohydrates, lipids and non vital microorganisms¹.

Various theories have been proposed for the appearance of these crystals in dental plaque, which heralds calculus formation². One of the theories, the carbon dioxide theory states that the level of carbon dioxide present in saliva, which leaves the ducts of the salivary glands, is considerably higher than that found in the saliva in the mouth. This difference will result in the escape of carbon dioxide from saliva, resulting in a rise in pH. When the pH of saliva rises it can not hold much calcium and phosphate ions in solution, therefore spontaneous precipitation occurs². Another theory states that ammonia production results in a rise in plaque pH because it has been shown that rapid calculus formers have an increase in urea concentration in their saliva². Also break down of proteins in plaque might result in the local production of urea and subsequently Ammonia. This in turn leads to a rise in the pH of plaque which would induce the local precipitation of calcium and phosphate ions². The epitaxis or

nucleation theory proposes that crystallization is nucleated by a compound of different chemical composition, although the compound supposed to start crystallization has not yet been identified². However micro-organisms degenerating under experimental conditions have been shown to form calcium phosphate crystals of the same type as those seen in calculus².

Primary and secondary prevention of calculus is very important in the prevention of periodontal disease, particularly as the surface of calculus is vulnerable to plaque accumulation and retention of irritant deposits, which in turn are involved in the initiation and progress of periodontal disease³.

Plaque as the primary etiologic factor in the initiation and progress of gingivitis and periodontitis, the two major periodontal diseases, has been established beyond doubt in various studies⁴.

Periodontal disease is the commonest oral disease in developing countries⁵ and it has been shown to be highly prevalent in Nigeria in all age groups^{6,7,8}.

Forms of periodontitis which are characterized with advanced destruction in early childhood, adolescence and early adulthood are described respectively as pre-pubertal, juvenile and rapidly progressive periodontitis⁸. These have been linked with specific subgingival floras such as *Actinobacillus actinomycetemcomitans*, *Bacteriodes intermedius*, *Capnocytophaga*, *Fusobacteria nucleatum* and *Spirochaetes* (*treponema* spp). Also implicated in the etiology of the above form of periodontitis are impairment of the immune and inflammatory mechanism as well as familial distribution⁸.

Quite often many people in this environment present at the dental clinic with gross accumulation of calculus. However rarely do they present with such an enormous size of calculus. Such presentations have quite often baffled some colleagues resulting

*Correspondence: Dr. J.O. Taiwo

in it being misdiagnosed as a jaw tumour.

This case report is to create awareness of the presence of such giant calculus their possible causes, and their prevention.

CASEREPORT

A 26 year old, healthy looking seamstress presented with the complaints of pain from her teeth, swelling on the right half of her face, restricted mouth opening and restricted chewing. She complained that she has lost almost all her teeth and this situation started since she was a teenager. She had previously visited other hospitals. She wanted a denture constructed for her. She was not on any drugs at the time of presentation and she had no allergy to any drugs. She had no chronic medical illness and had never been hospitalized.

She visited the dental clinic twice last year in an attempt to have dentures fabricated for her.

The patient is married with 3 children. She mentioned that her mother suffered from the same condition and lost almost all her teeth as a teenager before she was married. She does not smoke, drink nor chew kolanuts. She claimed she cleans her teeth once every day using toothbrush and toothpaste.

On extra-oral examination, asymmetry of the face, with a slight swelling on the right side of the face, around the commissure of the mouth was noticed Fig 1. Swelling was firm to touch and of normal body temperature. Submandibular lymph nodes were palpable, mobile but not tender to palpation.

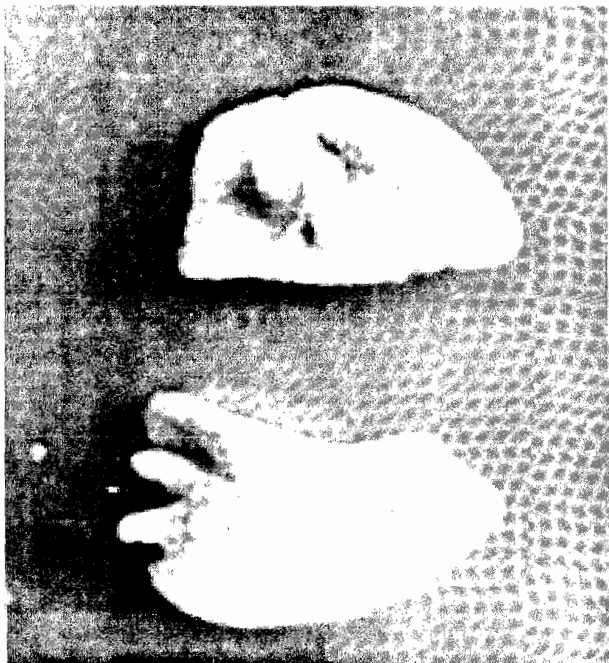
Figure 1: Extra-oral examination showing, asymmetry of the face and slight swelling of the right side.

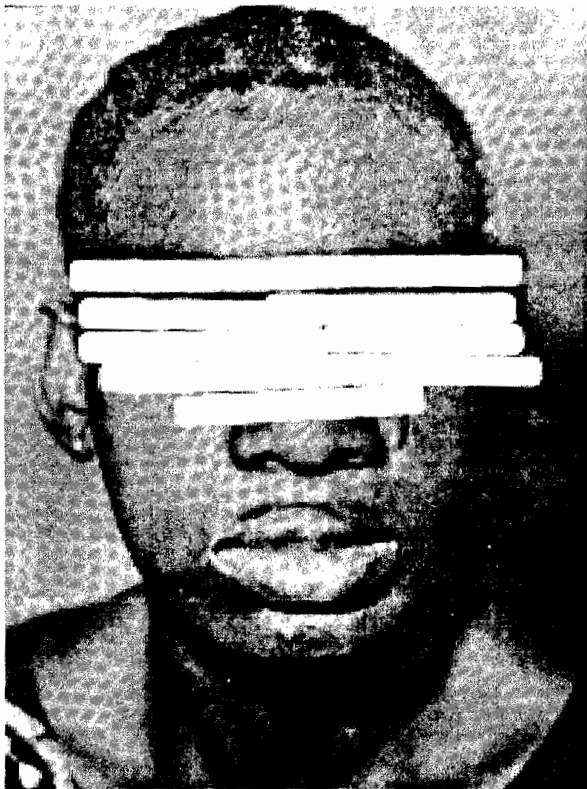

Figure 2: Intra-oral examination showing partially edentulous patient with tooth 28 only and a big chunk of the calculus.

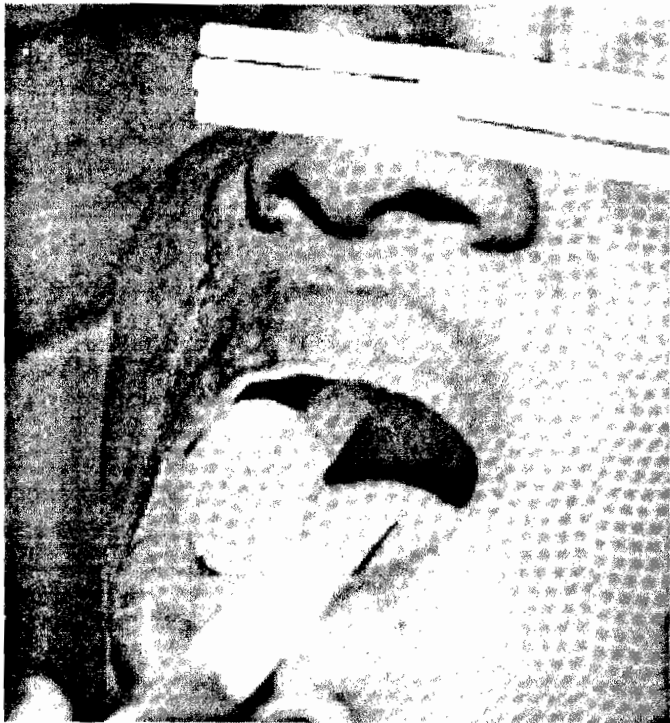

Figure 3: Further intral-oral examination revealed 2 big chunks of calculus inter locked together.



On intraoral examination, the tongue, palate, buccal mucosa and floor of the mouth appeared clinically normal. A partially edentulous patient with tooth 28 only clinically visible in the

mouth. A big chunk of calculus 50mm in length, 30 mm in buccolingual dimension and 30mm in height covering the right side of the maxilla and mandible from the regions of teeth 15 and 45 to the regions of teeth 18 and 48 was observed in the mouth Fig 2. Careful examination, revealed that there were 2 big chunks of calculus interlocked together Fig.3. It was cream in colour, chalky in texture with a rough surface, coated in thick plaque.

The gingivae below the calculus both in the maxilla and mandible were hyperemic, whilst in the other parts of the jaw, they appeared clinically normal. Periapical, radiographic view showed a homogenous radio-opaque mass attached to the bone by the roots of two teeth presumably 46 and 18, which were mobile and barely supported by bone tissues at the apices. Second degree mobility⁹, mesiobuccal and distobuccal pockets of 5mm of tooth 28 was observed. X-ray revealed gross bone loss in relation to the same tooth.

Possible diagnosis were juvenile periodontitis, prepubertal periodontitis and rapidly progressive periodontitis. Based on the presenting history of loss of a great number of her teeth during adolescence, familial history of the same condition in her mother, x-ray presentation and clinical picture, a definitive diagnosis of generalised juvenile periodontitis, advanced stage cum presence of gross calculus was made.

Treatment given consisted of oral hygiene motivation, after which the calculus was extracted with the supporting teeth. Patient was advised to have tooth 28 extracted, based on its prognosis and the cost benefit of having a complete denture of both the upper and lower jaws constructed. The Patient declined this option and as an alternative measure tooth 28 was scaled and deep curettage and irrigation with normal saline and hydrogen peroxide of the same tooth, was carried out¹⁰. The patient was placed on 250mg tetracycline four times daily for five days, metronidazole 200mg three times daily for seven days and Vit C 500mg twice daily for two weeks¹⁰. Warm saline and hydrogen peroxide mouth wash, six times daily, for seven days, was prescribed for the patient¹⁰. Subsequent visits made by the patient, expressed an improvement in gingival health, in areas which were previously inflamed and covered by calculus. A slight reduction in mobility of tooth 28 was observed, although control of plaque around tooth 28 was still poor. The patient was counselled on oral hygiene and was asked to report again for review in a week's time. The patient did not report for subsequent follow up visits.

DISCUSSION

Juvenile periodontitis is a rare condition which usually occurs in adolescents¹¹. It is a familial disease in which there is a distinct pattern of alveolar bone loss, which is characteristically localized to the first permanent molars and incisor teeth. A more generalized form of the disease affecting the entire dentition has been recognized¹¹. This case is of particular interest since this disease condition is associated with clean teeth, although there have been cases with poor oral hygiene and gross accumulation of plaque, as is exhibited in this patient¹¹. A patient with juvenile periodontitis falls into the high risk group and plaque level, gingival and periodontal health of such a patient needed to be closely monitored to prevent early loss of these teeth.

The aim of prevention of periodontal disease is to maintain a functionally, esthetically and socially acceptable natural dentition for the life span of most people¹².

Plaque forms continuously and tooth surfaces cannot be maintained in a plaque free state by conventional mechanical means¹³. The objective of plaque control in prevention of periodontal disease is therefore the periodic removal of accumulated plaque at intervals which are sufficiently frequent to prevent pathological effects arising from recurrent plaque formation¹³. To achieve gingival health the interval between tooth-cleaning sessions should not be less than 12 hours and should not be more than 48 hours, depending on prevailing gingival conditions and individual susceptibility to periodontal disease¹³. Toxins produced by bacteria plaque exert a toxic effect on the host cells, encourage degradation of tissues, have a chemostatic and antigenic effect, facilitate activation or suppression of inflammatory, immune mechanisms and stimulate bone resorption¹³.

Dental calculus falls in the group of plaque retention factors which modify the form of the clinical crown of the tooth, rendering plaque inaccessible to the patient during routine brushing¹³. In addition the surface of calculus retains plaque bacteria products which are injurious to the periodontium. It has been demonstrated that though the ordinary toothbrush cleans facial, oral and occlusal surfaces effectively, distal surfaces of last standing teeth and approximal surfaces bounding to edentulous zones are not readily cleaned¹⁴. The absence of adjacent teeth to the teeth encrusted in calculus may have contributed to the inability to control plaque around these teeth, resulting in the gross accumulation of plaque and subsequently calculus. The largest amount of supragingival calculus appear opposite the openings of the major salivary glands, on the buccal surfaces of maxillary molars and lingual surfaces of lower incisors. Whilst subgingival calculus occurs on the roots of teeth with periodontal pocketing². This explains the location of this giant calculus. The mechanism of chewing is a means by which the body cleans the oral cavity and avoid stagnation of food debris in the oral cavity. In areas where chewing is deficient and oral hygiene is compromised, there is accumulation of plaque and a resultant build up of calculus. This is clearly demonstrated in this patient. Calculus in a completely edentulous mouth is yet to be documented in the history of periodontal disease. Many patients, such as this patient even with the poorest oral hygiene claim they brush their teeth daily, using tooth brush and tooth paste. Various authors have emphasized effective cleaning rather than the frequency, as the most important aspect of cleaning the teeth¹¹. Often when mobile teeth are held in place by a big chunk of calculus, after scaling and polishing, the mobility of such teeth become apparent to the patient, creating the impression that the dentist has caused mobility of these teeth. It is therefore important to explain to the patient and inform the patient of the possibility of her losing these teeth before commencing on treatment.

CONCLUSION

Such accumulation of calculus could have resulted from oral hygiene neglect and facilitated by the anatomical position of teeth 18 and 46 as well as lack of the use of these teeth for chewing.

RECOMMENDATION

The most consistent findings in periodontal research is that people with high level plaque have more periodontal disease⁴. Bacterial plaque precedes calculus and contributes to its formation¹. Therefore careful clinical oral health management and keeping the patient under surveillance would have prolonged the life of her teeth. There is need to reach out to the populace, through oral health education and campaign, to create awareness of periodontal diseases and to stress the importance of regular dental visits in its prevention.

REFERENCES

1. **Jenkins WMM.** The prevention and control of chronic periodontal disease. Prevention of oral disease. Murray J.J. ed. Oxford University Press. 1996; 118-138
2. **Walsh T, Figure KH, Lamb DJ.** Clinical dental hygiene. Butterworth Heinemann LTD. 1992; 56-59.
3. **Cate JM.** Recent Advances in the study of dental calculus. Oxford University Press Oxford 1989.
4. **Sheiham A.** Current concepts in health education. Efficacy of treatment procedures in periodontics. Shanley D. Bed. Chicago Quintessence Publishing Co. Inc 1980.
5. World Health Organisation (W.H.O.). Periodontal profiles. An overview of C.P.I.T.N. data in W.H.O Global Oral Data Bank. W.H.O. Geneva. 1994.
6. **Taiwo JO.** Oral hygiene status and necrotising ulcerative gingivitis in Nigerian children. J. Periodontol. 1993; 63: 1071-1074.
7. **Kubota K, Watamcebe IT, Hollist NO et al.** Dental survey in Nigeria part 4. Prevalence and severity of periodontal diseases. Bull. Tokyo med. University 1988; 35: 11-17.
8. **Taiwo JO.** Oral health needs of the elderly population in Ibadan. (Pilot study.) a report for Dreyfus Health Foundation. 1999; 32-43.
9. **Kieser JB.** Measurement of Mobility. Mobility and drifting. Periodontics, A Practical approach. Kieser J. B. ed. Wright London. 1990; 343-351.
10. **Genco RJ.** Topical antimicrobial agents evaluated for treatment of periodontal diseases. Using antimicrobial agents to manage periodontal diseases. J.A.D.A. 1991; vol. 122: 31-37.
11. **Marsh PD.** Juvenile Periodontitis. The Microbiology of periodontal disease. Periodontics. A Practical Approach. Kieser J. B. ed. Wright London. 34-35.
12. **Shieiham A.** Public health aspects of periodontal diseases in Europe. J. Clin. Perio. 1991; 18: 362-369.
13. **Keiser JB.** The fundamental role of plaque control, A rational approach. Periodontics. A practical approach. Kieser J. B. ed. Wright London. 1990; 34-35.