

INTRACTABLE ORAL CANDIDOSIS AS AN INDICATOR OF HIV INFECTION IN INFANTS

A. Ojuawo, O. Owolabi

Department of Paediatrics, University of Ilorin Teaching Hospital, PMB 1459, Ilorin, Nigeria.

ABSTRACT

Objective: Human immunodeficiency virus infection is assuming an epidemic proportion in the developing world, and infants are increasingly being infected and seen with clinical features and serological evidence of HIV infection in Ilorin.

Intractable oral candidosis is one of the clinical features of the disease seen commonly in infants. This study examined the possible association between intractable oral thrush and HIV infections in infancy.

Design: This is a prospective study carried out over a 3 year period.

Subjects & Method: Infants presenting with oral candidosis who did not respond to two courses of oral mycostatin drop given thrice daily over 2 weeks period were studied. Such infants were screened for HIV infection after parental consent. Another group of infants who did not have oral candidosis but were screened for HIV infection due to other indications served as controls for the purpose of comparison.

Results: Thirty two infants with intractable oral candidosis were screened and 28 (87.5%) were HIV positive whilst 2 out of 20 (10%) cases without intractable oral candidosis screened for other reasons were positive for HIV infection ($\chi^2 = 21.48$, $p = 0.000036$, odds ratio = 24.54 "RR" = 5.42).

The presence of intractable oral candidosis in HIV infected infants has a sensitivity of 93.3% and a specificity of 81.8%, with a positive predictive value of 85.3%. The oral lesions cleared completely with oral miconazole gel given thrice daily for two weeks.

Conclusion: The finding of extensive intractable oral candidosis which is refractory to simple oral antifungal agent therapy in infants should raise the suspicion of HIV infection and such infants should be screened for HIV after parental consent.

KEY WORDS: *intractable oral thrush, infants, HIV infection, miconazole gel*

INTRODUCTION

Human immunodeficiency virus (HIV) infection is fast becoming a public health problem in the developing countries¹⁻³. It is estimated that 2.5 percent of the adult population in sub Saharan Africa are infected with the virus⁴. Following infection, there is rapid and widespread dissemination of the virus with the virus going for T cells and dropping the CD4 lymphocytes^{5,6}.

Opportunistic infections develop with the decline in the CD4 lymphocyte count, signifying the presence of an immunodeficiency. Perinatal acquisition of HIV infection can occur through vertical transmission in utero, intrapartum and through breast-feeding^{7,8}. Infants get infected with the virus through vertical transmission from the mother. The prevalence of perinatal transmission of HIV infection ranges from 25 to 48 percent in developing countries⁸.

Oral candidosis is the most common of the many recognised oral presentation of HIV infection due to the precipitous drop in

CD4 lymphocyte levels^{9,10}. Other oral lesions include viral (herpes simplex virus, varicella zoster virus, EBV, Cytomegalovirus), bacterial (gingivitis), and fungal infections.

There is a strong correlation between CD4 level and progression of HIV disease and since fungal infection control is through cell mediated immunity, fungal infection thrives in HIV infected infants.

In our centre, some infants with HIV infection present with oral candidosis early in life and do not respond to the simple oral antifungal agents. This study therefore aims at determining the association between HIV infection and intractable refractory oral thrush in infants in this environment.

MATERIALS AND METHODS

This is a prospective study carried out at the University of Ilorin Teaching Hospital, Ilorin over a 3 year period (January 1999 to December 2001) in children presenting with oral thrush and other features suggesting an immunocompromised state (e.g. failure to thrive, recurrent cough, recurrent diarrhoea, recurrent fever etc).

*Correspondence: Dr. A. Ojuawo

The types of oral thrush are classified as^{11,12}:

@**Pseudomembraneous** – white cream coloured plaques, which bleeds when scrapped

@**Hyperplastic** – white plaques on buccal mucosa not removable by scraping

@**Atrophic** – erythematous macular lesion of mucosa, buccal mucosa and dorsum of tongue

@**Angular cheilitis** – erythema, fissuring of angle of mouth.

Intractable oral thrush is defined as oral thrush that is refractory to two courses of simple oral antifungal agent such as Mycostatin drops and / or oral gentian violet paint given thrice daily over a 2 week period. Such patients are screened for HIV infection after parental consent. The children were screened for HIV I and II using the ELISA test for screening and Western blot test for confirmation¹³. Nineteen out of the thirty two mothers of these infants consented to be screened for HIV infection.

The T cells and CD4 levels could not be measured due to lack of such a facility in our centre.

Specimens of the scrapings of the oral lesions were sent to the laboratory for characterisation of the pathogen in the infants where feasible.

Another group of infants who did not have oral candidosis but were screened for HIV infection due to other indications served as controls for the purpose of comparison.

Simple proportions were compared using χ^2 test with a p value < 0.05 being significant.

The sensitivity and specificity of observed intractable oral thrush as an indicator of HIV seropositivity were calculated using the standard table for positives and negatives.

RESULT

A total of thirty-two babies with intractable oral thrush were studied over the two-year period. Seventeen were males whilst fourteen were females giving a male : female ratio of 1.3 : 1. The age at presentation ranged between 1.5 – 18 months with a mean of 4.13 ± 1.2 months, whilst the age at first appearance of oral thrush ranged between 1 – 8.2 months with a mean age of 2.45 ± 0.8 months.

The duration of symptoms before presentation ranged between 0.75 months to 5.5 months with a mean of 2.48 ± 0.6 months (Table 1).

All the babies have had between 2 to 6 courses of oral antifungal drugs with no relief or with recurrence. Other presenting symptoms include cough (71.8%), diarrhoea (56.3%), fever and failure to thrive (53.1%) each, pemphigus and perineal excoriation (21.8%), delayed developmental milestones (18.7%) and microcephaly and global spasticity (9.4%) each (Table 2).

The pseudomembraneous type of oral thrush accounted for 71.8% of the lesions seen in these infants, whilst the angular cheilitis variety was infrequent (Fig 1).

All the mothers of the HIV seropositive infants tested were equally positive for HIV infection in this study.

Table 3 shows that 28 (87.5%) of those babies with intractable oral thrush were HIV positive whilst only 2 out of 20 (10%) of those without intractable oral thrush were HIV positive ($\chi^2 = 21.48$, $p = 0.000036$, odds ratio = 24.56, relative risk "RR" = 5.42).

Table 1: The demographic characteristics of the babies with intractable oral thrush studied.

Parameter	Mean	Range
Age at presentation in months	4.13±1.2	1.5 - 18
Age at first episode of oral thrush (months)	2.45±0.8	1-8.2
Duration of symptoms before presentation (months)	2.48±0.6	0.75-5.5
Sex Male : Female	17:15	1.13 : 1
Number of courses of antifungal before presentation	2.85	2 – 6
Outcome over a 6 months follow up period		
Alive	20 (62.5%)	
Dead	12 (37.5%)	
Average age at death in months	5.56±0.3	2.5 – 9

Table 2 Clinical features seen in the thirty two infants with intractable oral thrush and HIV infection in this study

	n	Percentage
Cough	23	71.8%
Diarrhoea	18	56.3%
Failure to thrive	17	53.1%
Fever	17	53.1%
Pemphigus	8	25%
Vomiting	7	21.8%
Perineal excoriation	7	21.8%
Developmental retardation	6	18.7%
Lymphadenopathy	4	12.5%
Microcephaly	3	9.4%
Global spasticity	3	9.4%
Anaemia	3	9.4%
Seborrheic dermatitis	3	9.4%
Cortical blindness	2	6.25%

Infants with intractable oral thrush has a five fold risk of being HIV positive.

The sensitivity and specificity of intractable oral thrush as an indicator of HIV infection in infants was 93.3% and 81.8% respectively, with a positive predictive value of 85.3% in this study.

The mortality was 37.5% at 6 months follow up in those with intractable oral thrush that were HIV positive in this study and the average age at death was 5.56 ± 0.3 months (range of 2.5 to 9 months).

All the patients had a clearance of the oral thrush with the use of Miconazole gel with only 3 (9.4%) having a recurrence at

Figure 1: Pie chart showing the clinical types of oral candidosis seen in the thirty two children

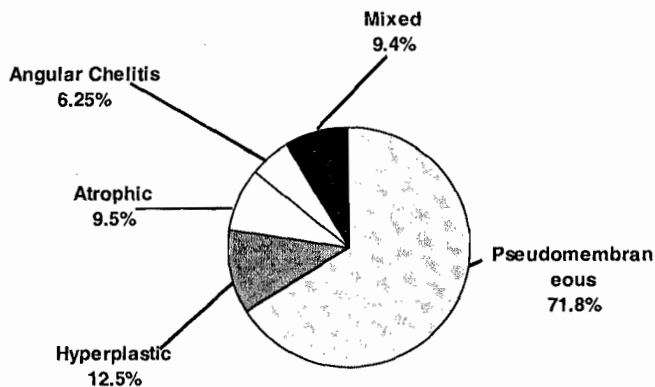


Table 3: The sensitivity and specificity of intractable oral thrush as an indicator of HIV infection in infants

	HIV positive	HIV negative
Oral thrush	28	4
No oral thrush	2	18

$\chi^2 = 21.48$, $p = 0.000036$, odds ratio = 24.54
 "RR" = 5.42

Sensitivity = 93.3%
 Specificity = 81.8%

6 months follow up.

DISCUSSION

Extensive intractable oral thrush which is refractory to the use of simple oral antifungal agents is commonly seen in HIV positive babies as demonstrated in this study. Previous studies did show that 40% of HIV infected patients have oral manifestation¹⁴. Oral candidosis is seen commonly when the CD4 cell count is less than 400 / mm³ in HIV infected patients¹⁵, though the CD4 count was not assessed in our patients due to lack of facilities.

The mean age at presentation was 4.13 months in this study, though the mean duration of symptoms before presentation was 2.48 months. With the appearance of the lesions, the mother or health giver would have used several remedies, and the patient would present only when the lesion persisted. The oral lesions reduce the appetite of the child, a factor that makes the mother to seek medical attention.

The association between oral thrush and cough / diarrhea is not surprising in these patients due to the extensiveness of the lesions. Irritation of the upper respiratory tract, causes cough. The diarrhoea is probably initiated by systemic candidosis along the entire gut, and this is further corroborated by the presence of perianal excoriation in a sizable number of the infants in this study, a finding that is in consonance with those of other reports

in the adults^{14,16,17}.

There is a highly significant association between intractable oral thrush and HIV seropositivity in the infants studied. The presence of intractable oral thrush in HIV positive infants in this study has a sensitivity of 90 percent and a specificity of over 80 percent with a positive predictive value of 85%. Previous studies reported that oral candidosis is seen in the early stage of the disease causing mild to moderate disability^{14,17}. Intractable oral thrush seems to be a very sensitive indicator of HIV infection, thus serving as an indicator for lentiviral screening in such infants. Concerning specificity, intractable oral thrush is a fairly specific indicator of HIV infection in infants. Such infants with intractable oral thrush have a five-fold risk of being HIV positive, a findings that is similar to that in adults where it could be the initial manifestation of AIDS in high risk patients^{14,17}.

The extensiveness and intractability of the oral lesions interferes with the appetite of the infants thus leading to undernutrition and failure to thrive.

The infants in this study were given different simple antifungal remedies such as Mycostatin suspension, Gentian violet oral paint and Fluconazole in two patients without relief. All the patients responded well to oral Miconazole gel with only three having a recurrence in six months. This is expected as Azole antifungal drugs has been found to be very effective in the treatment of adults with HIV and oral candidosis¹⁸⁻²⁰.

Miconazole cleared the oral lesions within 96 hours of therapy, but had to be continued for at least one week after the disappearance of the lesions to prevent recurrence.

We conclude from this study that intractable oral thrush that is refractory to simple antifungal agents is an indicator of possible HIV infection in infants in our environment. Such infants need to be screened for HIV infection after parental consent. This simple observed symptom is very sensitive and fairly specific in indicating a positive HIV infection in infants. Such oral lesion responds well to oral miconazole gel.

We recommend that infants presenting with intractable oral candidosis that is refractory to the simple antifungal agents should be screened for possible HIV infection.

REFERENCES

1. National AIDS control programme. Federal Ministry of Health and Human services: AIDS in Nigeria. Nig Bull of Epidemiol 1992;2: 6-16.
2. Olaleye OD, Bernstein L, Ekweozor CC et al. Prevalence of human immunodeficiency virus types 1 and 2 infections in Nigeria. J Inf Dis 1993; 167: 710-4.
3. Kukufe AD. Epidemiology of HIV/AIDS in Nigeria. Nig J Trop Med 1998; 7: 8-10.
4. Hunter DJ. AIDS in subsaharan Africa: The epidemiology of heterosexual transmission and the prospects for prevention. Epidemiology 1993; 4: 63-72.
5. Clark SJ, Saag MS, Decker WD et al. High titres of cytopathic

- virus in plasma of patients with symptomatic primary HIV 1 infection. *NEJM* 1991; 324: 954–60.
6. **Tindall B, Cooper DA.** Primary HIV infection: Host responses and intervention strategies. *AIDS* 1991; 5: 1–14.
 7. **Van de Perre P, Simonon A, Msellati P et al.** Postnatal transmission of human immunodeficiency virus type 1 from mother to infant: a prospective cohort study in Kigali, Rwanda. *NEJM* 1991; 325: 593–8.
 8. **Ryder RW, Nsa W, Hassig SA et al.** Perinatal transmission of the human immunodeficiency virus type 1 to infants of seropositive women in Zaire. *NEJM* 1989; 320: 1637–42.
 9. **Mackay CR, Marston W, Dudler L.** Altered patterns of T cell migration through lymph nodes and skin following antigen challenge. *Eur J Immunol* 1992; 22: 2205–10.
 10. **Barr C, Lopez M, Rau-Dobles A et al.** HIV associated oral lesions: immunologic, virologic and salivary parameters. *J Oral Pathol Med* 1992; 21: 295–8.
 11. **Ficarra G, Barone R, Ganglioti D.** Oral hairy leukoplakia among HIV positive intravenous drug abusers: A clinicopathological and ultrastructural study. *Oral Surg Oral Med Oral Pathol* 1988; 421–6.
 12. **Greenspan JS, Greenspan D, Winkler JR.** Diagnosis and management of the oral manifestations of HIV infection and AIDS. *Infect Dis Clin North Am* 1988; 2: 373–85.
 13. **Byland DJ, Zeigner UH, Hooper DG.** Human immunodeficiency virus Western Blot tests: comparison and considerations. *Ann Clin Lab Sci* 1990; 20: 343–6.
 14. **Klein RS, Harris CA, Small CR et al.** Oral candidosis in high risk patients as the initial manifestation of the AIDS. *NEJM* 1984; 311: 354–8.
 15. **Abdulrazaq GH, Ismail BK, Usman IG, Olatunde BOM, Onyemelukwe D.** Clinical manifestation of HIV infection in Northern Nigeria and its relationship to CD 4 + T cell counts. *Nig Med Pract* 1998; 35: 3–7.
 16. **Tindall B, Bavar S, Donovan B et al.** Characterisation of the acute clinical illness associated with human immunodeficiency virus infection. *Arch Intern Med* 1988; 148: 945–9.
 17. **Akinsete I.** Clinical management of HIV / AIDS: The story so far. *Nig J Med* 1998; 7: 16–20.
 18. **Dismukes WE.** Azole antifungal drugs: old and new. *Ann Intern Med* 1988; 109: 177–9.
 19. **Larsen RA.** Azoles and AIDS. *J Infect Dis* 1990; 162: 727–30.
 20. **Idoko JA.** Management of opportunistic infections and malignancies in HIV / AIDS patient. *Nig J Med* 1998; 7: 21–4.