

Evaluation of radiographic features of embedded primary molar roots in adult Turkish population

ME Çiftçi, E Haştar¹, AM Aktan

Departments of Oral and Maxillofacial Radiology, Gaziantep University, Gaziantep, Turkey, ¹Suleyman Demirel University, Isparta, Turkey

Abstract

Background: The roots of primary molars were found in the permanent dentition without symptoms on the clinical or radiographic examination. However, their incidence could not be achieved on the current literature.

Objective: The aim of this study is to evaluate the radiographic features of the embedded primary molar roots in adult dentulous patients in Turkey.

Materials and Methods: The data, from 5000 adult patients, including panoramic radiographs and demographic information, were evaluated retrospectively. The prevalence and location of the primary molar roots in the jaws were determined, as well as the prevalence and location of the primary molar roots in the adjacent permanent root levels.

Results: Among 5000 Turkish population dentulous patients, 20 retained primary molar roots (0.38%) were found in 19 ones.

Conclusions: The prevalence of the primary molar roots in the present study was found to be lower than that of the previous study. This finding may result from the larger amount of patient data that was evaluated in this study, which used panoramic radiographs.

Key words: Ankylosis, panoramic radiography, primary molar root

Date of Acceptance: 20-May-2014

Introduction

Panoramic radiography is an imaging technique that shows the facial structures, including both dental arches with their supporting structures, in a single image. These radiographs are most useful from a clinical perspective when broad coverage of the jaws is needed for diagnosis.^[1] Several incidental findings can also be seen on the panoramic radiographs. Some of these findings are carotid artery calcification, impacted teeth, variants in anatomical landmarks, foreign bodies, and retained root fragments.^[2-5]

A retained root is identified by its shape, the associated root canal, and the surrounding periodontal ligament space. These are common findings appearing as radiolucent landmarks on the radiographs, usually not accompanied by any symptoms or complaints.^[6] Although the literature

contains several studies related to the permanent retained root, very limited amount of data were found about embedded primary molar roots in the jaws of adult patients. While Worth explains the radiographic appearance of the primary molar roots,^[7] Saini *et al.* determine their prevalence using a very limited number of subjects.^[8]

Even though, embedded molar roots have come across as incidental radiographic findings without any symptoms, these roots can cause difficulties in some dental treatments, such as orthodontics and dental implants. For these reasons, it is important that the situations be assessed using the most recent data and a larger number of subjects. The aim of this study is to evaluate the radiographic features

Address for correspondence:

Dr. Mehmet Ertuğrul Çiftçi,
Departments of Oral and Maxillofacial Radiology,
Gaziantep University, Gaziantep 27310, Turkey.
E-mail: mertugrulciftci@hotmail.com

Access this article online

Quick Response Code:	Website: www.njcponline.com
	DOI: ***
	PMID: *****

of embedded primary molar roots in adult dentulous patients in Turkey and also to determine the prevalence of the embedded primary molar roots.

Materials and Methods

The present survey viewed panoramic radiographic records from 5000 adult dental patients in Turkey. Panoramic radiographs were taken from all of the adult patients, during routine control and when they were being treated for various dental problems, between 2008 and 2012, at the Department of Dentomaxillofacial Radiology, at Gaziantep University's Faculty of Dentistry. The male and female patients evaluated in this study ranged in age from 18 to 80 years.

The evaluation conditions were that the patients had no primary or mixed dentition and possessed first and second premolars in analyzed regions of their jaws. The panoramic radiographs were taken using Orthophos XG5® (Sirona, Bensheim, Germany) panoramic device, operated by a Rontgen technician who had 3 years of experience. The panoramic radiographs were evaluated by two radiologists in dark ambience, and a third radiologist was consulted as well.

The prevalence of the embedded primary roots was determined based on the 5000 patients. The images of the roots were analyzed to determine their presence or that of a periodontal ligament space. The absence of the space would indicate ankylosis. The determination of a root canal and the presence of a periodontal ligament space were used as markers to differentiate between embedded root fragments and focal idiopathic sclerosis. Embedded roots were located according to their position in the maxilla and mandible jaws or right and left sides.

Results

Among 5000 dentulous Turkish patients, 20 retained primary molar roots (0.38%) were found in 19 individuals. All but one of these patients had just one retained root fragment. Out of the 20 primary molar roots, 9 were found in females and 11 were in males; the female/male ratio was found to be 1/1.2. The mean age of the patients who had primary molar roots was 31.05 ± 14.23 . There were 13 retained roots observed in the mandibular left quadrant and seven retained roots seen in the mandibular right quadrant [Figure 1].

Four primary molar roots were found in the apical third of the adjacent permanent root [Figure 2], 10 were in the middle third of the adjacent permanent root [Figure 3], three were in the coronal third of the adjacent permanent root [Figure 4], and three were found in the gingiva, outside the region of the alveolar bone [Figure 5].

The presence of the periodontal ligament space surrounding the root fragment was found in 14 (70%) of the radiographs. The six retained fragments showed missing lamina dura and direct continuity of the bone, called as bony ankylosis.

Discussion

Retained molar roots, which are mainly incidental findings in radiographic examination, cause some clinic problems for dentists, such as foreign bodies, radiopacities, mental foramen crests, osteosclerosis, soft tissue calcification, and metallic objects.^[4,5,9] Several authors have researched the permanent dentition; however, only one article that relates to the primary dentition was found through a PubMed search. For that reason, this study has critical importance in terms of adding new data about retained primary molar roots.

While most of the articles that relate to retained roots are about permanent teeth and involve edentulous patients, studies that relate to retained primary roots and dentulous patients have been included. The incidence of permanent retained roots ranges from 1.2% to 40.5% in the different population.^[9-12] The incidence of primary roots was found to be 7.33 in 300 patients.^[8] In the current study, this proportion was found to be 0.38. However it looks as if Saini's findings agree with the literature that relates to permanent roots, although they do not correspond with the findings of the present study. The difference between this study and the literature may result from the use of panoramic radiography, which shows us a broader region than periapical radiography. In addition, racial differences may also contribute to the difference.

Retained deciduous roots present no problems as long as a healthy attachment apparatus exists in the coronal part of the root fragment. If, however, a periodontal disease process should occur, the deepening sulcus and plaque front would soon encounter the root tip. Considering the problems that could occur, it is important that such root tips be removed when the primary tooth exfoliates. The results of the present study show only one case that was inflammatory (5%), and extraction of the primary molar roots was considered in six (30%) of the 20 cases. A dentist who is treating patients should be alert to this possibility and should perform a thorough clinical and radiographic examination. If these primary molar roots are allowed to remain in the oral cavity, periodontist should be aware of their presence and modify the treatment plan accordingly.^[13]

Differential diagnosis of retained roots can be periapical cemental dysplasia, idiopathic osteosclerosis, and condensing osteitis. The primary retained roots diagnosed in the current study have distinguishing features from the periapical cemental dysplasia, in terms of their location

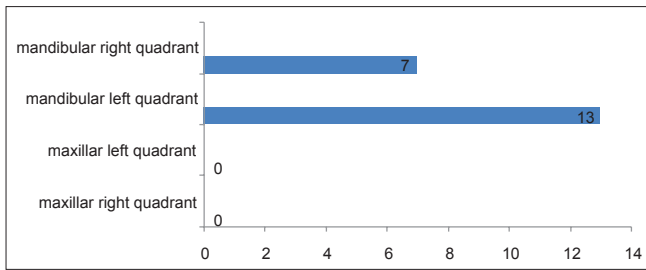


Figure 1: Distribution of retained primary molar roots in four quadrants

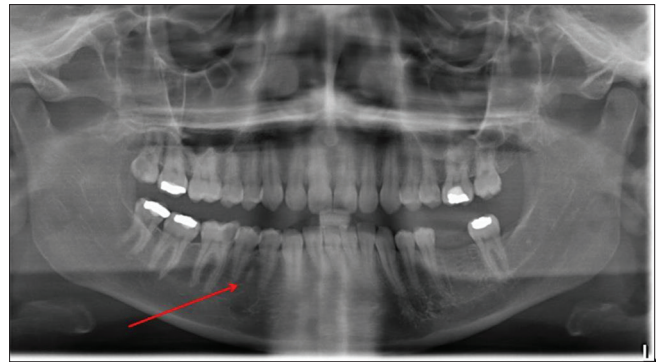


Figure 2: Retained primary molar root in the apical 1/3 of the adjacent permanent root

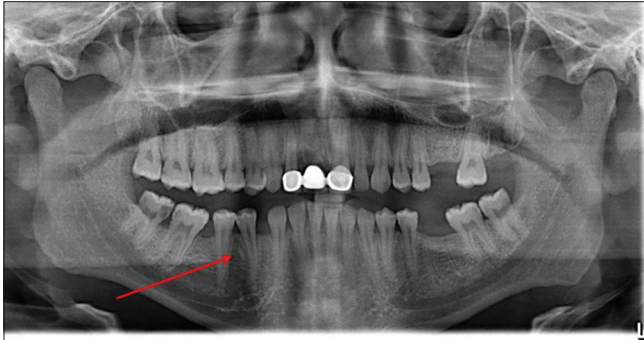


Figure 3: Retained primary molar root in the middle 1/3 of the adjacent permanent root

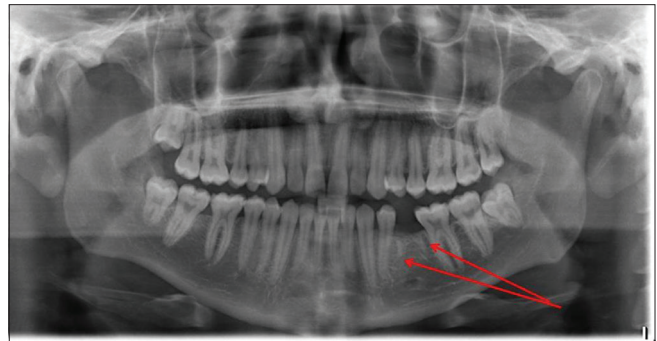


Figure 4: Retained primary molar root in the coronal 1/3 the adjacent permanent root

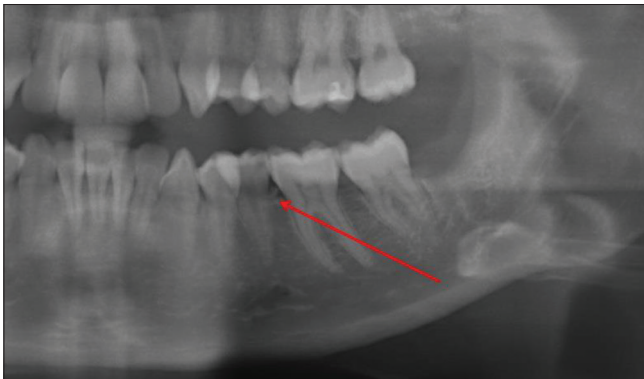

Figure 5: Retained primary molar root in the gingiva, outside the region of the alveolar bone

in the periapical region and their characterization through replacement of normal bone with fibrous tissue. Furthermore, idiopathic osteosclerosis was differentiated from the retained roots because the round and elliptical radiopaque areas increased bone production in the jaw.^[1] Finally, condensing osteitis was outside of the periodontal space and the lamina dura. Consequently, the primary retained roots that were diagnosed radiographically were as accurate as possible in this study.

This study looks to be more recent and current than the only other study about retained primary roots in the literature and shows many differences in comparison to the previous study. While 300 patients were used in the study by Saini *et al.*,^[8] data from 5000 patients were used, so that the

results reflect a larger population. Periapical radiography, which was used in the past study, shows only a few teeth and their surrounding tissues. Panoramic radiography, which is superior to periapical radiography, shows both jaws comprehensively and prefers to overlook any root structures. Therefore, it is thought that the present study makes a contribution to the literature by showing new and comprehensive data.

There are some advantages and disadvantages to panoramic radiography.^[1,14] The superimposition of structures is the one of the disadvantages related to the study. Superimposition in the permanent premolar region, which is the localization of the primary molar roots, increases the difficulties in the diagnosis of the structures. The advantages, however, include low patient doses, high patient acceptability, and short imaging times. The limitations of this technique are the lack of fine anatomical detail, the superimposition of structures, magnification, and the high initial setup costs.^[1]

Embedded root fragments without an associated radiolucent area do not usually require surgical intervention. However, the need for routine radiographic examination is explained to patients and also the possible complications, such as acute situations resulting from the presence of these fragments. If the retained root is associated with a radiolucent area, the root should definitely be removed. If it is not removed,

the root may become infected and serious problems could occur. Nyssönen *et al.* have proposed that infected retained roots may act as an additional health hazard and that they should be extracted or otherwise treated. Therefore, it is important to know the magnitude of the problem within any given population.^[14]

Since 75% of the patients were aged 30 years or younger, showing early loss of premolar teeth after the age of 30, we excluded patients with missing premolar teeth. Of the 20 retained primary roots, 17 were found to be impacted without any symptoms in the present study. This data might indicate a lack of eruptive force or appositional growth of the alveolar process in an occlusal direction as being contributing factors. Bony ankylosis was seen in six teeth (30%). This ratio suggests that the criteria for radiographic interpretation of ankylosis used in this survey may minimize the true prevalence of ankylosis because of the inefficiency of panoramic radiography in terms of visualization of space for the periodontal membrane and lamina dura.

Conclusion

The prevalence of the primary molar roots in the present study was found to be lower than that of the previous study. This finding may result from the larger amounts of patient data that were evaluated using panoramic radiography. In addition, the dentists may encounter some clinical problems in cases where there are retained primary roots. Prevalence of 0.38% of deciduous molar roots was encountered in Turkish dentate individuals. Dental practitioners should be aware of this and the possible related facts.

References

1. Stuart C, White MJ. Oral Radiology: Principle and Interpretation. 3rd ed. St. Louis: Mosby; 2003.
2. Friedlander AH, Chang TI, Aghazadehsani N, Berenji GR, Harada ND, Garrett NR. Panoramic images of white and black post-menopausal females evidencing carotid calcifications are at high risk of comorbid osteopenia of the femoral neck. *Dentomaxillofac Radiol* 2013;42:20120195.
3. Gupta S, Bhowate RR, Nigam N, Saxena S. Evaluation of impacted mandibular third molars by panoramic radiography. *ISRN Dent* 2011;2011:406714.
4. Masood F, Robinson VV, Beavers KS, Haney KL. Findings from panoramic radiographs of the edentulous population and review of the literature. *Quintessence Int* 2007;38:e298-305.
5. Awad EA, Al-Dharrab A. Panoramic radiographic examination: A survey of 271 edentulous patients. *Int J Prosthodont* 2011;24:55-7.
6. Chung MP, Chen CP, Shieh YS. Floating retained root lesion mimicking apical periodontitis. *Oral Surg Oral Med Oral Pathol Oral Radiol Endod* 2009;108:e63-6.
7. Worth HM. Principles and Practice of Oral Radiologic Interpretation. 1st ed. Chicago: Year Book Medical Publishers; 1963.
8. Saini T, Kharat DU, Keene J. A retrospective radiographic survey of embedded primary molar roots in Saudi adult patients. *ASDC J Dent Child* 1998; 65:32-5.
9. Sumer AP, Sumer M, Güler AU, Biçer I. Panoramic radiographic examination of edentulous mouths. *Quintessence Int* 2007;38:e399-403.
10. Jindal SK, Sheikh S, Kulkarni S, Singla A. Significance of pre-treatment panoramic radiographic assessment of edentulous patients – A survey. *Med Oral Patol Oral Cir Bucal* 2011;16:e600-6.
11. Barclay JK, Donaldson KI. Panoramic radiography of the edentulous jaws – A survey of 100 patients. *N Z Dent J* 1970;66:53-60.
12. Kharat DU, Saini TS, Mokeem S. Shovel-shaped incisors and associated invagination in some Asian and African populations. *J Dent* 1990;18:216-20.
13. Wheeler RC. A Textbook of Dental Anatomy and Physiology. 4th ed. Philadelphia: W B Saunders Company; 1965.
14. Nyssönen V, Paunio I, Rajala M. Prevalence of retained roots in the Finnish adult population. *Community Dent Oral Epidemiol* 1983;11:117-21.

How to cite this article: ???

Source of Support: Nil, **Conflict of Interest:** None declared.