

## THE UNERUPTED MAXILLARY CANINE - A REVIEW OF LITERATURE

O. O. daCosta

*Department of Medicine, Child Dental Health, College of Medicine, University of Lagos, Lagos*

### ABSTRACT

The purpose of this paper is to bring about a better appreciation of causative factors and those influencing management decisions of the unerupted maxillary canine. It reviews current literature of the anomaly of the unerupted maxillary canine, which is one of the most frequently displaced teeth in the maxillary arch.

Aetiological factors of this anomaly are widely varied and include advanced state of development at an early age, trauma, dento-alveolar disproportion, absence or reduction in size of the upper lateral incisor and genetics. The possible complications of canine impaction are also discussed. Methods of assessing the unerupted canine both clinically and radiographically are highlighted along with ways of predicting and preventing the anomaly. Finally it details management of the problem including factors to be taken into consideration prior to treatment and the various treatment options available to date.

The need for early assessment of patients presenting in the dental clinic cannot be over-emphasized in the possible prevention of this anomaly. The observation of one or more of the possible causative factors as well as delayed eruption of the permanent canine or prolonged retention of its predecessor should also be cause for further investigation. Choice of the various treatment options available is dependent on a number of factors including patient's attitude, the position of the unerupted tooth relative to the standing teeth as well as the present occlusion of the patient.

**KEY WORDS:** *Maxillary Canine, Unerupted, Review*

### INTRODUCTION

The permanent maxillary canine is a key tooth in the maxillary dentition. It is infrequently damaged by contact sports and is a useful abutment tooth<sup>1</sup>. The maxillary canine has a lower mortality rate than the first premolar and has an important anatomic and cosmetic function. It is one of the most frequently displaced teeth in the dental arch, second only to the third molars in frequency of impaction<sup>2-4</sup>. Failed eruption of the maxillary canine has been reported to occur in 1.5-2.0% of selected populations in the Western world<sup>1,5,6</sup>. The findings among the general populace in this region show a slightly lower occurrence of 1.5-1.8%<sup>7,8</sup>. In Nigeria, this anomaly has been reported to occur in approximately 2% of orthodontic patients<sup>9,10</sup>. Failure of eruption of the maxillary canine occurs bilaterally in up to 27% of affected persons in Western populations<sup>1,5,11</sup>, while it is reported to occur in 33% in a study of a Nigerian population<sup>10</sup>. Among Caucasians, palatal displacement of the unerupted canine occurs in the majority of cases with a ratio ranging from 2.5:1 to 12:1 in relation to buccal displacement<sup>1,5,11-14</sup>. However, Buccal displacement has been reported to occur far more frequently than palatal among Orientals<sup>14</sup>, while in Nigerians the ratio of palatal to buccal displacement is much reduced<sup>10</sup>. The unerupted canine has also been reported to occur more frequently in females than males in both the general and

selected populations<sup>5,8,15</sup>.

The management of this anomaly usually requires the expertise of the orthodontist who together with the oral surgeon is often responsible for bringing the unerupted tooth into its correct position in the dental arch.

The purpose of this paper is to review current literature on the normal development, aetiology, complications, clinical assessment and management of the unerupted maxillary canine. It is hoped that this will result in a better appreciation of the factors that influence management decisions.

#### *Normal development of the permanent maxillary canine*

This has been well documented by Broadent<sup>16</sup> and Moyers<sup>17</sup>. Calcification of the crown of the permanent maxillary canine begins at 4 to 5 months of age. By the age of one year it is high in the fronto-nasal process of the maxilla, beneath the floor of the orbit and above the bifurcation of the first primary molar. With eruption of the primary teeth the canine crypt rapidly migrates forward in the maxilla and by the age of 3 years the crown is mesially and lingually directed, lying just above the apex of the primary canine. Calcification of the crown is completed at approximately 6 to 7 years and by 7 years of age root development begins. As the root moves downwards towards the occlusal plane, the crown lies in close proximity to the root of the lateral incisor. It travels down the distal aspect of the root emerging into the mouth at about 11 to 12 years of age. As the canine erupts,

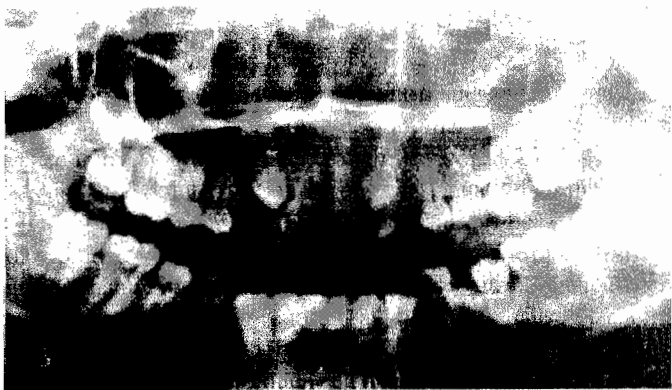\*Correspondence: Dr. O. O. daCosta

pressure is exerted on the distal surface of the lateral incisor root, which causes its crown to become distally inclined. This results in a typical splayed appearance of these teeth often resulting in a physiological midline diastema – the ‘ugly duckling’ stage occurring at 8 to 9 years.

In the lateral plane the canine shows significant movement in the buccal direction between 10 and 12 years of age. Before this, movement occurred in a palatal direction.<sup>18</sup> Another radiological study showed that the upper canine initially erupts with increasing mesial inclination until a maximum point is reached. This is followed by gradual straightening distally which occurs at approximately 9 years of age<sup>19</sup>. By 12 years of age the canine has usually reached occlusion, the laterals incisors have uprighted with closure of the midline spacing. At the time of eruption, three-quarters of root formation has occurred and this is usually complete within two years of eruption.

### **Aetiological factors**

Moss observed that the frequent displacement of the canine is probably due to its high developmental position and advanced state of development of the crown at an early age<sup>20</sup>. Bishara et al pointed out numerous causes including the rate of resorption of primary teeth, trauma to the primary tooth bud, disturbance of tooth eruption sequence, rotation of tooth buds and premature root closure<sup>21</sup>. Early trauma to the permanent incisor teeth has also been reported as a possible cause of canine impaction<sup>22</sup>. Several authors implicated crowding or lack of space within the arch as a frequent cause of canine impaction<sup>1,5,7,21</sup>. This usually results in buccal displacement (Fig. 1). Jacoby<sup>13</sup> however noted that in 85% of palatal impactions there was adequate space to allow for eruption of the canine. This finding is supported by a recent finding showing that patients with (impacted) palatally displaced canine had significantly smaller than average teeth<sup>23</sup> and are therefore likely to have adequate arch space. However, the results of a related study showed no statistically significant differences between arch size of patients with palatally impacted canines and a control sample<sup>24</sup>.



**Fig. 1: A Panoramic x-ray of a 14 year old boy showing bilateral impaction of the maxillary canines.**

The lateral incisor acts as a guide for the erupting canine, thus absence or reduction in size of the adjacent lateral incisor may lead to failed eruption or displacement of the maxillary ca-

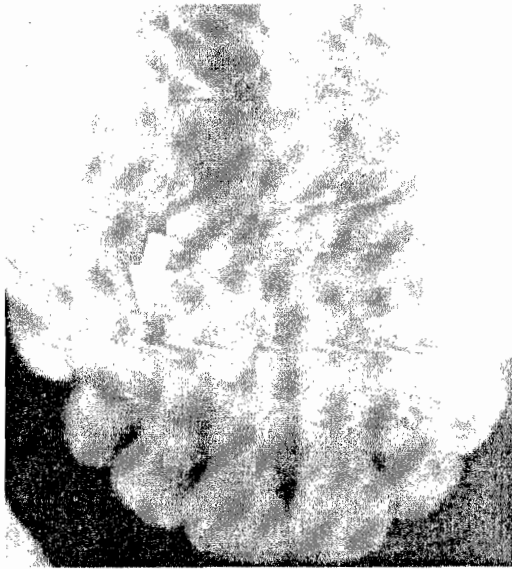
nine<sup>3,7,14</sup> (Fig 2). A study comparing canine impaction in patients with a missing lateral incisor on one side and a peg-shaped lateral incisor on the contralateral side showed that failed eruption occurred far more frequently on the side of the diminutive lateral incisor than on the side with the missing lateral incisor<sup>25</sup>. It has been suggested that a possible cause for this is that agenesis of the lateral incisor would allow for normal uprighting of the canine seen in the later stages of development thus reducing the frequency of canine impaction in these cases.<sup>19</sup> Findings by Peck et al<sup>26</sup> showed a highly significant increase in peg shaped laterals among patients with palatally impacted canines. While Becker et al<sup>27</sup> reported an increase of 2.4 times in the incidence of impacted canines adjacent to the sites of missing lateral incisors as compared with the general population, a recent study<sup>28</sup> showed that the prevalence of congenitally missing permanent teeth in patients with unerupted canines was 35.8%. This was observed to be 4.5 times that of the normal population. In the same study it was also concluded that failed eruption of the maxillary canine was genetic in origin and related to incisor/premolar hypodontia in first and second-degree relatives. Bass<sup>5</sup> suggested that both missing teeth and ectopic canines are caused by the same disturbance of the dental lamina. Similar findings were also reported in another study whereby a highly significant increase in the absence of 3<sup>rd</sup> molars and 2<sup>nd</sup> premolars was associated with impacted canines<sup>26</sup>. McSherry and Richardson<sup>29</sup> observed in their study that the unerupted canine always travelled in a palatal direction and failed to demonstrate the late buccal movement, which normally occurs at 10 to 12 years of age. In addition they noted a significant reduction in the vertical growth of ectopic canines on the left and right sides at ages 7 to 12 and 9 to 11 years respectively.



**Fig. 2: An unerupted upper left canine associated with peg-shaped lateral incisors in a 19-year old female.**

Follicles of ectopically erupting canines have been reported to be larger and more asymmetric in shape than those of normally erupting canines<sup>30</sup>. Unerupted canines may also be seen in con-

ditions where there is generalized failure of the teeth to erupt e.g. Cleidocranial dysostosis, Hypopituitarism and Cleft Palate. It is also known to be associated with the occurrence of supernumerary teeth. Other local causes of non-eruption include the presence of cysts, odontomes, tumours and scar formation in the eruptive path<sup>3</sup> (Fig. 3).



**Fig. 3: Failed eruption of the upper right canine due to the presence of an odontome in the path of eruption seen in a 16 year old female.**

### Complications

Complications associated with unerupted maxillary canines include dentigerous cysts, resorption of incisor roots and coronal resorption of the unerupted canine.

Dentigerous cysts may occur as a complication of the unerupted canine whereby there is fluid accumulation between the tooth and the reduced enamel epithelium. It may cause displacement of the tooth and destruction of bone<sup>31</sup>. Hitchin<sup>32</sup> reported that 7.3% of impacted canines in his study were associated with dentigerous cysts. Resorption of the roots of the lateral incisors and less frequently the central incisors is believed to occur during the eruptive phase of the canine. It has been reported to occur as early as 9 years with peak frequency between 11 and 12 years<sup>33</sup>. The occurrence of root resorption beyond the age of 15 years is unusual<sup>34</sup>. Incisor resorption has been reported in 1-47% of cases with canine impaction occurring more frequently among females<sup>1,2,5,8,33</sup>. Ericson and Kurol<sup>8</sup> noted that conventional tomography doubled the number of teeth with diagnosed resorption compared to intraoral films and panoramic radiographs alone. It also gave a more reliable indication of the extent of the lesion essential for therapeutic decision. The introduction of Computerized Tomography (CT) eliminated the blurring problem of conventional tomography and increased perceptibility of root resorption substantially<sup>35</sup>. The incidence of root resorption has been reported to increase when the lateral incisor is of normal size<sup>36</sup>. Resorption appears most frequently on the middle and apical third of the injured incisors and is seen as commonly on the buccal as on the lingual root surfaces. It is also reported that resorption is often severe with frequent pulpal involvement<sup>34,37</sup>.

However, clinical signs and symptoms are rarely reported by patients<sup>37</sup>.

Very rarely, resorption of the premolar roots by impacted canines may occur<sup>38</sup>.

Coronal resorption of the maxillary canine is another possible complication of long standing impaction. Azaz and Shteyer<sup>39</sup> reported a 14% occurrence of resorption among the impacted canines seen in their study. Complete impaction over a long period of time was an important aetiological factor. Most cases were seen in patients of 40 years and above. It has been suggested that local inflammatory factors such as non-vital teeth, periodontal pockets or chronic irritation from dentures may act as predisposing factors leading to the destruction of enamel epithelium and initiation of enamel resorption. Diagnosis of coronal resorption is usually discovered on routine radiograph, the appearance resembling caries. This process is usually asymptomatic. External resorption of the crown occurs more frequently than root resorption and occasionally the whole tooth may be destroyed without symptoms. However, due to the difficulty in removing the tooth in this condition Seddon and Smith<sup>40</sup> concluded that only in cases where it is necessary should this be done e.g. cystic change, fitting of prostheses or presence of symptoms.

### Diagnosis

The diagnosis of the unerupted canine should be based on both clinical assessment and radiographic investigations.

### Clinical assessment

Normal eruption of the maxillary canine usually occurs at 11-12 years of age in females and 11-13 years of age in males. Delayed eruption of the permanent canine or prolonged retention of the deciduous canine beyond the age of 14 to 15 years of age may be indicative of canine impaction<sup>41</sup>. Also failure of a maxillary canine to erupt within a year following eruption of the contra lateral tooth may require further investigations. Inspection of the mouth may show the presence of a visible bulge on the buccal or palatal mucosa produced by the crown of the unerupted canine. It will also enable the clinician to determine the availability of space in the arch for the unerupted tooth. Furthermore, the presence of retained primary or supplemental lateral incisor should be determined. The position of the lateral incisor is a valuable indicator of the position of the unerupted canine<sup>19,42</sup>. Pressure from the canine to the root of the lateral incisor often results in displacement of the crown. A distally inclined crown indicates pressure on the distal part of the apex of the lateral incisor, while a labially flared lateral incisor indicates labial pressure on the root of the tooth indicating buccal displacement of the unerupted canine. Very rarely the position of the central incisor may be affected by the unerupted canine<sup>42</sup>.

Palpation of the Buccal or palatal bone may reveal the position of the unerupted tooth. In the presence of a retained primary canine, palpation may exhibit some degree of mobility of the tooth indicating root resorption. Similarly mobility of the lateral incisor due to resorption may be noted. If a canine is palpable in an abnormal position or cannot be palpated radiographs are required for its localization.

## **Radiographic Investigations**

Radiographs may be taken in two planes to give a three-dimensional impression of the unerupted tooth as well as to assess the adjacent structures. Proper localization of the impacted tooth plays a critical role in determining the feasibility of, as well as the proper access for the surgical approach and proper direction for the application of orthodontic forces.

Rayne<sup>1</sup> reported that radiographs provide the following information:

- a. The position of the canine buccal, palatal or in line with the arch.
- b. A pathological condition in association with the crown of the canine e.g. crown resorption, cyst formation or incisor root resorption.
- c. The form of the apex of the canine root and its position relative to the roots of the standing teeth.
- d. The obliquity of the axis of the canine.
- e. The antero-posterior position of the apex of the canine.

**Periapical radiograph** – This shows the position of the canine relative to the roots of the adjacent teeth in the antero-posterior dimension. It shows the degree of root formation of the unerupted canine and the presence of any local pathology e.g. odontome, possible cystic changes and the extent of root resorption of the adjacent teeth.

**Parallax localization** – This technique of localization employs the use of two films and a shift between each exposure. Two films are placed successively in the same position and exposed using two different directions of the x-ray tube. There is usually a 20-30 degree shift between each exposure. If the objects are observed at different angles their relative positions change due to parallax. The more distant object travels in the same direction while the nearer object travels in the opposite direction. Parallax technique may be carried out using periapical, occlusal or panoramic radiographs. It should be noted however, that a buccally or labially placed object moves with the tube in a panoramic x-ray as the tube is situated behind the patient.

**Vertex occlusal** – This radiograph is taken with the x-ray parallel to the long axis of the central incisors. It provides a plan view of the maxillary teeth and permits bucco-palatal localization in this region. A disadvantage of this view however is the exposure to a high dose of radiation<sup>3,43</sup> and loss of detail<sup>44,42</sup>.

**Postero-Anterior and Lateral Cephalometric X-rays** – In the postero-anterior cephalometric radiograph the relationship of the crown of the canine to the midline and the lateral relationship of the root apex to the standing teeth may also be seen. From the lateral radiograph the relationship of the crown of the canine to the incisor roots, its height above the occlusal plane and obliquity of the long axis can be noted<sup>44,45</sup>.

**Panoramic radiograph** – Dental panoramic radiographs are the most likely first choice of radiographs to be taken in assessment of patients for orthodontic treatment<sup>46</sup>. The use of this radiograph often allows for early determination of possible canine impaction from routine mixed dentition radiographs. Lindauer observed that when the canine cusp tip overlaid the distal half of the lateral incisor root on panoramic radiograph a canine impaction is usually present<sup>47</sup>. In the panoramic radiograph, objects

placed palatal to the image layer appear excessively magnified in the horizontal plane while buccally located objects appear proportionately diminished. Diagnosis of labio-palatal location of the unerupted maxillary canines on the basis of magnification in this radiograph was found to be accurate in 80-90% of cases<sup>48,49</sup>. This radiograph may therefore be considered a useful indicator in the location of the unerupted canine. Image magnification however, is considered a less accurate method of radiographic localization when compared to parallax technique<sup>42</sup>.

**Computerized Tomography (CT)** – This is a three-dimensional imaging method that has been proved superior to other radiographic methods in visualizing bone tissue. Computed Tomography overcomes the limitations of conventional radiographic methods and has been proved to be a useful method for diagnosing the positions and complications of ectopically erupting teeth<sup>33</sup>. However, a disadvantage of CT is the relatively high radiation dose to the patient<sup>42</sup>. Preda et al concluded that CT should be limited to cases where conventional radiography poorly depicts the actual relationship between the impacted tooth and roots of the adjacent teeth and in cases where the anatomical situation is complex<sup>50</sup>.

While a number of radiographic views are recommended for localization of the unerupted canines there is the disadvantage of limited availability in this environment. Simple parallax technique using periapical radiographs in addition to a standard occlusal view are often sufficient for localization of the tooth.

## **Prediction and prevention of canine impaction**

Between 8 and 9 years of age the maxillary canine is easily located on lateral radiograph. The crown should be positioned near the apex of the primary canine root with the crown inclined medially in relation to the root. In frontal radiographs the canine should be inclined only slightly medially with the crowns below the level of the apices of the lateral incisors. Clinically, at this age a bulge is normally palpable high in the alveolar process above the primary canine<sup>51</sup>. If the normal canine bulge cannot be palpated by 11 years of age ectopic eruption should be suspected and radiographic examination is indicated<sup>52</sup>. Examination of panoramic radiographs in young children has shown that the majority of palatally impacted canines present with cuspal tips overlapping or mesial to the lateral incisor<sup>47</sup>. However, it has been reported that this sign should only be considered applicable after complete development of the lateral incisor root<sup>19</sup>. Williams<sup>51</sup> suggested that radiographs showing abnormal findings such as these and clinically absent bulges should be under serious consideration for removal of the maxillary primary canine. He reported that extraction of primary canines has been shown to bring about spontaneous correction of permanent canine positions in many cases with their eruption into positions requiring little or no further mechanotherapy. Subsequent studies have confirmed this belief. Early removal of primary canines was shown to correct the eruptive position of 62-78% of palatally displaced canines within a 6-12 month period<sup>53,54</sup>. The outcome of removal of the primary canine was noted to be dependent on the position of the permanent canine. Success was more likely in children aged 10-13 years where the horizontal overlap of the adjacent incisor by the im-

ected canine was no more than half of the tooth width. The presence of crowding also adversely affects favourable eruption of the permanent canine<sup>53,54</sup>.

## TREATMENT

Factors that need to be taken into consideration before proceeding with treatment have been outlined by Moss<sup>20</sup>. They include:

**Patient's co-operation** – The patient must be willing to undergo prolonged treatment required to align the canine. The patient should be dentally conscious and able to maintain good oral hygiene. The age and medical condition of the patient will also play a role in the decision to treat.

**Position of the unerupted tooth** – Most malpositioned upper canines are in palatal position. The apex of the canine should lie mesial to the apex of the first premolar and distal to the apex of the lateral incisor. If the apex is far from its correct position it is more difficult to bring about movement of the tooth and possibility for alignment is limited. The position of the crown relative to the adjacent teeth should be carefully located and its influence on the neighbouring teeth assessed. If the crown is firmly impacted against the tooth the prognosis for canine alignment is poor.

**Space** – There must be sufficient space available for the tooth in the dental arch either with or without planned extraction of other teeth.

**Condition of neighbouring teeth** – This should be assessed from the viewpoint of whether they will take the place of the canine tooth e.g. a primary canine with adequate crown and root or a first premolar which has moved mesially into contact with the lateral incisor.

**Occlusal relationship of the dental arches** – If space is required in the arch to reduce a Class II relationship much space can be gained from the loss of the impacted canine

## Treatment Methods

There are various treatment options for the unerupted canine.

**Leave the tooth in place** – Symptomless teeth may be left in place and observed at regular intervals to ensure that no pathological changes have taken place. This may be the treatment of choice in some adult patients and those unwilling to undergo orthodontic treatment. Also may be carried out in some medically compromised patients.

**Interceptive treatment** – This can be carried out in cases where there is failed resorption of the primary canine thereby preventing eruption of its successor. The primary tooth can be extracted in order to allow for the eruption of the permanent canine into alignment

**Exposure and orthodontic alignment** – This is usually the treatment of choice in co-operative patients where the position of the canine is favourable and space is available or has been created for the alignment of the tooth. Exposure of the unerupted tooth requires surgical intervention whereby there is minimal exposure of the tooth. Alternatively, a flap may be raised and replaced following bonding of the bracket onto the unerupted tooth. In palatally positioned canines, the entire crown may be exposed and the exposure maintained with a surgical pack. On

exposure, two structures should be safe-guarded these are the outer plate of alveolar bone and the attached gingiva. There are various methods for application of traction to the unerupted tooth, this includes the use of a gold chain consisting of many links bonded to the unerupted tooth via a bracket<sup>45</sup> or application of direct force from the bracket on the unerupted tooth via elastics or flexible wires<sup>55,56</sup>. Alternative methods of traction include the use of removable appliances whereby a traction loop is incorporated onto the Adam's clasp of the appliance<sup>57</sup> and the use of a lasso<sup>58</sup>. The lasso consists of a soft stainless steel wire – 0.5mm in diameter which is placed around the neck of the tooth. This technique is no longer recommended as it has been noted to cause irreparable damage to the periodontal tissues in the region of the unerupted tooth<sup>59</sup>. An increased incidence of ankylosis associated with external root resorption of the canine has also been reported<sup>41</sup>. The use of magnetic force as a means of traction has also been reported<sup>60,61</sup>. This involves the bonding of a small magnet onto the unerupted tooth while a second larger magnet is incorporated into a removable appliance in an appropriate position. Advantages of this technique are that few adjustments are required and the magnets can provide constant physiological force over long periods of time<sup>61</sup>.

**Exposure and allowance for spontaneous eruption** – Most useful when the canine has correct axial inclination and does not need to be uprighted during eruption<sup>41</sup>. A high success rate has been recorded using this technique<sup>62</sup>. Compared to the use of orthodontic traction it has been described as being equally efficient and reliable<sup>63</sup>.

**Repositioning** – In this method the unerupted canine is surgically exposed and repositioned by rotating it around its apex without disturbing the neurovascular bundle in the hope that the still vital tooth would continue to erupt into occlusion. Complications include loss of vitality, insufficient eruption and supra-eruption of the tooth<sup>6</sup>.

**Auto-transplantation** – This may provide a simplified and faster treatment option for patients with ectopic canines. Especially useful in adults who often reject the idea of using an appliance to align the tooth yet would benefit from positioning this tooth<sup>65</sup>. The procedure involves the surgical removal of the canine with minimal trauma and handling and creation of a socket to receive the tooth. Of vital importance is that the transplant is removed without damage to the periodontium<sup>66</sup>. The buccopalatal width of the alveolar ridge at the recipient site must also be sufficient to accommodate the transplant<sup>65</sup>. The transplanted tooth is flexibly splinted using surgical sutures, orthodontic appliances or steel ligatures for a period of approximately 1-2 weeks<sup>66</sup>. Transplantation of teeth with immature roots provides a higher success rate<sup>65</sup>, while in cases of teeth with closed apices endodontic treatment may be commenced 4 weeks after transplantation<sup>67</sup>. Possible complications of this treatment include discolouration, loss of vitality, root resorption and ankylosis<sup>20,65</sup>.

**Extraction** – This may be advocated when the canine is lying in an unfavourable position, there is insufficient space in the arch or the present occlusal relationship is satisfactory. Surgical removal of the tooth is also indicated if there is poor patient co-operation and in cases when there is evidence of early resorption of adjacent teeth or pathology affecting the tooth<sup>64</sup>.



## CONCLUSION

The unerupted maxillary canine is an anomaly that can be found quite frequently in dental practice. The need for early assessment of patients presenting both clinically and radiographically at an early age cannot be over-emphasized in the possible prevention of this anomaly. The observation of one or more of the causative factors as well as delayed eruption of the maxillary permanent canine or prolonged retention of its predecessor should be cause for further investigation. Numerous treatment options are available in its management. These are dependent on the patient's attitude, the position of the unerupted tooth relative to the standing teeth as well as the present occlusion of the patient.

Adequate knowledge of this anomaly is important to both general dental practitioners and specialists in the field in order to enable them make informed decisions in its management based on influencing factors that present.

## REFERENCES

1. **Rayne J.** The unerupted maxillary canine. *Dent Practit* 1969; 19: 194–204
2. **Howard RD.** The displaced maxillary canine. Positional variations associated with incisal resorption. *Dent Practit* 1972; 22: 279–287.
3. **Kay LW.** The impacted maxillary canine. *Dent Update* 1977; 4: 335–339.
4. **Beeching BW.** Developmental anomalies, part 2 Unerupted, impacted and misplaced teeth. *Dent Update* 1979; 16: 23–46.
5. **Bass TB.** Observations on the misplaced upper canine tooth. *Dent Practit* 1967; 18: 25–33.
6. **Mckay C.** The unerupted maxillary canine. An assessment of the role of surgery in 2,500 treated cases. *Br Dent J* 1978; 145: 207–210.
7. **Thilander B, Jacobsson SO.** Local factors in impaction of maxillary canines. *Acta Odont Scandinav* 1968; 26: 145–168.
8. **Ericson S, Kurol J.** Radiographic examination of ectopically erupting maxillary canines. *Am J Orthod* 1987; 91: 483–491.
9. **Isiekwe MC, Logan WW.** An analysis of the first 100 orthodontic patients treated in Lagos University Teaching Hospital. *Nig Dent J* 1980; 1: 1–6.
10. **daCosta OO, Isiekwe MC.** The incidence of unerupted maxillary canines in a Nigerian orthodontic population. *Nig Qt J Hosp Med* 1998; 8: 87–90.
11. **McConnell TL, Hoffman DL, Forbes DP, Janzen EK, Weintraub NH.** Maxillary canine impaction in patients with transverse maxillary deficiency. *J Dent Child* 1996; 63: 190–195.
12. **Jacoby H.** The 'ballista spring' system for impacted teeth. *Am J Orthod* 1979; 72: 143–151.
13. **Jacoby H.** The etiology of maxillary canine impactions. *Am J Orthod* 1983; 84: 125–132.
14. **Olliver REG, Mannion JE, Robinson JM.** Morphology of the maxillary incisor in cases of unilateral impaction of the maxillary canine. *Br J Orthod* 1989; 19: 9–16.
15. **Kuftinec MM, Stom D, Shapira Y.** The maxillary canine I. Review of concepts. *J Dent Child* 1995; 62: 317–324.
16. **Broadbent BH.** Odontogenic development of occlusion. *Angle Orthod* 1941; 11: 223–241.
17. **Moyers RE.** *Handbook of Orthodontics (4<sup>th</sup> Edition)* Yearbook Medical Publishers inc. 1988: 140.
18. **Coulter J, Richardson A.** Normal eruption of maxillary canine quantified in three dimensions. *Eur. J. Orthod* 1997; 18: 449–456.
19. **Fernandez E, Bravo LA, Canteras M.** Eruption of the permanent upper canine: A radiologic study. *Am J Orthod* 1998; 113: 414–420.
20. **Moss JP.** The unerupted canine. *Dent Practit* 1972; 22: 241–247.
21. **Bishara SE, Kommer DD, McNeil MH, Montagano LN, Oesterle LJ, Youngquist HW.** Management of impacted canines. *Am J Orthod* 1976; 69: 371–387.
22. **Brin I, Solomon Y, Zilberman Y.** Trauma as a possible etiologic factor in maxillary canine impaction. *Am J Orthod Dentofac Orthop* 1993; 104: 132–137.
23. **Langberg BJ, Peck S.** Tooth size reduction associated with occurrence of palatal displacement of canines. *Angle Orthod* 2000; 7: 126–128.
24. **Langberg BJ, Peck S.** Adequacy of maxillary dental arch width in patients with palatally displaced canines. *Am J Orthod Dentofacial Orthop* 2000; 118: 220–223.
25. **Becker A, Gillis I, Shpack N.** The aetiology of palatal displacement of maxillary canines. *Clin Orthod Res* 1999; 2: 62–66.
26. **Peck S, Peck L, Kataja M.** Prevalence of tooth agenesis and peg-shaped maxillary lateral incisor associated with palatally displaced canine (PDC) anomaly. *Am J Orthod Dentofac Orthop* 1996; 110: 441–443.
27. **Becker A, Smith P, Behar R.** The incidence of anomalous lateral incisors in relation to palatally displaced cuspids. *Angle Orthod* 1981; 51: 24–9.
28. **Pirinin S, Arte S, Apajalahti S.** Palatal displacement of canine is genetic and related to congenital absence of teeth. *J. Dent Res* 1996; 75: 1742–1746.
29. **McSherry P, Richardson A.** Ectopic eruption of the maxillary canine quantified in three dimensions on cephalometric radiographs between the ages of 5 and 15 years. *Eur J Orthod* 1999; 21: 41–48.

30. **Ericson S, Bjerklin K.** The dental follicle in normally and ectopically erupting maxillary canines: A computed tomography study. *Angle Orthod* 2001; 71: 333–342.
31. **Shafer WG, Hine MK, Levy BM.** *A Textbook of Oral Pathology* (4th Edition). WB Saunders Company Philadelphia, London, Toronto. 1983; pp 68, 260.
32. **Hitchin AD.** The impacted maxillary canine. *Br Dent J* 1956; 100: 1–14.
33. **Ericson S, Kurol J.** Resorption of incisors after ectopic eruption of maxillary canines: A CT study *Angle Orthod* 2000; 70: 415–423.
34. **Brown ID, Matthews RW.** Apical resorption of a maxillary lateral incisor from a misplaced canine in a 17 year old. A case report. *Br J Orthod* 1981; 8: 3–5.
35. **Ericson S, Kurol J.** Incisor root resorptions due to maxillary canines imaged by Computed Tomography: A comparative study in extracted teeth. *Angle Orthod* 2000; 70: 276–283.
36. **Brin I, Becker A, Zilberman Y.** Resorbed lateral incisors adjacent to impacted canines have normal crown size. *Am J Orthod Dentofac Orthop* 1993; 104: 60–66.
37. **Rimes RJ, Mitchell C, Wilmot DR.** Maxillary incisor root resorption in relation to the ectopic canine: A review of 26 patients. *Eur J Orthod* 1997; 19: 79–81.
38. **Postlethwaite KM.** Resorption of premolar roots by ectopic canines. *Br Dent J* 1989; 167: 397–398.
39. **Azaz B, Shteyer A.** Resorption of the crown of impacted maxillary canines. *Int J Oral Surg* 1978; 7: 167–171.
40. **Seddon RP, Smith PB.** Early arrested development and coronal resorption of an impacted maxillary canine. Report of a case. *J Dent Child* 1996; 63: 208–212.
41. **Bishara SE.** Impacted maxillary canines: A review. *Am J Orthod Dentofac Orthop* 1992; 101: 159–171.
42. **Jacobs SG.** Localization of the unerupted maxillary canine: How to and when to. *Am J Orthod Dentofac Orthop* 1999; 115: 314–322.
43. **Wraith KL.** Methods of repositioning the misplaced canine. *Dent Practit* 1969; 19: 387–394.
44. **Hunter SB.** The radiographic assessment of the unerupted maxillary canine. *Br Dent J* 1981; 150: 151–155.
45. **Usiskin LA.** Management of the palatal ectopic and unerupted maxillary canine. *Br J Orthod* 1991; 18: 339–346.
46. **Southall PJ, Gravely JF.** Radiographic localization of unerupted teeth in the anterior part of the maxilla: a survey of methods currently employed. *Br J Orthod* 1987; 14: 235–242.
47. **Lindauer SJ, Rubenstein LK, Hang WM, Anderson C, Isaacson RJ.** Canine impaction identified early with panoramic radiographs. *J Am Dent Assoc* 1992; 123: 91–97.
48. **Fox NA, Fletcher GA, Horner K.** Localizing maxillary canines using dental panoramic tomography. *Br Dent J* 1995; 179: 416–420.
49. **Chaushu S, Chaushu G, Becker A.** The use of panoramic radiographs to localize displaced maxillary canines. *Oral Surg, Oral Med, Oral Pathol, Oral Radiol Endod* 1999; 88: 511–516.
50. **Preda L, LaFianza A, DiMaggio EM, Dove R, Schifino MR, Campari R et al.** The use of spiral Computed Tomography in the localization of impacted maxillary canines. *Dentomaxillofac Radiol* 1997; 26: 236–241.
51. **Williams BJ.** Diagnosis and prevention of maxillary cuspid impaction. *Angle Orthod* 1981; 51: 30–40.
52. **Ericson S, Kurol J.** Longitudinal analysis of clinical supervision of maxillary canine eruption. *Comm Dent Oral Epidemiol* 1986; 14: 172–176.
53. **Ericson S, Kurol J.** early treatment of palatally erupting maxillary canines by extraction of the primary canines. *Eur J Orthod* 1988; 10: 283–295.
54. **Power SM, Short MB.** An investigation into the response of palatally displaced canines to the removal of deciduous canines and an assessment of factors contributing to favourable eruption. *Br J Orthod* 1993; 20: 215–223.
55. **Mermigos J, Full AC.** Surgical exposure and orthodontic positioning of the unerupted maxillary canine: a case report. *Paed Dent* 1989; 11:72–75.
56. **Kornhauser S, Abed Y, Harari D, Becker A.** The resolution of palatally impacted canines using palatal occlusal force from a buccal auxiliary. *Am J Orthod Dentofac Orthop* 1996; 110: 528–534.
57. **Noble PM, Butcher GW.** A removable appliance for the three-dimensional movement of ectopic maxillary canines. *Br J Orthod* 1991; 18: 135–138.
58. **Isiekwe MC, Nwoku AL.** Surgery as an adjunct in the orthodontic management of impacted maxillary canines. *Odontostomatol Trop* 1987; XI: 17–20.
59. **Boyd RL.** Clinical assessment of injuries in orthodontic movement of impacted teeth I. Methods of attachment. *Am J Orthod* 1982; 82: 478–485.
60. **Sandler JP.** An attractive solution to unerupted teeth. *Am J Orthod Dentofac Orthop* 1991; 100: 489–493.
61. **Noar JH, Evans RD.** Rare earth magnets in orthodontics: An overview. *Br J Orthod* 1999; 26: 29–37.
62. **Ferguson JW, Parvizi F.** Eruption of palatal canines following surgical exposure. Review of outcomes in a series of consecutively treated cases. *Br J Orthod* 1997; 24: 203–207.

63. **Pearson MH, Robinson SN, Reed R, Birnie DJ, Zaki GA.** Management of palatally impacted canines: the findings of a collaborative study. *Eur J Orthod* 1997; 19: 511–515.
64. **McSherry P.** The Ectopic Maxillary Canine: A review. *Br J Orthod* 1998; 25: 209–216.
65. **Turner SR, Sandy JR.** Autotransplantation of teeth: Is there a role? *Br J Orthod* 1998; 25: 275–282.
66. **Berglund L, Kurol J, Kvint S.** Orthodontic pre-treatment prior to auto transplantation of palatally impacted maxillary canines: case reports on a new approach. *Eur J Orthod* 1996; 18: 449–456.