

Comparison of reliability of lateral cephalogram and computed tomography for assessment of airway space

S Kaur, S Rai¹, M Kaur²

Departments of Oral Medicine and Radiology, I.D.S.T. Dental College, ¹Institute of Dental Studies and Technologies, Kadrabad, Modinagar, Uttar Pradesh, ²Dental College, Jamia Milia Islamia, New Delhi, India

Abstract

Background and Aims: The oropharyngeal (OP) and nasopharyngeal structures seems to play roles in the development of the dentofacial complex. Soft palate as a part of nasopharyngeal and OP apparatus has an important role in phonation, deglutition and respiration. The aim of this study was to find whether any correlation exists between the three types of malocclusion and airway space using lateral cephalogram and computed tomography (CT) and to compare its reliability. To obtain important information on the morphology of the soft palate on lateral cephalogram and to determine its etiopathogenesis in obstructive sleep apnea (OSA).

Materials and Methods: Lateral cephalogram of 45 subjects were used to measure the pharyngeal airway. The subjects were divided into three groups (each group included 15 subjects) according to ANB angle: Class I (ANB angle 2-4°), Class II (ANB angle >4°), Class III (ANB angle ≤2°).

Results: The result showed a significant reduction in pharyngeal airway in ANB Class II. Type I soft palate, leaf-shape was found in maximum subjects. The volume of airway size showed higher statistical significance with the greater coefficient of variation on CT in relation to corresponding cephalometric airway area.

Conclusion: The sagittal skeletal pattern is a contributory factor in variations in the upper airway dimensions. The measurements acquired from both the modalities are reliable and reproducible, but CT gives the better assessment of cross-sectional dimensions of airway space. Morphology of the soft palate can be used as references for etiological research of OSA.

Key words: Airway space, computed tomography, lateral cephalogram, malocclusion, obstructive sleep apnea, soft tissue area

Date of Acceptance: 07-May-2014

Introduction

The form and function of the pharynx has been of interest to researchers for many years. While the typical growth pattern of the pharynx in children and adolescents has been elucidated using growth study material,^[1] roentgenocephalometric analysis has been used extensively to evaluate the growth and malformations of the dentofacial skeleton.^[2]

It seems to be a general belief that the oropharyngeal (OP) and nasopharyngeal structures play important roles in the development of the dentofacial complex.^[3] In many studies, it was demonstrated, that a significant relationship exist between the pharyngeal structures and both-dentofacial and craniofacial structures at varying degrees.^[4] Airway obstruction can determine abnormal development of the facial pattern. Thus, it might be considered useful that the

Address for correspondence:

Dr. Shalu Rai,
Department of Oral Medicine and Radiology,
Institute of Dental Studies and Technologies, Kadrabad,
Modinagar - 201 201, Uttar Pradesh, India.
E-mail: drshalurai@gmail.com

Access this article online

Quick Response Code:



Website: www.njcponline.com

DOI: 10.4103/1119-3077.141431

PMID: *****

assessment of the pharyngeal structures should be included with the orthodontic diagnosis and treatment planning, as the functional, positional, and structural assessments of the dentofacial pattern.

Cephalometry is a relatively inexpensive method and permits morphometric assessment of the nasopharynx, or the configuration of adjacent structures including oro- and hypo-pharynx, which can be defined in terms of depth and height in the median sagittal plane. The dimensional analysis of the soft palate^[5] and tongue and its interaction with upper airway size can be reviewed in depth. The use of lateral cephalometric radiographs is limited and provides only two-dimensional images of the airway.^[4] The arrival of three-dimensional computed tomography (CT) alleviate this problem and provide a detailed analysis of the relationship between the upper airway and its surrounding soft tissues.^[6]

In this study, lateral cephalogram and three-dimensional airway CT were used to investigate the pharyngeal size at various levels that is, nasopharynx, oropharynx and hypopharynx of patients having different dentofacial skeletal patterns, along with dimensional analysis of the soft palate and tongue to determine the linear, volumetric, and cross-sectional area measurements to evaluate the interaction of upper airway size and dentofacial structures.

Study subjects

The study was carried out on patients visiting the Institute of Dental Studies and Technologies, Modinagar, District Ghaziabad, Uttar Pradesh, India from May 2011 to September 2012, who were referred for lateral cephalogram and CT either by the Department of Oral Medicine and Radiology or Department of Orthodontics and Dentofacial Orthopedics. A total of 45 patients in the age range of 18-25 years were selected for the study. Patients with cross bite (posterior),

airway diseases, large adenoids/tonsils, those undergoing orthodontic treatment as well edentulous patients, were excluded from the study. For each patient, written consent was taken, and ethical clearance from Ethical Committee of the Institution was obtained. Based on the sagittal skeleton pattern, all the patients were divided into three groups of 15 subjects each. Class I group (ANB angle 2-4°) Class II group (ANB angle >4°) and Class III group (ANB angle ≤2°). For lateral cephalogram, subjects were exposed with teeth in centric occlusion, lips relaxed and head in natural head position. The dorsum of the tongue and pharyngeal airway were coated with radiopaque dye IOHEX (i.e. iodine 300 mg, tromethamine 1.2 mg, edetate calcium disodium 0.1 mg and water) to enhance the outline of tongue and pharyngeal soft tissue. The patient was asked to swish the dye for 1 s and then swallow. The radiographs were obtained with Kodak, 8000 C dental system. All the radiographs were traced manually by the same investigator thrice. Various cephalometric landmarks, hard tissue linear and angular parameters [Figure 1] and upper airway soft tissue linear measurements were traced manually [Figure 2]. The area of the upper airway soft tissue that is, nasopharynx, oropharynx, hypopharynx, soft palate, and tongue was calculated with Image tool 3.00 software in pixel square [Figure 3]. The pixel square was converted into millimeter square by multiplying the value with 0.264. Soft palate dimensions were traced manually using 0.5 mm lead pencil on acetate paper and classified into five types [Figure 4].

For CT, each subject had an awake CT scan in the supine position for axial scans on the scanning table, with the head carefully aligned in the cephalocaudal axis and neck placed in a neutral position midway between flexion and extension. Axial scans were planned parallel to the infra orbital-metal line and covered the whole region from the external auditory canal to the upper border of the manubrium sterni. Such extended coverage ensures proper evaluation of the pharynx, skull base, and all node bearing areas and examination was

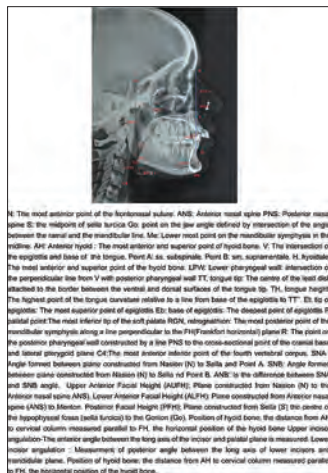

Figure 1: Cephalometric landmark, hard tissue linear and angular measurements




Figure 2: Cephalometric upper airway soft tissue linear measurements

best performed with 3 mm continuous slices. The axial scan was obtained with GE 2369660, MEDICAL SYSTEMS, USA. A fixed window level of 42 and a window width of 378 were used to view muscle. All scans were performed by the same operator on the same machine with recommended exposure parameters. The upper and lower limit of the upper airway and soft tissue volume (cubic centimeters) calculation was evaluated on CT as described by Mayer et al. 1996.^[7] The volume of nasopharynx, oropharynx, hypopharynx, tongue, and soft palate was calculated using the “paint on slices” tool on the workstation by applying paint on all the slice of the image stack in the axial plane of each upper airway soft tissue [Figure 5]. “Histogram” view on the workstation automatically reflects the volume of the sinus in cubic centimeters.

Reliability and Error Analysis

All the measurement was completed twice, 2 weeks apart, by the two investigators. The mean values of the variables measured on each of the two occasions were compared using paired *t*-tests to detect any systematic error in measurements made.

Statistics

Student’s *t*-test for paired samples was used to compare the mean values of study variable vital parameters in relation to airway of lateral cephalogram and CT. The probability value $P < 0.05$ was considered as significant, $P < 0.01$ and $P < 0.001$ were considered as highly significant. The statistical analysis Chi-square test was used for the difference between proportions.

Results

A total number of a male patient in the study were 25 with the distribution of 9 (36%), 4 (15%) and 12 (48%) in each ANB group. A total number of female patient in the study were 20 with distribution of 6 (30%), 11 (55%) and 3 (20%) in each ANB group [Table 1].

Upper airway space and area were measured and compared in three different ANB groups [Table 2]. There was a statistical significant difference among the various ANB groups in the superior posterior airway space (SPAS) and nasopharynx and oropharynx area ($P < 0.05$). In Group I that is, (ANB 2-4°) there was an increase in the upper airway space that is, SPAS ($P < 0.05$), middle airway space (MAS) and inferior airway space (IAS) when compared with other two groups, whereas Group II (i.e., ANB >4°) showed a decrease in MAS, IAS and upper airway area, that is, nasopharynx ($P < 0.05$), oropharynx ($P < 0.05$) and hypopharynx area.

Comparison of facial height, soft tissue linear measurements and upper airway space and area in different ANB groups on

lateral cephalogram showed a statistical significant difference among the groups in the OP area ($P = 0.04$), posterior facial height (PFH) ($P = 0.02$), and highly significant difference




Figure 3: Cephalometric upper airway soft tissue area measurements

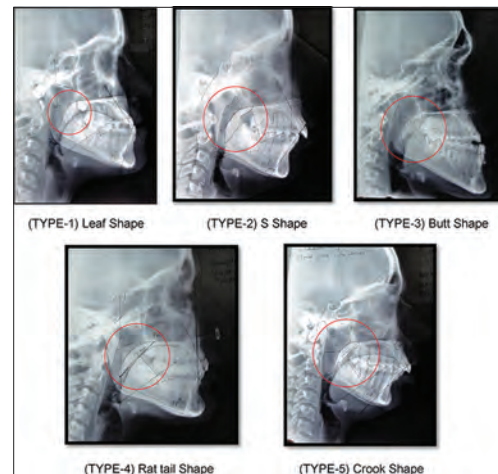


Figure 4: Various shapes of soft palate

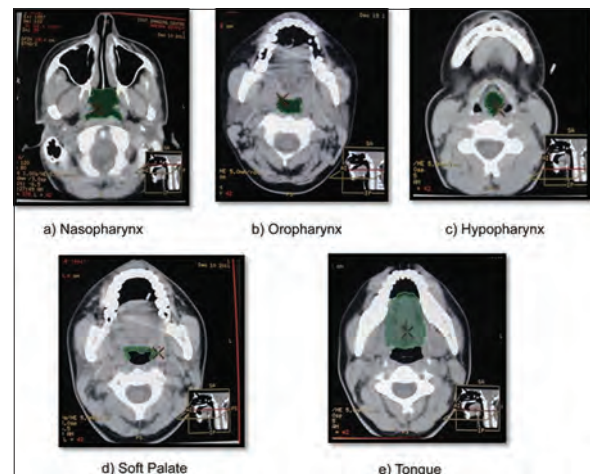


Figure 5: Sequential tracing of the upper airway soft tissue with “paint on slice” tool

among the various three groups in the PFH/anterior facial height (AFH) ($P = 0.01$), SPAS ($P = 0.01$), and nasopharynx area ($P = 0.001$). There was a positive correlation between SNA, SNB and ANB angle and pharyngeal airway that is, nasopharynx, oropharynx and hypopharynx ($P = 0.001$) suggesting positive association

between sagittal maxillomandibular relationship and dimensions of pharyngeal structures [Table 3 and Graph 1]. Additional findings in our study were that maxillary and mandibular incisor angulation did not show any correlation with upper airway. The PFH/AFH ratio was decreased in ANB Group II compared with ANB Groups I and III.

Table 1: Subject classification by malocclusion and sex

Gender (%)	Class (n=15)			Total (n=45)
	I (ANB 2-4°)	II (ANB >4°)	III (ANB ≤2°)	
Male	9 (36)	4 (16)	12 (48)	25 (55.6)
Female	6 (30)	11 (55)	3 (15)	20 (44.4)

ANB=Is the difference between SNA and SNB angle

Table 2: Cephalometric upper airway space and area in the three ANB groups

	Group (n=15)						P value
	I ANB 2-4°		II ANB >4°		III ANB ≤2°		
Should any subhead be here? (mm)							
SPAS	14.07	3.13	12.73	1.67	11.47	1.46	0.01
MAS	13.13	2.20	11.07	2.76	12.13	2.75	0.10
IAS	14.33	2.85	12.67	3.50	13.87	3.80	0.39
Area (mm ²)							
Nasopharynx	1198.75	179.77	1110.04	155.62	1412.59	215.80	0.001
Oropharynx	3028.70	665.40	2640.47	467.76	3057.65	323.94	0.04
Hypopharynx	1934.32	419.21	1636.46	507.48	1717.73	295.82	0.14

SPAS=Superior posterior airway space; MAS=Middle airway space; IAS=Inferior airway space, ANB=Is the difference between SNA and SNB angle

Larger dimension of the soft palate length (PNS-P) was found in ANB Group II; however, it was statistically insignificant ($P > 0.05$). The morphology of the soft palate on lateral cephalogram was examined on the basis of the various radiographic appearances [Table 4] and were classified into five types as: Type I - Leaf-shaped; Type II - Rat-tail shaped; Type III - Butt-like; Type IV - S-shaped; Type V - Crook-shaped. Distribution and proportion of these types are presented in [Table 5 and Graph 2]. The leaf-shape was found in maximum subjects with percentage of 31.3%, followed by crook-shape (28.9%), rat tail (24.4%), S-shape (11.1%), and butt shape (4.4%).

The mean and the standard deviation (SD) for all the dimensions of upper airway and soft tissue volume (cubic centimeters) on CT found statistically significant difference for nasopharynx, oropharynx, and hypopharynx ($P < 0.05$) [Table 6].

The upper airway volume and area in males had overall larger dimensions than in females when compared between CT and lateral cephalogram [Table 7] and found statistically significant difference for nasopharynx, soft palate, tongue

Table 3: Comparison of facial height, soft tissue linear measurements and upper airway space and area in different ANB groups on LC

	Class I malocclusion ANB 2-4° (n=15)		Class II malocclusion ANB >4° (n=15)		Class III malocclusion ANB ≤2° (n=15)		P value
	Mean	SD	Mean	SD	Mean	SD	
	SNA	83.80	2.37	83.00	3.42	77.47	
SNB	80.93	2.49	77.13	3.42	82.13	5.60	0.001
ANB	2.93	0.96	6.20	1.74	-4.67	3.54	0.001
UAFH (mm)	51.50	4.03	48.87	4.49	50.67	4.34	0.20
ULFH (mm)	63.70	4.99	62.47	5.69	64.40	5.54	0.70
AFH	114.20	7.51	111.33	8.58	116.07	8.40	0.66
PFH (mm)	82.87	7.35	75.33	5.05	79.13	7.67	0.02
PFH divided AFH	73.83	6.96	68.00	2.78	68.39	6.20	0.01
Tongue length (mm)	71.07	7.54	70.07	7.06	64.67	10.57	0.10
Tongue height (mm)	28.80	4.96	24.53	4.26	26.13	5.38	0.07
Soft palate length (mm)	33.07	4.79	33.93	5.82	32.60	3.36	0.74
Area (mm ²)							
Nasopharynx	1198.75	179.77	1110.04	155.62	1412.59	215.80	0.001
Oropharynx	3028.70	665.40	2640.47	467.76	3057.65	323.94	0.04
Hypopharynx	1934.32	419.21	1636.46	507.48	1717.73	295.82	0.14
Soft palate	1297.12	167.76	1242.43	175.80	1326.76	175.86	0.41
Tongue	13124.05	2152.14	10590.03	3334.10	11131.60	4124.38	0.10

UAFH=Upper anterior facial height; ULFH=Upper lower facial height; AFH=Anterior facial height; PFH=Posterior facial height; SD=Standard deviation; LC=Lateral cephalogram SNA=Angle formed between plane constructed from Nasion (N) to Sella and Point A; SNB=Angle formed between plane constructed from Nasion (N) to Sella and Point B; ANB=Is the difference between SNA and SNB angle

area ($P < 0.05$) and oropharynx and hypopharynx volume ($P < 0.05$).

The area and volume of the upper airway and soft tissue structures in two different age groups were compared that is, from 18 to 22 years and from 23 to

27 years and showed that nasopharyngeal size tends to decrease with growing age; however, it was statistically insignificant ($P < 0.05$) [Table 7].

The coefficient of variation determined for lateral cephalogram and CT showed that CT measurements were more variable than corresponding airway area on lateral cephalogram [Table 8].

Discussion

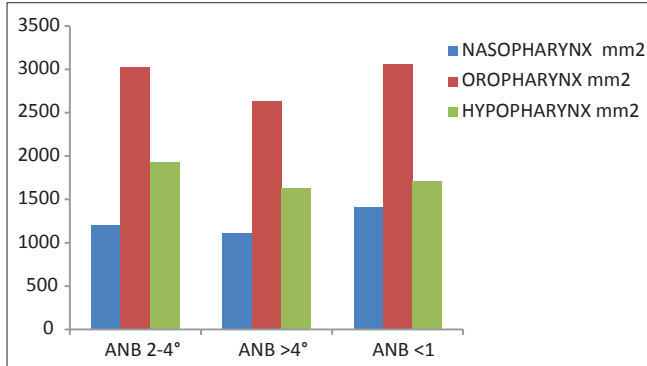
Normal respiration is dependent on sufficient anatomic dimensions of the airway. In recent years, studies have been done concluding that variation in skeletal pattern could predispose to upper airway obstruction. Cephalometry enables analysis of dental and skeletal anomalies as well as soft tissue structures and form.

The ANB angle, which is most commonly used in the determination of anteroposterior dentofacial discrepancy, was used to classify the subjects according to their skeletal configurations into Group I (ANB angle 2-4°), Group II (ANB angle >4°) and Group III (ANB angle ≤2°).^[8]

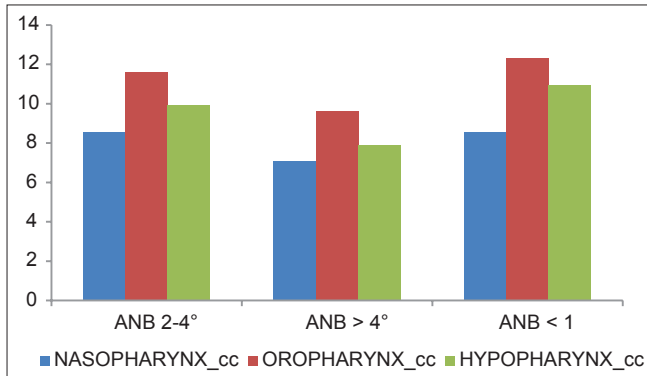
When the airway dimensions were compared significant difference was found between Groups I, II and III at the nasopharynx, oropharynx, and hypopharynx level ($P < 0.05$) thus showing that the dimensions of oropharynx decreased markedly with an increase in ANB angle (ANB angle >4°). The fact that the larger the ANB angle, the less the OP area may be attributable to a different location of tongue and mandible in Class II malocclusion than in other skeletal configurations, as stated in Balters' philosophy.^[9] In Class II malocclusion, the respiratory function is impeded in the region of the larynx and there is faulty deglutition and mouth breathing. Class III malocclusions are due to more forward position of tongue and to cervical overdevelopment.^[4]

These results are in accordance to Alves et al.,^[10] partly in accordance to Ceylan and Oktay^[9] where only oropharynx area has significant relation to ANB angle.

Our present study found that with an increase in PFH, the tongue area increases, which is in accordance with Hwang



Graph 1: Distribution of upper airway area in different ANB group



Graph 2: Distribution of upper airway (cubic centimeters) in three different ANB group on computed tomography

Table 4: Distribution and proportion of soft palate morphology according to gender

Shape (%)	Type I leaf	Type II rat tail	Type III butt shape	Type IV S-shape	Type V crook-shape	Total
Male	7 (28)	5 (20)	1 (4)	4 (16)	8 (32)	25 (55.65)
Female	7 (35)	6 (30)	1 (5)	1 (5)	5 (25)	20 (44.4)
Proportion	14 (31.1)	11 (24.4)	2 (4.4)	5 (11.1)	13 (28.9)	

$\chi^2=2.03$; $df=4$; $P>0.05$ that is, nonsignificant

Table 5: Upper airway and soft tissue volume data for different ANB group on CT

	Class I ANB 2-4° (n=15)		Class II Group II ANB>4° (n=15)		Class III Group III ANB≤2° (n=15)		P value
	Mean	SD	Mean	SD	Mean	SD	
Nasopharynx (cc)	8.5707	1.83331	7.0853	1.43778	8.5793	1.42023	0.019
Oropharynx (cc)	11.619	2.3758	9.605	2.1546	12.318	1.5585	0.002
Hypopharynx (cc)	9.954	1.87746	7.8767	2.36215	10.9347	1.72117	0.001
Tongue (cc)	30.8247	4.78377	28.5307	5.0554	32.088	4.49768	0.131
Soft palate (cc)	7.556	0.60433	7.6047	0.67501	7.850	0.94375	0.526

SD=Standard deviation; CT=Computed tomography

Table 6: The mean and SD of cephalometric and CT upper airway and soft tissue area and volume according to gender

	Male n=25 (55.6%)		Female n=20 (44.4%)		P value
	Mean	SD	Mean	SD	
LC (mm ²)					
Nasopharynx	1333.03	229.70	1124.75	148.84	0.001
Oropharynx	3035.35	559.27	2750.92	456.14	0.07
Hypopharynx	1815.63	392.86	1696.85	466.86	0.36
Soft palate	1345.27	160.19	1218.15	165.30	0.01
Tongue	13378.50	1627.51	9411.14	3794.60	0.001
CT (cc)					
Nasopharynx	8.17	1.64	7.94	1.79	0.65
Oropharynx	11.99	2.01	10.17	2.34	0.01
Hypopharynx	10.85	1.88	8.01	1.88	0.001
Tongue	30.74	4.42	30.16	5.56	0.70
Soft palate	7.8548	0.80466	7.4395	0.61	0.090

SD=Standard deviation; CT=Computed tomography; LC=Lateral cephalogram

Table 7: The means, SD of cephalometric and CT upper airway and soft tissue area and volume according to the age group

	18-22 years n=28 (62.2%)		23-27 years n=17 (37.8%)		P value
	Mean	SD	Mean	SD	
LC (mm ²)					
Nasopharynx	1257.41	240.82	1212.53	190.73	0.52
Oropharynx	2980.37	501.89	2791.28	568.96	0.25
Hypopharynx	1738.82	324.64	1802.40	565.33	0.63
Soft palate	1293.56	181.40	1280.88	162.85	0.82
Tongue	11454.25	3395.99	11880.37	3524.33	0.69
CT (cc)					
Nasopharynx	8.18	1.76	7.88	1.60	0.58
Oropharynx	11.13	2.06	11.27	2.78	0.85
Hypopharynx	9.52	2.19	9.70	2.66	0.81
Tongue	30.90	5.19	29.79	4.46	0.47
Soft palate	7.8179	0.72398	7.4271	0.74744	0.99

SD=Standard deviation; CT=Computed tomography; LC=Lateral cephalogram

Table 8: Comparison of LC area and CT volume along with mean, SD and CV

	Mean	SD	CV
CT volume			
Nasopharynx	8.07	1.69	0.210
Oropharynx	11.18	2.32	0.208
Hypopharynx	9.59	2.35	0.245
LC area			
Nasopharynx	120.46	222.03	0.179
Oropharynx	2908.94	529.98	0.182
Hypopharynx	1762.84	426.46	0.242

SD=Standard deviation; CV=Coefficient of variation; CT=Computed tomography; LC=Lateral cephalogram. Coefficient variance=(SD/mean) × 100. More variability in CT with airway compare to LC with airway

et al.^[11] Thus, our study concluded that facial height has an influence on tongue area [Table 3].

In our study, the patients with an increase in AFH showed larger nasopharyngeal area, which is in partial accordance with the study by Kerr^[12] who found a moderate correlation between Class II malocclusion subjects and facial height (total facial height and anterior lower face height) and nasopharyngeal dimensions. This confirms that when function is normal, the relationship between changes in nasopharyngeal morphology and AFH are weak. Our finding that nasopharyngeal area is of smaller dimension in Class II group accord well with the data presented by Kerr.^[12]

Our finding showed that larger dimension of the soft palate length in ANB Group II could be due to backward position of tongue resulting in compression of the soft palate and therefore, decrease in thickness and increase in length of the soft palate, which was in agreement to Jena *et al.*^[13] who evaluated the sagittal mandibular development effects on the dimensions of the pharyngeal airway passage in awake patients.

In this study Type I, leaf-shape being present in 14 patients (31.1%) was the most frequent type as also observed by You *et al.*^[5] [Table 4]. This type was previously described as classical soft palate morphology in the literature and is considered to be the most frequent type of presentation. Type IV, S-shape palate, which was described as a hooked appearance of the soft palate according to Pépin *et al.*^[14] was present in five patients (11.1%) of our study (Type V). They hypothesized that soft palate-hooking plays a key role in pharyngeal collapse, since hooking results in a sudden and a major reduction in the OP dimensions, which therefore dramatically increases upper airway resistance and the transpharyngeal pressure gradient and concluded that hooking of the soft palate in awake patients indicates a high risk for obstructive sleep apnoea (OSA) syndrome.

The percentages of Types IV (S-shape) and Type V (crook-shape) were found to be smaller in women than in men. The soft palate length in Type III that is, Butt shape was significantly shorter than the other types. It is a likely hypothesized that velopharyngeal adequacy is strongly dependent on a close coordination of the anatomic parts involved in velopharyngeal closure: The soft palate and the contiguous pharyngeal structures.

Advances in CT imaging and the three-dimensional technology allows better visualization of the airway and volumetric analysis.^[15] Clinicians can more easily perform the volumetric measurements and also calculate the cross-sectional areas of the airway in three planes of space:

Coronal, sagittal, and axial.^[16] The axial plane, which is not visualized on a lateral cephalogram, is the most physiologically relevant plane because it is perpendicular to the airflow.^[17,18]

The mean and the SD for all the dimensions of upper airway and soft tissue volume in axial plane on CT showed that when all three ANB groups were compared statistically, significant difference was found for nasopharyngeal, OP and hypopharyngeal volume. The airway volume was less in ANB Group II and larger in Group III as compared with Group I. Thus, it can be concluded from our study that decrease in OP size in Class II patients can be a result of different location of tongue and mandible and increase in OP size in Class III is due to anterior mandibular position and lower tongue position. This is in agreement with El and Palomo^[3] who measured the nasal passage and OP volumes of patients on cone-beam CT (CBCT). The finding that patients with Class III had larger OP area and width compared with the Class I group was in accordance with Iwasaki *et al.*,^[19] and with Hong *et al.*^[20]

Our study calculated the mean along with the SD for all the dimensions of upper airway volume and area on CT and lateral cephalogram of both gender and found that upper airway volume and area in males had overall larger dimensions than in females. These findings are in accordance with Martin *et al.*,^[4] Grauer,^[21] Son and Choi,^[22] Samman *et al.*,^[23] and Chiang *et al.*^[24]

The area and volume of the upper airway and soft tissue structures in two different age groups were compared, that is, from 18 to 22 years and from 23 to 27 years. Our results showed that nasopharyngeal size tends to decrease with growing age ($P < 0.05$), but was statistically insignificant.

King,^[25] Handelman and Osborne^[26] and Tourn^[27] have stated that the nasopharyngeal depth is formed at the early stages of life, and then it usually remains the same. Jeans *et al.*^[28] have reported that the nasopharyngeal airway area increases rapidly until 13 years of age and after this period, the growth slows down, which is in accordance with our study. In addition to above our study also concluded that with increasing age, hypopharynx size (area and volume) increases, oropharynx volume increases with a decrease in area, tongue area increases with a decrease in volume and soft palate size (area and volume) decreases.

Evaluation of the airway is useful in some orthodontic patients, especially those with breathing disorders. Moreover, the three-dimensional imaging systems allow clinicians to overcome the limitations of the two-dimensional representation of three-dimensional objects. Our approach was to compare the reliability of the airway measurements in three-dimensional CT with data obtained with two-dimensional cephalograms. The variability results from

changes in the airway position, morphology, and dimension due to the effects of either the patient's respiration or swallowing actions during the scanning procedure. CT airway volume shows more variability than corresponding airway area indicating that there may be airway information that is not accurately depicted on the lateral head film. Aboudara *et al.*^[29] compared airway information from 11 normal adolescent children between lateral cephalometric head films and three-dimensional CBCTs. They concluded that intra-subject proportion of airway volume to area shows moderate variability. Similar study conducted by Aboudara *et al.*^[15] from 35 adolescent subjects indicated that there is a significant positive relationship between nasopharyngeal airway size on a head film and its true volumetric size from a CBCT scan. They concluded that the three-dimensional CBCT scan is a simple and effective method to analyze the airway accurately.

Abramson *et al.*^[18] correlated the three-dimensional CT findings of airway size and shape with lateral cephalometric measurements. Their results indicated that the three-dimensional CT and lateral cephalometric measurements were reliable and reproducible.

Vizzotto *et al.* (2011)^[30] evaluated the accuracy of airway measurements from lateral cephalograms, CBCT lateral reconstructions and CBCT axial planes and showed that the airway linear measurements are reliable, with both lateral cephalograms and CBCT reconstruction.

Our findings are in accordance with the above-mentioned studies as the measurements acquired from both the modalities are reliable and reproducible, but lateral cephalometric radiographs provides no information about the volumetric measurements of the upper airway and that CT airway volume shows more variability than corresponding airway area.

Conclusion

Sagittal skeleton pattern had a close association between the pharyngeal airway passage and dimensions of pharyngeal airway passage. Significant sex dimorphism was evident for measurements of the pharyngeal airway suggesting that the males had larger dimensions compared with females. The leaf-shape of the soft palate was found in maximum subjects in our population with percentage of 31.3%. The S-shape described as a hooked appearance which was found to be 11.1% could be considered as high risk for sleep apnea. Thus, our study also concludes that facial height has an influence on nasopharynx and tongue area. The measurements acquired from both the modalities are reliable and reproducible, but lateral cephalometric radiographs provide no information about the lateral structures and volumetric measurements of the upper airway. Further investigation using both

static and dynamic imaging techniques such as all night polysomnographic recordings, the sleep recording including electroencephalogram, electrocardiogram, electrooculogram, electromyogram, thoracic respiratory movements, naso-oral airflow, and transcutaneous oxygen tension further clarify the pathogenesis of OSA in obese and nonobese patients.

References

- Johnston CD, Richardson A. Cephalometric changes in adult pharyngeal morphology. *Eur J Orthod* 1999;21:357-62.
- deBerry-Borowiecki B, Kukwa A, Blanks RH. Cephalometric analysis for diagnosis and treatment of obstructive sleep apnea. *Laryngoscope* 1988;98:226-34.
- El H, Palomo JM. Airway volume for different dentofacial skeletal patterns. *Am J Orthod Dentofacial Orthop* 2011;139:e511-21.
- Martin O, Muelas L, Viñas MJ. Nasopharyngeal cephalometric study of ideal occlusions. *Am J Orthod Dentofacial Orthop* 2006;130:436.e1-9.
- You M, Li X, Wang H, Zhang J, Wu H, Liu Y, *et al.* Morphological variety of the soft palate in normal individuals: A digital cephalometric study. *Dentomaxillofac Radiol* 2008;37:344-9.
- Lowe AA, Fleetham JA, Adachi S, Ryan CF. Cephalometric and computed tomographic predictors of obstructive sleep apnea severity. *Am J Orthod Dentofacial Orthop* 1995;107:589-95.
- Mayer P, Pépin JL, Bettega G, Veale D, Ferretti G, Deschaux C, *et al.* Relationship between body mass index, age and upper airway measurements in snorers and sleep apnoea patients. *Eur Respir J* 1996;9:1801-9.
- Bhad WA, Nayak S, Doshi UH. A new approach of assessing sagittal dysplasia: The W angle. *Eur J Orthod*. 2013 Feb;35:66-70. doi: 10.1093/ejo/cjr001. Epub 2011 Feb 8.
- Ceylan I, Oktay H. A study on the pharyngeal size in different skeletal patterns. *Am J Orthod Dentofacial Orthop* 1995;108:69-75.
- Alves M Jr, Franzotti ES, Baratieri C, Nunes LK, Nojima LI, Ruellas AC. Evaluation of pharyngeal airway space amongst different skeletal patterns. *Int J Oral Maxillofac Surg* 2012;41:814-9.
- Hwang YI, Lee KH, Lee KJ, Kim SC, Cho HJ, Cheon SH, *et al.* Effect of airway and tongue in facial morphology of prepubertal class I, II children. *Korean J Orthod* 2008;38:74-82.
- Kerr WJ. The nasopharynx, face height, and overbite. *Angle Orthod* 1985;55:31-6.
- Jena AK, Singh SP, Utreja AK. Sagittal mandibular development effects on the dimensions of the awake pharyngeal airway passage. *Angle Orthod* 2010;80:1061-7.
- Pépin JL, Veale D, Ferretti GR, Mayer P, Lévy PA. Obstructive sleep apnea syndrome: Hooked appearance of the soft palate in awake patients – Cephalometric and CT findings. *Radiology* 1999;210:163-70.
- Aboudara C, Nielsen I, Huang JC, Maki K, Miller AJ, Hatcher D. Comparison of airway space with conventional lateral headfilms and 3-dimensional reconstruction from cone-beam computed tomography. *Am J Orthod Dentofacial Orthop* 2009;135:468-79.
- Schwab RJ. Upper airway imaging. *Clin Chest Med* 1998;19:33-54.
- Isono S, Morrison DL, Launois SH, Feroah TR, Whitelaw WA, Remmers JE. Static mechanics of the velopharynx of patients with obstructive sleep apnea. *J Appl Physiol* (1985) 1993;75:148-54.
- Abramson ZR, Susarla S, Tagoni JR, Kaban L. Three-dimensional computed tomographic analysis of airway anatomy. *J Oral Maxillofac Surg* 2010;68:363-71.
- Iwasaki T, Hayasaki H, Takemoto Y, Kanomi R, Yamasaki Y. Oropharyngeal airway in children with Class III malocclusion evaluated by cone-beam computed tomography. *Am J Orthod Dentofacial Orthop* 2009;136:318.e1-9.
- Hong JS, Oh KM, Kim BR, Kim YJ, Park YH. Three-dimensional analysis of pharyngeal airway volume in adults with anterior position of the mandible. *Am J Orthod Dentofacial Orthop* 2011;140:e161-9.
- Grauer D, Cevdanes LS, Styner MA, Ackerman JL, Proffit WR. Pharyngeal airway volume and shape from cone-beam computed tomography: Relationship to facial morphology. *Am J Orthod Dentofacial Orthop* 2009;136:805-14.
- Son WS, Choi YS. Evaluation of hyoid bone position and airway size in class III malocclusion. *Korean J Orthod* 1996;26:247-53.
- Samman N, Mohammadi H, Xia J. Cephalometric norms for the upper airway in a healthy Hong Kong Chinese population. *Hong Kong Med J* 2003;9:25-30.
- Chiang CC, Jeffres MN, Miller A, Hatcher DC. Three-dimensional airway evaluation in 387 subjects from one university orthodontic clinic using cone beam computed tomography. *Angle Orthod* 2012;82:985-92.
- King EW. A roentgenographic study of pharyngeal growth. *Angle Orthod* 1952;22:23-37.
- Handelman CS, Osborne G. Growth of the nasopharynx and adenoid development from one to eighteen years. *Angle Orthod* 1976;46:243-59.
- Tourné LP. Growth of the pharynx and its physiologic implications. *Am J Orthod Dentofacial Orthop* 1991;99:129-39.
- Jeans WD, Fernando DC, Maw AR, Leighton BC. A longitudinal study of the growth of the nasopharynx and its contents in normal children. *Br J Radiol* 1981;54:117-21.
- Aboudara CA, Hatcher D, Nielsen IL, Miller A. A three-dimensional evaluation of the upper airway in adolescents. *Orthod Craniofac Res* 2003;6 Suppl 1:173-5.
- Vizzotto MB, Liedke GS, Delamare EL, Silveira HD, Dutra V, Silveira HE. A comparative study of lateral cephalograms and cone-beam computed tomographic images in upper airway assessment. *Euro J of Orthodontics* 2011;34:390-3.

How to cite this article: Kaur S, Rai S, Kaur M. Comparison of reliability of lateral cephalogram and computed tomography for assessment of airway space. *Niger J Clin Pract* 2014;17:629-36.

Source of Support: Nil, **Conflict of Interest:** None declared.