

Sonographic assessment of the normal limits of the spleen in healthy school children in South-East Nigeria

SN Ezeofor¹, EN Obikili^{1,2}, GE Anyanwu², AC Onuh¹, SO Mgbor¹

Departments of ¹Radiation Medicine, and ²Anatomy, College of Medicine, Faculty of Medical Sciences, University of Nigeria, Enugu Campus, Enugu State, Nigeria

Abstract

Background/Objective: Ultrasonography is a good modality for the detection of splenomegaly even when it is not clinically palpable. The objective of this study was to establish the normal values of splenic length in healthy school children in South-East, Nigeria and to correlate them with body indices.

Materials and Methods: This is a cross-sectional prospective study of 1315 children (633 boys and 682 girls) between the ages of 5 and 17 years. The splenic length was measured between the most superiomedial and the most inferiolateral margins, at the level of the hilum. Only the spleens that had normal shape and echotexture were measured. The mean splenic length and the 5th and 95th percentiles were determined for each age. The length was correlated with the sex, age, weight (WT), height, body mass index (BMI) and body surface area (BSA) of the subjects. A regression model for prediction of spleen dimension from age and body habitus was computed.

Results: There was a significant correlation between splenic length and age, $P < 0.001$. Males had statistically significant longer spleen length than females. The splenic length correlated best with BSA, followed by body WT and least with BMI.

Conclusions: This study noted racial variation between the established Nigerian values and results from other countries of the world. For the first time, a baseline value for splenic size for the Nigerian Children of various ages has been established with a regression model for predicting the splenic sizes.

Key words: Children, echotexture, Nigeria, sonography, spleen, splenomegaly, ultrasonography

Date of Acceptance: 14-Dec-2013

Introduction

The spleen is an intra-abdominal organ located superior-laterally on the left. It can be affected by several groups of diseases; falciparum malaria infection and hematopoietic disorders (including sickle cell anemia, tropical splenomegaly syndrome). Others are reticuloendothelial proliferation, portal hypertension, storage diseases, inflammatory conditions,^[1] neoplasms, viral infections like infectious mononucleosis,^[2] as well as trauma. The assessment of the size of an organ is an integral part

of the evaluation of a disease, either localized or systemic, involving that organ for screening, diagnostic and prognostic purposes. Clinical examination has been established to be often inaccurate in detecting especially small increases in size.^[3,4] The spleen may be palpable in only about 15-17% of healthy neonates^[5] and 10% of healthy children.^[6] Studies^[7] have established that palpable cases do not signify splenic enlargement. In most individuals, it is usually 2-3 times its normal size before it is actually palpable.^[6] This is because

Address for correspondence:

Dr. Salome N Ezeofor,
Department of Radiation Medicine, College of Medicine, Faculty of Medical Sciences, University of Nigeria, Enugu Campus, Enugu State, Nigeria.
E-mail: salome.ezeofor@unn.edu.ng

Access this article online

Quick Response Code:



Website: www.njcponline.com

DOI: 10.4103/1119-3077.134046

PMID: 24909474

it is located laterally and bordered by the ribs thus making palpation and percussion difficult. It is therefore usually significantly enlarged before it can be clinically assessed under the costal margin. Reports on earlier studies^[6,8] have demonstrated that splenic size differs from race to race; thus the provision of accurate values should be specific to any given population.

Imaging findings must be accurate to assess the duration and level of care. Splenic salvage techniques and non-operative managements are preferable to splenectomy in children.^[9,10] The spleen can be evaluated with imaging modalities such as conventional radiography, computed tomography (CT) scan and scintigraphy. Although some of these methods utilize ionizing radiation, others are invasive. Differences in imaging technique can bring about variations in organ sizes.^[11] Earlier studies, using scintigraphy,^[12,13] and conventional radiography^[14] have established that these methods magnify images. With conventional radiography, it is difficult to visualize normal-sized spleen. In some cases, only the inferior pole can be identified and this may not necessarily signify splenomegaly, but may be due to its inferior displacement by masses like left sided subphrenic mass. CT and scintigraphy are expensive in most localities and may not always be readily available. Sonographically obtained linear measurements have been shown to have a high correlation with CT volume assessment.^[15] Thus, CT scan does not actually add any significant clinical value in terms of measurements. Moreover, it is not advisable to use CT for routine measurements and investigations in children because of the exposure of radiosensitive areas to radiation with consequent risk of cancer development. Imaging can also be obtained with Magnetic resonance imaging; this does not utilize ionizing radiation, but is very expensive and also not readily available in most parts of the developing countries.

Determination of the spleen size has been done using various parameters of the spleen such as the width,^[11,16,17] the volume^[18,19] and the ratio.^[1,8] However, when serial examinations of spleen sizes are required, these modes of measurements become cumbersome and time consuming, making use of the spleen length the most effective and convenient method. The use of splenic length in the determination of the splenic size has been noted to compare very closely with measurements at autopsy.^[1,20-22]

Ultrasonography is routinely used to evaluate the abdominal organs in children because it does not use ionizing radiation, is non-invasive, lacks radiographic magnification and osmotic effect of the iodinated contrast medium.^[23] Moreover it is safe, provides real time images and does not require anesthesia.^[24,25] Furthermore during the follow-up examination, repeat sonography can be safely done. Ultrasound was adopted as the imaging tool for this study due to its health advantages, accessibility and portability.

Furthermore, sonographically obtained splenic length is considered the best tool for the assessment of the size and growth of the spleen and has further been demonstrated to correlate well with measurements at autopsy.^[1,20-22]

Earlier studies have established racial variation in the splenic size.^[11,16,25] Studies on the spleen dimension of children are few in the literature and are even non-existent in some developing countries like Nigeria. Estimations of the normal size of the spleen among our clinicians and other health care practitioners have been based on the reports of studies done outside our environment where the samples in most cases were from other races. This practice makes us vulnerable to the error of either under-estimating or over-estimating the spleen length. Nigeria is one of the African countries battling with the problem of primary health care. As part of the effort to ensure basic primary health care and with the total absence of published normative data of splenic size in children in this country as a whole, we decided to establish these normal values and correlate it with age, sex and body size indices. This data, we project will serve as a normative reference data for assessment of spleen size amongst the primary health care administrators in both rural and urban regions of Nigeria.

Materials and Methods

This is a cross-sectional study of Nigerian children in primary and secondary schools from the ages of 5-17 years. Sex, age, body weight (WT), height (HT), body surface area (BSA) and body mass index (BMI), were determined for each participant. This study was approved by the ethics committee of the University of Nigeria teaching hospital, Enugu State, Nigeria. Furthermore informed consent, describing the purpose of the study, was obtained from all parents whose children were involved in the study. The study was conducted between April 2008 and November 2010. Only apparently healthy children were randomly selected for this study after brief clinical examination of the children. Apparently healthy children with chronic conditions like sickle cell anemia were excluded from the study.

Clinical exclusion criteria were fever, jaundice, macular or maculopapular rash and lymphadenopathy. Imaging exclusion criteria were parenchyma abnormal masses, accessory spleens, cysts (solitary or multiple). HT was measured to the nearest 0.5 cm using a vertical scale of portable stadiometer with the participant in an erect position without shoes and head held in the Frankfort plane. WT was measured to the nearest 0.1 kg using the same stadiometer, with each participant lightly clothed. BMI was calculated as WT divided by square of HT (kg/m^2).

Measurements were taken by one of the radiologists who is also one of the authors. Scans were done with GE LOGIC 400 CL made by GE medical systems with a curvilinear probe

of 3.5 MHz frequency. Two sequential measurements were obtained and the mean calculated; this was to minimize intra-operator variation and ensure greater accuracy and reliability of measurements. Most measurements were taken in quiet respiration for the younger children. In older children, it was taken in deep inspiration while the subjects briefly held their breath. No sedation or preparation was used.

Measurement was done with each subject in supine or in a slightly right lateral decubitus position. The splenic length was measured on a longitudinal coronal plane between the most superiomedial and the most inferiolateral margins at the level of the hilum^[20] [Figure 1].

Statistical methods

Data analysis was carried out using SPSS version 15.0. (SPSS Inc., Chicago, IL). The relationships between the spleen length, age, sex, WT, HT, BSA and BMI were determined and regression model was established.

Results

The spleens of a total of 1,315 school age children were measured. There were 633 (48.1%) males and 682 (51.9%)

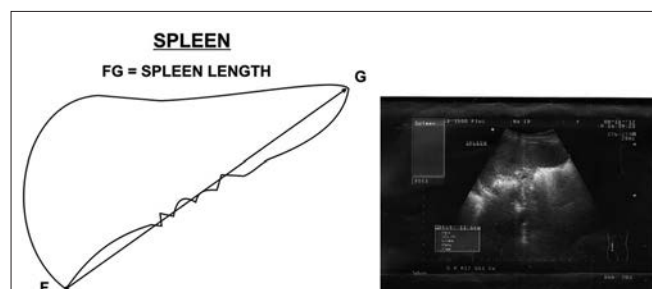


Figure 1: The schematic and ultrasound image of the points of measurement of the spleen length

Table 1: Frequency distribution of participants by age and sex

Age (years)	Frequency males	Frequency females	Total
5	23	31	54
6	55	64	119
7	49	63	112
8	44	55	99
9	96	80	176
10	97	101	198
11	66	65	131
12	41	42	83
13	25	33	58
14	46	55	101
15	42	39	81
16	31	41	72
17	18	13	31
Total	633	682	1315

females giving a M:F ratio of 1:1.1. The distribution of the spleen dimension with body size indices is shown in Table 1.

Tables 2 and 3 show a direct relationship of the spleen length with both age and body size indices. Table 3 shows a Pearson correlation matrix of the splenic length with other variables. The splenic length correlated best with BSA, followed by WT.

The splenic length was established to be longer in males with a statistically significant difference from 6 years of age ($P < 0.05$, $P < 0.01$). A regression model for computing the splenic length from age, WT and HT was computed at $P < 0.001$ and is as follows:

$$\text{Splenic length} = (4.66) + \text{Age} (0.05) + \text{HT} (0.01) + \text{WT} (0.04)$$

Discussion

The importance of the knowledge of the normal range of values of the various viscera in identification of early pathological changes can never be over emphasized. It is therefore very mandatory to establish these normal values for identification of early pathological changes. Most of the reports of studies on the spleen size have been done with a limited number of subjects,^[11,21-25] this has made normal distribution of the ages of these subjects in these reports difficult. For effective distribution of age groups, 1315 Nigerians within the pediatric age group (<17 years) were used in the establishment of normal spleen lengths in Nigerian children within the south east. This study, through the use of ultrasound has set a baseline data, which can be used as a comprehensive guide to indicate normal spleen dimensions for the South East Nigerian child within the age of 5-17 years. Spleen dimensions have been reported to vary with races and countries.^[11,21-25]

Males in our study showed significantly larger spleen dimension from 6 years of age. Earlier studies in similar age groups in other countries found no difference in the spleen dimensions at this age group.^[13,20] On the contrary, a report from Jordan^[1] noted that at age 15 years and above, the spleen lengths of the females were slightly larger than those of the males. These are evidences of racial differences in spleen size.

The splenic size, in our study, increased with age. This is in line with earlier reports by Okoye *et al.*^[26] in their study of the splenic sizes in adult Nigerian population. They reported that spleen gets to its maximum size in males at age 39 years and in females at age 44 years. This report when compared with other results from other countries shows that a Nigerian child has a relatively smaller spleen size when compared with a child of the same age group in America^[21] and Turkey.^[17] Comparably similar spleen sizes were noted for Nigerians and

Table 2: Distribution of spleen length based on age and body size indices

Age	Females						Males					
	HT	WT	BSA	SPL	5 th %	95 th %	HT	WT	BSA	SPL	5 th %	95 th %
5.0	113.5±5.2	19.6±2.3	0.8±0.1	6.5±0.8	5.3	8.5	113.6±5.4	21.0±2.5	0.8±0.1	6.9±0.8	5.6	8.2
6.0	117.6±6.2	21.5±2.2	0.8±0.1	7.1±0.9	5.6	9.0	118.2±5.3	22.5±3.1	0.9±0.1	7.2±0.7	6.1	8.6
7.0	125.3±5.7	24.6±3.0	0.9±0.1	7.2±0.8	5.7	8.3	125.7±4.7	25.1±3.1	0.9±0.1	7.3±0.8	6.2	8.7
8.0	130.4±6.7	28.1±6.4	1.0±0.1	7.2±0.8	5.7	9.0	130.2±4.7	27.6±4.5	1.0±0.1	7.5±0.9	6.2	9.2
9.0	137.0±6.5	31.7±6.0	1.1±0.1	7.5±0.8	6.2	9.3	136.3±6.0	31.1±4.7	1.1±0.1	7.6±1.0	6.0	9.7
10.0	142.2±7.2	35.2±7.4	1.2±0.1	7.7±1.1	6.2	9.6	141.3±5.3	33.5±5.5	1.2±0.1	7.9±1.0	6.5	9.7
11.0	145.9±8.6	37.7±6.9	1.2±0.1	7.7±1.1	6.2	9.8	144.3±6.9	35.4±5.8	1.2±0.1	7.9±1.1	6.3	9.8
12.0	152.4±7.1	44.5±11.3	1.4±0.2	8.1±1.6	6.2	10.5	146.3±8.7	39.4±9.2	1.3±0.2	8.2±1.4	6.5	11.2
13.0	155.1±7.4	45.7±13.1	1.4±0.2	8.6±1.4	6.5	11.0	154.2±7.3	43.4±9.7	1.4±0.2	8.7±1.8	6.8	13.4
14.0	163.2±8.1	54.8±11.1	1.6±0.2	9.2±1.0	7.5	11.3	162.5±6.1	54.6±11.5	1.6±0.2	9.4±1.5	7.4	12.6
15.0	166.5±6.8	56.1±9.1	1.6±0.1	9.2±1.1	7.5	12.0	166.9±5.3	58.1±12.2	1.6±0.3	9.3±1.3	7.3	11.7
16.0	165.7±6.7	58.0±13.1	1.6±0.2	9.2±1.2	7.6	12.1	177.1±7.0	64.1±11.1	1.8±0.2	10.1±1.6	7.7	14.1
17.0	166.7±1.2	58.5±7.8	1.7±0.1	9.1±0.9	7.7	12.1	175.0±6.5	62.2±8.1	1.8±0.1	10.1±1.4	7.7	14.3

HT=Height; WT=Weight; BSA=Body surface area; SPL=Splenic length

Table 3: Pearson correlation matrix of the splenic length and body size indicators

Body size indicators	Age	HT	WT	BMI	BSA
SPL	0.587**	0.603**	0.643**	0.055*	0.645**

HT=Height; WT=Weight; BSA=Body surface area; BMI=Body mass index; SPL=Splenic length; * $P < 0.05$; ** $P < 0.01$

Indians.^[27] Similar study in Philadelphia^[21] reported larger splenic size when compared with their Turkish^[17] counterparts for children <8 years of age. Loftus and Metreweli^[8] in their study have reported similar sizes of spleen for Chinese and American Children within 15 years of age despite the smaller statures of Chinese children. They further demonstrated, that the diagnosis of splenomegaly should be made if the spleen is more than 1.25 times the size of the adjacent kidney.

Splenic length in our study correlated very well with all the body size indicators. This is in agreement with the observation of the rapid increases of organs during the early years of life.^[11] In our study, BSA gave the best correlation with splenic length. This is in agreement with the study by Safak *et al.*^[24] but contrary to reports by Konus *et al.*^[17] and Dhingra *et al.*^[27] where HT was reported to give the best correlation, followed by BSA. Other studies^[25,28] have reported WT to give the best correlation. Other studies on spleen length in adults have also compared body habitus with spleen sizes. Two of these studies in Nigeria^[25,26] noted WT as the best correlate. Although sex, age and body habitus alongside ethnicity are considered very important in the estimation of the spleen length in children, Hosey *et al.*^[11] in their study of the spleen size of collegiate athletes emphasized strongly the role of sex and race above others, in reliable prediction of the spleen size of adults.

Conclusion

This work in comparison with results from other studies in various continents of the world, noted a variation between the

Nigerian values and some of these reported values. The study agreed with earlier reports of smaller splenic sizes in Africans and African Americans^[11] it also reported similar splenic size between Nigerians and Indians.^[27] This study for the first time, has set a baseline value for splenic size for the Nigerian Children of various ages with the regression model for predicting the splenic sizes. These values are expected to enhance medical and health care practice particularly in centers that may not afford or have easy access to ultrasound machines, rural areas where electric power generation is still a challenge and also in urban areas where it can speed up health response.

References

- Al-Imam O, Suleiman A, Khuleifat S. Ultrasound assessment of normal splenic length and spleen-to-kidney ratio in children. *East Mediterr Health J* 2000;6:514-6.
- Kinderknecht JJ. Infectious mononucleosis and the spleen. *Curr Sports Med Rep* 2002;1:116-20.
- Zhang B, Lewis SM. A study of the reliability of clinical palpation of the spleen. *Clin Lab Haematol* 1989;11:7-10.
- Gerspacher-Lara R, Pinto-Silva RA, Serufo JC, Rayes AA, Drummond SC, Lambertucci JR. Splenic palpation for the evaluation of morbidity due to schistosomiasis mansoni. *Mem Inst Oswaldo Cruz* 1998;93 Suppl 1:245-8.
- Mimouni F, Merlob P, Ashkenazi S, Litmanovitz I, Reisner SH. Palpable spleens in newborn term infants. *Clin Pediatr (Phila)* 1985;24:197-8.
- French J, Camitta BM. Splenomegaly. *Nelson Textbook of Paediatric*. 15th ed. Philadelphia, Pa: Saunders; 1996. p. 1439.
- Arkles LB, Gill GD, Molan MP. A palpable spleen is not necessarily enlarged or pathological. *Med J Aust* 1986;145:15-7.
- Loftus WK, Metreweli C. Ultrasound assessment of mild splenomegaly: Spleen/kidney ratio. *Pediatr Radiol* 1998;28:98-100.
- Lynn KN, Werder GM, Callaghan RM, Sullivan AN, Jafri ZH, Bloom DA. Pediatric blunt splenic trauma: A comprehensive review. *Pediatr Radiol* 2009;39:904-16.
- Podberesky DJ, Unsell BJ, Anton CG. Imaging of American football injuries in children. *Pediatr Radiol* 2009;39:1264-74.
- Hosey RG, Mattacola CG, Kriss V, Armsey T, Quarles JD, Jagger J. Ultrasound assessment of spleen size in collegiate athletes. *Br J Sports Med* 2006;40:251-4.
- Markisz JA, Treves ST, Davis RT. Normal hepatic and splenic size in children: Scintigraphic determination. *Pediatr Radiol* 1987;17:273-6.
- Holder LE, Strife J, Padikal TN, Perkins PJ, Kereiakes JG. Liver size determination in pediatrics using sonographic and scintigraphic techniques. *Radiology* 1975;117:349-53.

14. Deligeorgis D, Yannakos D, Doxiadis S. Normal size of liver in infancy and childhood. X-ray study. *Arch Dis Child* 1973;48:790-3.
15. Lamb PM, Lund A, Kanagasabay RR, Martin A, Webb JA, Reznek RH. Spleen size: How well do linear ultrasound measurements correlate with three-dimensional CT volume assessments? *Br J Radiol* 2002;75:573-7.
16. Kutlu R, Yakinci C, Durmaz Y, Baysal T, Ozgen U. Sonographic evaluation of liver and spleen sizes in School-aged children. *Turk J Med Sci* 2000;30:187-19.
17. Konuş OL, Ozdemir A, Akkaya A, Erbaş G, Celik H, İşik S. Normal liver, spleen, and kidney dimensions in neonates, infants, and children: Evaluation with sonography. *AJR Am J Roentgenol* 1998;171:1693-8.
18. Dittrich M, Milde S, Dinkel E, Baumann W, Weitzel D. Sonographic biometry of liver and spleen size in childhood. *Pediatr Radiol* 1983;13:206-11.
19. Henderson JM, Heymsfield SB, Horowitz J, Kutner MH. Measurement of liver and spleen volume by computed tomography. Assessment of reproducibility and changes found following a selective distal splenorenal shunt. *Radiology* 1981;141:525-7.
20. Megremis SD, Vlachonikolis IG, Tsilimigaki AM. Spleen length in childhood with US: Normal values based on age, sex, and somatometric parameters. *Radiology* 2004;231:129-34.
21. Rosenberg HK, Markowitz RI, Kolberg H, Park C, Hubbard A, Bellah RD. Normal splenic size in infants and children: Sonographic measurements. *AJR Am J Roentgenol* 1991;157:119-21.
22. Loftus WK, Chow LT, Metreweli C. Sonographic measurement of splenic length: Correlation with measurement at autopsy. *J Clin Ultrasound* 1999;27:71-4.
23. Rosenbaum DM, Korngold E, Teele RL. Sonographic assessment of renal length in normal children. *AJR Am J Roentgenol* 1984;142:467-9.
24. Safak AA, Simsek E, Bahcebasi T. Sonographic assessment of the normal limits and percentile curves of liver, spleen, and kidney dimensions in healthy school-aged children. *J Ultrasound Med* 2005;24:1359-64.
25. Ehimwenma O, Tagbo MT. Determination of normal dimension of the spleen by ultrasound in an endemic tropical environment. *Niger Med J* 2011;52:198-203.
26. Okoye JJ, Agwu KK, Ochie K. Sonographic spleen sizes in normal adult Nigeria population. *West Afr J Radiol* 2005;12:37-43.
27. Dhingra B, Sharma S, Mishra D, Kumari R, Pandey RM, Aggarwal S. Normal values of liver and spleen size by ultrasonography in Indian children. *Indian Pediatr* 2010;47:487-92.
28. Soyupak SK, Narli N, Yapicioglu H, Satar M, Aksungur EH. Sonographic measurements of the liver, spleen and kidney dimensions in the healthy term and preterm newborns. *Eur J Radiol* 2002;43:73-8.

How to cite this article: Ezeofor SN, Obikili EN, Anyanwu GE, Onuh AC, Mgbor SO. Sonographic assessment of the normal limits of the spleen in healthy school children in South-East Nigeria. *Niger J Clin Pract* 2014;17:484-8.

Source of Support: Nil, **Conflict of Interest:** None declared.