

Right colon interposition in corrosive esophageal long segment stricture: Our local experience

JC Eze, FA Onyekwulu¹, IA Nwafor, K Etukokwn², O Orakwe³

Department of Surgery, UNTH, Enugu, ¹Department of Anaesthesia, UNTH, Enugu. ²Department of Surgery, FTH, Abakaliki, ³Department of Surgery, FMC, Asaba, Nigeria

Abstract

Background: Aim of our study is to highlight technical details in pedicled right colon interposition locally in cases of long segment corrosive esophageal stricture. Lesion results from cicatrization of burns wound inflicted by chemicals. Restoration of swallowing is of paramount importance.

Materials and Methods: It was a retrospective study involving adult and adolescent patients who had surgery because of corrosive esophageal stricture between January 2001 and December 2010. Hospital records were reviewed for age, sex, radiological findings, detail of anesthesia, operative procedure, and follow up. The steps which included mobilization of colon with intact marginal blood supply, safeguarding the middle colic artery that forms the pedicle, and doing three anastomoses that were leak proof were ascertained.

Result: There were 12 males (70.5%) and six females (29.4%) and age ranged from 14 to 45 years. Caustic soda caused the problem among 10 (58.8%) patients while liquid acid battery was involved in three (17.6%) patients. The rest were distributed equally between native concoction and unknown substance. All were done under general anesthesia and mean duration of the procedure was 306.8 ± 54.6 min with an average intra operative blood loss of 823.1 ± 428.5 ml. Sixteen (94.1%) had successful pedicle isolation and 15 (82.3%) patients had neither dysphagia nor reflux at follow-up.

Conclusion: Securing a pedicled right colon based on middle colic artery was a critical step. This surgical technique should be used to restore swallowing among patients with long segment esophageal stricture.

Key words: Colon interposition, corrosive esophageal stricture, nutrition, vascular pedicle

Date of Acceptance: 20-Sep-2013

Introduction

Corrosive esophageal stricture is one of the most important complications of chemical burns of esophagus.^[1] Prevention of the chemical from coming into contact with the esophagus will eradicate this problem.^[2] No age or sex is exempted. The victims do have cachexia, drooling of saliva, aspiration pneumonitis, bronchiectasis, and lung abscess.

Line of management is resuscitation, emergency gastrostomy, and subsequent colon replacement of esophagus.^[3] Some even die. Accidental ingestion was prevalent, thereby

serving as pointer to the haphazard nature of handling of these chemicals in our society.

The surgery which is a staged procedure has some complications. The ascending colon and part of transverse colon form the graft island pedicle. Maintenance of adequate nutrition during all the stages of treatment does help.

Paying heed to technical details during the colon interposition for esophageal replacement gives the

Address for correspondence:

Dr. John C. Eze, Cardiothoracic Unit,
Department of Surgery,
UNTH, PMB 01129, Enugu, Nigeria.
E-mail: johnc.eze@unn.edu.ng

Access this article online

Quick Response Code:	Website: www.njcponline.com
	DOI: ***
	PMID: *****

desired result. The steps at surgery include mobilization of right colon, securing the middle colic artery which is a branch of superior mesenteric artery as pedicle and doing esophagocolic, gastrocolic, and ileocolic anastomoses.

Some publications on this lesion have been made in Nigeria.^[4-8] This retrospective study is being undertaken to highlight the details of the operative procedure of already operated cases at this center in attempt at helping the victims. This surgical procedure is done currently in few centers in Nigeria and West African sub region because of lack of technical knowhow. Before the middle of 1980s, my center was not performing the operation and the current authors are locally trained showing that the regional residency program is producing appropriate manpower.

Materials and Methods

It was a retrospective study involving adult and adolescent patients who had surgery because of corrosive oesophageal stricture between January 2001 and December 2010. Following ethical approval, hospital records were reviewed for age, sex, symptoms, radiological findings, and details of operative procedure and follow-up. Data obtained were analyzed and presented in tabular forms. Analysis of data was by simple arithmetic and percentages.

Gastrostomy is usually done except in cases where there is gastric outlet obstruction from stricture. In such cases where the pylorus is not patent, jejunostomy is done instead of gastrostomy but later during colon interposition, gastrojejunostomy is used to maintain continuity of gastrointestinal tract (GIT). The aim of gastrostomy is to improve alimentation. Foley's catheter, size 34 or above is used in adult while smaller appropriate size will be used in adolescent. Weight gain to normal for age and sex is mandatory and protein estimation with other investigations is done serially. Few days before this surgical operation, work up of each patient included 5-day bowel preparation regimen with a combination of both chemical and mechanical methods.

At induction of anesthesia, parenteral antibiotic and metronidazole were given. Standard monitoring was carried out with pulse oximetry, electrocardiogram, capnography, and noninvasive arterial blood pressure. Patients were preoxygenated for 3 minutes and premedication was done with metoclopramide 10 mg, ranitidine 50 mg, and atropine 0.02 mg/kg. Induction of anesthesia was effected with propofol 2 mg/kg and suxamethonium 2 mg/kg. Endotracheal intubation was carried out by the anesthetist with the aid of McIntosh™ laryngoscope and appropriate size endotracheal tube. Patients were connected to the anesthetic machine and ventilator using the close system.

The patient was placed in supine position with the head

rotated to the right. The neck, chest, and abdomen were prepared using cetrimide solution and iodine in spirit. Drapes were applied to expose longitudinal narrow median parts of the neck, chest, and abdomen in continuity. Exposure was from just below the left ear to the pubis. The chest and head were slightly elevated with small soft block and head rest, respectively.

Through a long midline laparotomy incision from epigastrium to hypogastrium, abdominal viscera including the colon were exposed. Both diathermy and 2-0 silk ligatures were used to maintain haemostasis. The caecum is identified in the right lower quadrant and mobilized with terminal ileum and appendix. Through lateral retroperitoneal dissection, the ascending colon was mobilized up to hepatic flexure and its ligament was transected. The first step after right colon mobilization was inspection of the anatomy of vasculature of the right colon with confirmation of the presence of the normal middle colic artery and adequate, well-developed marginal artery. A critical area was the ileocecal region. It was common practice to include the terminal ileum and ileocecal valve.

Exposed second part of the duodenum was carefully preserved while isolating the colon. With aid of transillumination from theater light, ileal branch of ileo-colic artery, appendicular artery, right colic artery, and middle colic artery were identified as well as their arcades in the mesentery as these communicate.

Sequentially, ileal branch of ileo-colic and appendicular arteries were ligated between two artery forceps. The mesentery was breached on two sides of ileo-colic artery very close to its origin from the superior mesenteric artery. Vascular clamp or Bulldog clamp was temporarily applied to it while the cecum, appendix, and terminal ileum were assessed for viability. If there was no compromise to perfusion, another clamp was applied and it was then transected between the two clamps and suture-ligated with silk 2-0 or Prolene™ size 2-0.

Next was the right colic artery which was temporarily clamped close to its origin from superior mesenteric artery, just proximal to its first bifurcation. Viability of cecum, appendix, and ascending colon as well as pulsation of their arcades was checked. If the pink color was maintained and presence of pulsations was observed, another clamp was applied proximally, almost flush with the superior mesenteric artery. After transection, the distal end was ligated with 2-0 silk while the proximal end was suture ligated with 3-0 Prolene™ on the superior mesenteric artery. Warm mop, dripping with saline was applied to the isolated cecum, ascending colon, and part of transverse colon [Figure 1]. Securing a viable pedicled right colon is the critical point in this procedure and the colon will remain pink if the vascular pedicle is viable.

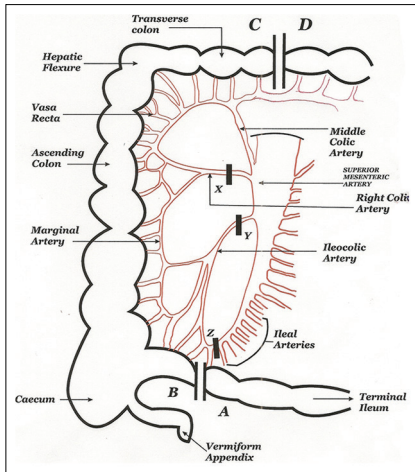


Figure 1: Schematic diagram showing the pedicle for the grafted colon

Through separate incisions in the mesentery, the terminal ileum was clamped with proximal non-crushing and distal crushing intestinal clamps, and thereafter transected. This was done very close to the cecum and appendix. The distal cecum was taken to the neck to assess the adequacy of length of colon required before transecting the transverse colon.

Blunt dissection of the sternal end of the laparotomy wound led into the retrosternal space which was the anterior mediastinum. Under the xiphoid process but superficial to the linea alba, the sternal origin of the diaphragm was identified. In the midline, the antero-median gap was located and through it the inferior retrosternal space was entered. This was widened to accommodate the transplanted colon [Figure 2].

Cervical incision was shaped like a hockey stick on the left side of the neck, along the medial border of sternocleidomastoid muscle and terminated at the suprasternal notch. Sternal end of sternocleidomastoid muscle was transected, while sternohyoid and superior belly of omo-hyoid were retracted laterally or transected. Thyroid gland and carotid sheath were retracted medially and laterally, respectively. Hemostasis was achieved with diathermy and ligatures. With both sharp and blunt dissection, the esophagus which lies behind the trachea was delivered into the cervical wound and put on a tape. The dissection of suprasternal notch allows entry into the thoracic inlet and this was advanced into the retrosternal space proximally. This was achieved with combined blunt and sharp dissection.

The transition between the distal strictured and proximal patent esophagus was defined. The oesophagus was clamped and transected proximal to the transition and the distal part was suture ligated with silk size 2 suture. The proximal esophagus was opened and communication with the mouth established by introducing naso-gastric tube or

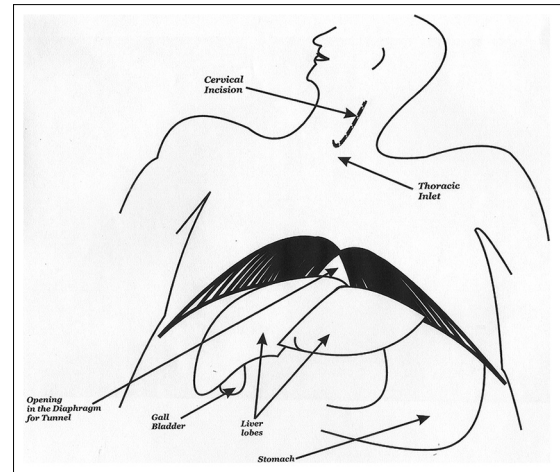


Figure 2: Schematic diagram showing the tunnel in the diaphragm

an esophageal dilator. The communication between the thoracic inlet and outlet retrosternally formed the passage for the pedicled colon graft.

The transverse colon was transected between non-crushing intestinal clamps at the point where adequate length for cervical anastomosis has been ascertained. A thoracic catheter was introduced through the thoracic inlet into the abdominal cavity. The terminal ileum and appendix were sutured to the catheter and dragged into the retrosternal space and into the cervical wound. Care was exercised over the state of the pedicle and viability was checked in the neck through both the color and the bleeding that occurred as appendectomy was done in the neck.

Ileocecal end was used in performing the cervical esophagocolic anastomosis. This anastomosis was done with continuous 2-0 linen or Vicryl™ or silk suture in two layers. Gastrocolic anastomosis was done using end of colon to side of the antrum and also in two layers between clamps in order to prevent both bleeding and spillage of colonic content. Ileo-colic anastomosis involved end of ileum to side of transverse colon [Figure 3]. Same type of suture was used in two layers, while the transected end of the transverse colon was suture ligated with size 2 silk. The gaps in the mesentery were closed with suture, thoracic catheter was introduced as drain in the abdominal cavity, and brought out at the right iliac fossa. As the three anastomoses were duly completed, hemostasis fully achieved, instruments and swabs counted, the abdominal wound was closed in layers. The cervical wound was closed loosely with interrupted sutures.

Anesthesia was maintained with 1% isoflurane in air-oxygen mixture and pancuronium. Intravenous morphine analgesic was also administered. Intra-operatively patients who developed bradycardia due to gut translocation receive intravenous atropine. Patients were extubated in the operating room after surgery and transferred to intensive care

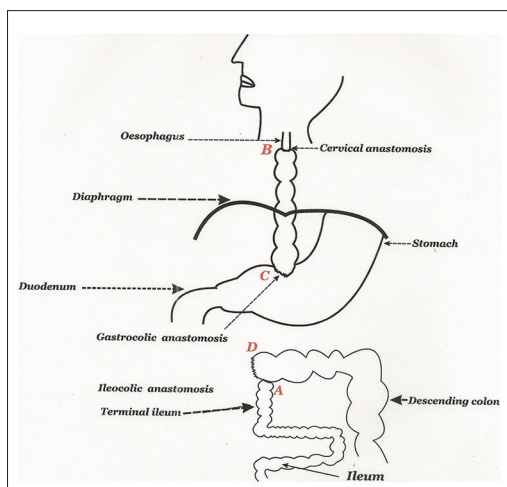


Figure 3: Schematic diagram showing the three anastomoses

unit (ICU) for effective post operative monitoring. Elective postoperative ventilation in the ICU was also offered to patients with poor respiratory function. The patients were nursed overnight at ICU and then transferred to regular ward. Oral feeding is restarted about 10 days post operatively.

Results

There were 12 (70.5%) males and five (29.4%) females. Their age ranged from 14 to 45 years with median age of 26 years [Table 1]. Majority of the cases were accidental ingestion of corrosive agent while three (17.6%) were suicidal bid. Sixteen (94.1%) patients received gastrostomy, while one (5.9%) patient had jejunostomy. The indications for colonic interposition graft are shown in Table 2. Long segment stricture accounted for 14 (82.3%) patients. Except one of the patients, 16 (94.1%) had successful isolation of the ileocolic, right colic, and middle colic arteries. That one patient had compromised ileocolic artery during the procedure with subsequent gangrene of the cecum post operatively. All the patients had retrosternal colon interposition.

The average post operative intensive care unit (ICU) stay was 28 h. The mean duration of the procedure was 306.8 ± 54.6 min with an average intra operative blood loss of 823.1 ± 428.5 mls. Three patients (17.6%) had early complication of cervical fistula and same number had reflux neo-esophagitis as shown on Table 3. Mid-term functional assessment of these patients through follow-up showed no dysphagia and no reflux among 15 (82.3%) of them from the time of the study, which is about a decade.

Discussion

Evidence of long segment tight esophageal stricture as shown on Barium swallow evaluation in Figure 3 was an indication for pedicled colon interposition.^[9] The

Table 1: Age distribution of patients

Age range in years	Number	Percentage
14-18	4	23.5
19-23	3	17.6
24-28	6	35.3
29-33	2	11.8
34-38	0	0
39-43	0	0
44-48	2	11.8
Total	17	100

Table 2: Indications for surgery

Indications	Frequency	Percentage
Long segment/multiple strictures	14	82.3
Undilatable strictures	2	11.8
Instrumental perforation	1	5.9
Total	17	100

Table 3: Early complications

Type of lesion	Number	Percentage
Hospital mortality	1	5.9
Graft infarction	1	5.9
Cervical fistulae	3	17.6
Reflux neo-esophagitis	3	17.6
Post-op intestinal obstruction	1	5.9

operation was carried out in the hospital main theater under general anesthesia with endotracheal intubation. Surgical intervention by esophageal substitution was the treatment of choice for patients who developed corrosive esophageal stricture refractory to dilatation. Repeated dilatation carries its own risk as the patient required frequent admissions to hospital and multiple anesthetics with inherent risks.^[7] Figure 3 is barium swallow showing patent retrosternal interposed colon of one of the patients.

Clinically, such patient presents with drooling of saliva, cachexia, dehydration, and esophageal lung syndrome. This esophageal lung syndrome has three components of aspiration pneumonitis, bronchiectasis, and lung abscess as a result of oesophageal obstruction from any cause and is different from esophageal lung. Esophageal lung is a congenital anomaly where the bronchus is connected to the esophagus instead of trachea and gives non functioning lung.

Severe dysphagia is a distressful condition for the patient and family.^[8] Optimizing the patient before esophageal replacement is paramount. Modalities to ensure that the nutrition of patient is adequate must be instituted before surgery. This is important for the healing process of all the anastomoses.

The aim of gastrostomy is to improve alimentation. Weight gain to normal for age and sex is mandatory and protein

estimation with other investigations is done serially. Work up of each patient included 5-day bowel preparation regimen with a combination of both chemical and mechanical methods. This has been adequately discussed in earlier publication.^[3] Some other authors have reported good outcome with use of one-day bowel preparation using mannitol drip through the gastrostomy tube. However, adequate attention must be paid to the electrolytes.

The organs used for esophageal replacement in patients after caustic injuries included stomach, jejunum, and colon.^[10,11] The colon has become a favored organ for interposition because of the ease of isolation of a segment and its concomitant vasculature with the marginal artery of Drummond.^[12] Ascending and part of transverse colon form the conduit of choice in the study center. It is less bulky as compared to descending colon.^[13] This arrangement is isoperistaltic, neck bulge is less, ileocecal valve is preserved, and the right colic artery is more sizeable and longer which makes it easier for mobilization. These are reasons why we prefer the right colon to the left.

General anesthesia with endotracheal intubation and muscle relaxation was the anaesthetic technique used for the surgery. The success of anesthesia and surgery depend on the preoperative optimization of the patient. Patients with chest infection due to repeated aspiration of saliva must be treated and in some cases esophagostomy is offered to reduce the risk. Good nutrition is important to prevent wound dehiscence. Moreover, anesthetic agents bind to serum proteins and lack of them may result in drug overdose. Premedication with metoclopramide and ranitidine is to prevent aspiration pneumonitis which might occur due to aspiration of gut content postoperatively as the protective esophageal sphincters are no longer relevant. Elective postoperative ventilation is necessary in those patients who develop poor respiratory function due to preoperative recurrent chest infection and in situation where the pleura is breached during the procedure.^[14] The breach in pleura in this state leads to open chest situation. The choice of anesthetic technique is to allow adequate muscle relaxation for effective mechanical ventilation and optimal surgical condition. During the colon transplant surgery, adequate ventilation, volume replacement, and control of arrhythmias are necessary for the success of the procedure.^[14] Thoracostomy is done with thoracic catheter connected to underwater seal drainage in any patient with breached pleura as a matter of protocol.

It cannot be overemphasized that the first step after right colon mobilization is inspection of the anatomy of vasculature of the right colon with confirmation of the presence of the normal middle colic artery and adequate, well-developed marginal artery. A critical area is the ileocaecal region. It is common practice to include the terminal ileum and ileocecal valve in the transplant,

but it is only visible when the marginal artery is obviously continuous in this region and the blood supply is adequate. The right colic and ileocolic arteries are sacrificed close to their origin from superior mesenteric artery to maintain the continuity of the marginal artery. The middle colic artery with both left and right branches form the vascular pedicle of the interposed colon [Figure 1].

The interposed colon is isoperistaltic in this case because the right colon was used, while Jiang, *et al.*, used the left colon.^[15] With our interposed colon in place, food bolus moves from the cervical esophagus into the interposed right colon through ileal end of right colon and enters the stomach through the transverse colon. Figure 3 shows what it looks like. Involvement of the terminal ileum may predispose to vitamin B deficiency anemia if excessive length is resected.^[16] Therefore, we always took extra precaution in dealing with the terminal ileum. Antiperistaltic conduit may cause inflammation of the anastomosis and affect the healing process and might as well cause more leakages of cervical anastomosis than isoperistaltic.^[17]

During the colon interposition, the residual esophagus is not resected but routinely left behind. Although the scarred and damaged esophagus might have an increased incidence of malignancy,^[18,19] an attempt to resect it at same sitting would add to morbidity and might be fatal.^[20] Esophagectomy and colon interposition at one stage do not share the same route as esophagectomy with transmediastinal placement of the stomach and cervical esophagogastronomy.^[7] The primitive esophagus will be taken out at second stage in our method.

The three anastomoses; esophagocolic, gastrocolic, and ileocolic anastomoses are hand sown; but we know that some centers use gastrointestinal anastomosis (GIA) stapler. The stapler helps to shorten the operation time among other benefits. Ileocolic anastomosis was end of ileum to side of transverse colon. The suture-ligated end of transverse colon was anchored to the proximal end of the transverse colon that was anastomosed to the antrum. This was in order to avoid disturbance of the middle colic artery, which was the pedicle and also pretty close to the colonic transection. By this arrangement, the middle colic artery remained lax and non migratory as it perfuses the graft. The use of the right colon pedicled on the right colic artery does not result in graft necrosis comparatively.^[21]

Colon patch esophagoplasty as mode of treatment is not our option of treatment in cases of long segment stricture. Esophageal stricture from reflux esophagitis that affects the lower oesophagus is a condition where esophagoplasty is commonly used to relieve the problem. This type of stricture usually involves short segment of the esophagus. Any other cause of such stricture at that site will benefit from esophagoplasty.^[22,23]

The cervical wound is closed loosely with interrupted sutures. This is very important in order to avoid tension that may compromise respiration and also cause necrosis of graft. The bulge and swelling occasioned by the cecum eventually subsides and neck wound heals uneventfully.

The adoption of this procedure is in line with the work of Watson, *et al.*,^[24] which concluded that restoration of pleasure of eating is viewed by patients to be successful as in Figure 3.

Conclusion

Securing a viable pedicled colon based on middle colic artery was a critical step. This surgical technique should be used to restore swallowing among unfortunate victims with long segment oesophageal stricture. Line of action should include resuscitation, gastrostomy, and subsequent right colon replacement of esophagus. The steps at surgery include mobilization of right colon, securing the middle colic artery which is a branch of superior mesenteric artery as pedicle and doing oesophagocolic, gastrocolic, and ileocolic anastomoses.

Acknowledgements

Our gratitude goes to God Almighty, the UNTH whose patients were included in this study and fellow consultants need special mention. We are grateful to Dr Charles Uzo for the graphics. All others who saw that the patients were attended to are hereby acknowledged as well.

References

- Goldman LP, Weigert JM. Corrosive substance ingestion: A review. *Am J Gastroenterol* 1984;79:85-90.
- Holinger PH. Management of oesophageal lesions caused by chemical burns. *Ann Otol Rhinol Laryngol* 1968;77:819-29.
- Eze JC, Ezemba N. Corrosive injury of upper gastrointestinal tract. In: Okechukwu Emmanuel Nwankwo, editor. *Essentials of Trauma Management and Related Principles of Surgery*. Ezu Books Ltd; 2011. p. 319-30.
- Anyanwu CH, Okonkwo PO. Oesophageal strictures induced by herbal preparations. *Trans R Soc Trop Med Hyg* 1981;75:864-8.
- Agugua NE. Colon bypass for corrosive oesophageal strictures in Nigerian children. *Int J Paed Surg Sci* 1988;2:7-10.
- Aghaji MA, Chukwu OC. Oesophageal replacement in adult Nigerians with corrosive stricture. *Int Surg* 1993;78:189-92.
- Adegbeye VO, Adebo OA, Brimo IA. Oesophagectomy without thoracotomy for corrosive oesophageal stricture. *Niger J Surg* 1995;2:62-6.
- Eze JC. Corrosive oesophageal stricture: A preventable scourge. *Orient J Med* 2003;15:8-11.
- Imre J, Kopp M. Arguments against long-term conservative treatment of oesophageal strictures due to corrosive burns. *Thorax* 1972;27:594-8.
- Hirschl RB, Yardeni D, Oldham K, Sherman N, Siplovich L, Gross E, et al. Gastric transposition for esophageal replacement in children: Experience with 41 consecutive cases with special emphasis on esophageal atresia. *Ann Surg* 2002;236:531-9.
- Erdogan E, Emir H, Eroglu E, Danismend N, Yeker D. Esophageal replacement using the colon: A 15-year review. *Pediatr Surg Int* 2000;16:546-9.
- Mansour kA, Hansen HA, Hersh T, Miller JI, Hatcher CR. Colon interposition for advanced nonmalignant esophageal stricture: Experience with 40 patients. *Ann Thorac Surg* 1981;32:584-91.
- Munkonge L. Challenges in the management of benign oesophageal strictures in zambians. *East Cent Afr J Surg* 2006;11:72-7.
- Ezike HA. Anaesthesia for oesophageal replacement with colon conduit: A review of forty six cases. *Niger Med J* 2008;49:70-3.
- Jiang Y, Lin Y, Wang R, Zouh J, Gong T, Ma Z, et al. Pharyngocolic anastomosis for esophageal reconstruction in corrosive esophageal stricture. *Ann Thorac Surg* 2005;79:1890-4.
- Rodgers BM, Talbert JL, Moazam F, Felman AH. Functional and metabolic evaluation of colon replacement of the esophagus in children. *J Pediatr Surg* 1978;13:35-9.
- Han Y, Cheng Q, Li Q, Wang X. Surgical management of esophageal strictures after caustic burns: A 30 years of experience. *World J Gastroenterol* 2004;10:2846-9.
- Kim YT, Sung SW, Kim JH. Is it necessary to resect the diseased esophagus in performing reconstruction for corrosive esophageal stricture? *Eur J Cardiothorac Surg* 2001;20:1-6.
- Davids PH, Bartelsman JF, Tilanus HW, van Lanschot JJ. Consequences of caustic damage of the esophagus. *Ned Tijdschr Geneesk* 2001;145:2105-8.
- Sarfati E, Gossor D, Assens P, Cetercer M. Management of caustic ingestion in adults. *Br J Surg* 1987;74:146-8.
- Ventemiglia R, Khalil KG, Frazier OH, Mountain CF. The role of perioperative mesenteric arteriography in colon interposition. *J Thorac Cardiovasc Surg* 1977;74:98-104.
- Hugh TB, Lusby RJ, Coleman MJ. Antral patch esophagoplasty. A new procedure for acid-peptic esophageal stricture. *Am J Surg* 1979;137:221-5.
- Hourang MH, Mehrabi V. Colon patch esophagoplasty: A clinical study for chemical burn esophagoplasty. *Internet J Surg* 2003;15:1.
- Watson TJ, DeMeester TR, Kauer WK, Peters JH, Hagen JA. Esophageal replacement for end-stage benign esophageal disease. *J Thorac Cardiovasc Surg* 1998;115:1241-7.

How to cite this article: ???

Source of Support: Nil, Conflict of Interest: None declared.