

Takayasu arteritis in young male

BS Patil, UG Rajoor

Department of Medicine, SDM College of Medical Sciences and Hospital, Manjushree nagar, Sattur, Dharwad, Karnataka, India

Abstract

Hypertension is one of the common diseases affecting general population. The World Health Organization has concluded that hypertension is the major factor responsible for the most deaths worldwide, 12.8% per year or more than seven million. Additionally hypertension is rated third on the list of factors responsible for the burden of disease during life, as measured by disability-adjusted life-years. The study, diagnosis and treatment of hypertension in the young constitute one of the major health challenges today, because of high percentage of potentially curable chance if the cause could be found. Indeed intensive study and investigations are required to unravel the underlying cause. Here we present a case of typical Takayasu arteritis presented with swelling in the right neck and hypertension.

Key words: Hypertension, takayasu arteritis, young adults

Date of Acceptance: 23-Sep-2012

Introduction

Hypertension is one of the commonest clinical conditions met in practice. Hypertension (HTN) in young is mostly of secondary type. Relatively small numbers of conditions are responsible for secondary HTN. Less than 5% of HTN was thought to be due to secondary causes and there has been much debate whether it is worthwhile to screen for secondary causes of HTN.^[1] Recent studies showed a much higher prevalence of secondary causes.^[2] The importance of diagnosing secondary HTN lies in the fact that it is potentially curable. Even if the underlying disease may not be curable, being able to offer disease specific treatments will often make blood pressure control much easier.^[2]

Case Report

A twenty one year male, previously healthy individual presented to the medicine outpatient department with complaints of swelling in the right neck and easy fatiguability of 15 days duration. Informed consent was obtained prior

to examination. On examination, patient was apparently healthy. His blood pressure was 190/110 mm Hg in right upper limb and 160/92 mm Hg in left upper limb. Left upper limb pulses were feeble and hardly palpable and there was radio radial delay but no radio femoral delay. Painless pulsatile swelling noted in right upper part of the neck [Figure 1] and there was bruit over left subclavian artery. The remaining clinical and neurological examinations were unremarkable.

Investigations

Hemoglobin-12.6 gm%, Erythrocyte sediment rate-45 mm/1st hr, renal parameters and serum electrolytes were normal. Chest x-ray showed tortuous descending aorta. No radiological abnormality noted in lung fields. Electrocardiography, fundus, ultrasonography of abdomen, renal arterial doppler, echocardiography are all normal. Venereal Disease Research Laboratory (VDRL) test and Tubercular antibodies were negative.

Address for correspondence:

Dr. Umesh. G. Rajoor, Associate Prof.,
Department of Medicine, SDM College of Medical Sciences and Hospital, Manjushree nagar, Sattur, Dharwad, Karnataka, India.
E-mail: drumeshrajoor@gmail.com

Access this article online

Quick Response Code:



Website: www.njcponline.com

DOI: 10.4103/1119-3077.116913

PMID: *****

Carotid and vertebral arterial Doppler: Both the common carotid arteries showed variability in luminal caliber with irregular wall thickening, with evidence of 78% area stenosis involving proximal left common carotid artery. Multiple saccular aneurysms evident are the most prominent one in the region of right carotid bulb/bifurcation. Similar wall thickening evident are in both subclavian arteries. Findings were in favour of diffuse large vessel vasculitis.

MR angiography (aortic arch to circle of willis)

Diffuse irregular mural thickening with variable luminal stenosis and associated pre and post stenotic dilatation involving predominantly the arch of aorta [Figure 2a, b, c), descending thoracic aorta [Figure 2d], brachiocephalic trunk, both subclavian arteries and common carotid arteries. Right common carotid artery shows multiple saccular aneurysms of variable sizes, largest of them noted close to carotid bifurcation [Figure 2b, c]. Both subclavian arteries shows similar but minimal mural thickening. The descending thoracic aorta shows mural thickening with large fusiform aneurysm and mural ulcerations. Abdominal aorta and renal arteries are normal. Findings were in favour of large vessel vasculitis-Takayasu arteritis with aortic arch involvement. Initially he was started with amlodipine 5 mg bid; blood pressure was not under control, later added metoprolol 50 mg bid. After MRI he was started with prednisone 1 mg/kg/day and losartan 50 mg bid, as angiotensin receptor blockers/angiotensin converting enzyme inhibitors are drugs of choice as the renovascular hypertension is very common in such patients. At present patient is on tapered dose of prednisone (10 mg/day). His blood pressure is well controlled with losartan 50 mg bid. Clinically aneurysm in the neck is regressing and there is no clinical evidence of occlusion.

Discussion

Hypertension in young is mostly of secondary type. In young adults without family history of hypertension and with persistent hypertension, most commonly due to renal

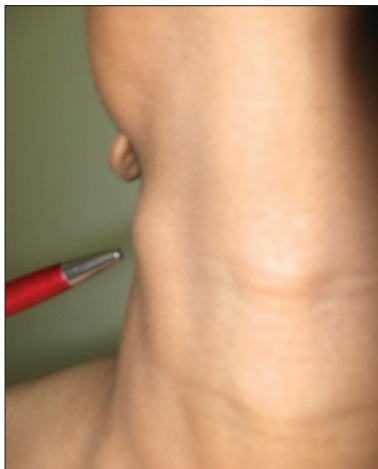


Figure 1: Pulsatile swelling in the right upper part of the neck

causes. Most of the underlying diseases are rare. Most of them if diagnosed early are potentially curable. There are no well co-ordinated national surveys of the prevalence of HTN available from the Indian subcontinent. Pooling of epidemiological studies shows that HTN is present in 25% urban and 10% rural subjects in India. At an underestimate, there are 31.5 million hypertensive in rural and 34 million in urban population.^[3] The prevalence of HTN in young adults is about 5%.^[4]

Causes of HTN in young^[5] Primary (essential or idiopathic) hypertension (~80-95%) and Secondary hypertension (~5-20%) [Table 1]

Takayasu's arteritis is a large vessel vasculitis of unknown etiology that involves aorta and its major branches.^[7] The disease is characterized by a specific predilection for females. Female: Male varies from 9:1 in Japan to 1.6:1 in India.^[8,9] The average age of Indian patients is between 25-30 yrs. Based upon the type and extent of involvement, now the disease is classified of 5 anatomical subtypes.^[10,11] Type I: Branches of aortic arch involvement, Type IIa: Ascending aorta, aortic arch and its branches, Type IIb: Ascending aorta, aortic arch and its branches, thoracic descending aorta, Type III: Thoracic descending aorta, abdominal aorta and/or renal arteries, Type IV: Abdominal aorta and/or renal arteries, Type V: Combination type IIb and IV. Involvement of coronary or pulmonary artery is designated as C (+) or P (+) along with any one of the types. The frequency of involvement of the abdominal aorta and/or renal arteries is higher in Indian patients when compared to Japanese patients.^[12] HTN is the most common mode of presentation in Asian patients and is detected up to 90% of patients on examination. The pathogenesis of HTN includes renal ischemia due to renal artery stenosis (unilateral/bilateral), loss of vascular compliance and an increased sensitivity of carotid sinus reflex. Diagnostic criteria proposed by American College Rheumatology^[12] (1990):-a) age <40 yrs, b) claudication of an extremity, c) absent, decreased or unequal pulses, d) a difference of more than 10 mmHg systolic blood pressure between 2 limbs, e) a bruit over subclavian arteries or aorta f) Angiographic evidence of narrowing or occlusion of aorta and its branches. Treatment: Medical management comprises of steroids

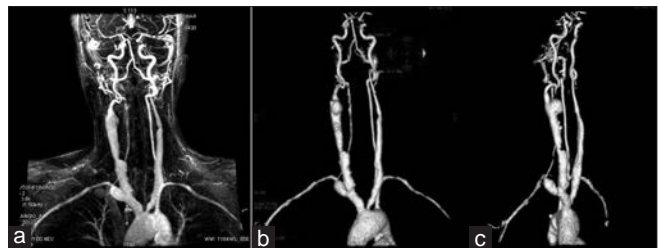


Figure 2: (a) Irregular mural thickening in arch of aorta. (b) Right common carotid artery shows multiple saccular aneurysms. (c) mural thickening noted in descending thoracic aorta

Table 1: Causes of secondary HTN

Renal (2.5-6%) ^[6]
Parenchymal disease (2-3%)
Chronic glomerulonephritis
Chronic pyelonephritis
Polycystic kidney disease
Renovascular hypertension (1-2%)
Atherosclerosis
Fibromuscular dysplasia
Coarctation of aorta
Collagen vascular disease
Endocrine (1-2%)
Primary aldosteronism
Cushing's syndrome
Pheochromocytoma
Hyperthyroidism and hypothyroidism
Hyperparathyroidism
Pregnancy-induced hypertension
Drugs and toxins: Examples-cocaine, amphetamines, alcohol

during the phase of activity and treatment of HTN and other complications during the occlusive phase. Prednisolone 0.5-1 mg/kg/day; Total duration of therapy is controversial. The usual maintenance dose is administered for 3-6 months and tapered over next 2 or 3 years. Surgical treatment is reserved for symptomatic lesions of prognostic significance. These lesions include stenosed segment of aorta producing severe HTN or ischemia of an organ, atypical coarctation, renovascular HTN, Aortic regurgitation and symptomatic aneurysm.

Learning points:

1. Proper clinical examination is essential.
2. Appropriate BP measurement with verification in contra lateral arm.
3. Palpation of all peripheral pulses is important.
4. Auscultation for carotid, abdominal and femoral bruits.

Conclusion

In young hypertensive secondary causes are commonly found. Renal, endocrine and cardiovascular diseases account for most of the cases. If underlying causes are corrected, most of the secondary forms of hypertension are curable. So in young hypertensive patients, a high index of suspicion may enable a physician to make a timely diagnosis and hence avert the potentially disastrous complications that may arise in undetected patients.

References

1. Danielson M, Dammstrom B. The prevalence of secondary and curable hypertension. *Acta Med Scand* 1981;209:451-5.
2. Wing-bun Chan. Endocrine Hypertension-Strategy for Screening and Workup. *The Hong Kong Medical Diary* 2006;11:12-16.
3. Muruganathan A. Hypertensive emergencies-a clinical, practical update. Vol. 24. In: Postgraduate medicine-contemporary medicine-challenges and solutions; 2010. p. 109-16.
4. Bechung Ooi BS, Chen BT, Toh CC, Khoo OT. Causes of hypertension in the young. *Br Med J* 1970;2:744-6.
5. Kotchen TA. Hypertensive vascular disease. In: Harrison's principle of internal medicine. 17th ed. Mc Graw-hill's; 2008. p. 1553-4.
6. Panja M, Kumar S, Sarkar CN, Sinha DP, Ray S, Chatterjee A, et al. Hypertension in the young in Eastern India. *Indian Heart J* 1996;48:663-6.
7. Kerr GS, Hallahan CW, Giordano J, Leavitt RY, Fauci AS, Rottem M, et al. Takayasu arteritis. *Ann Intern Med* 1994;120:919-29.
8. Jain S, Kumari S, Ganguly NK, Sharma BK. Current status of Takayasu arteritis in India. *Int J Cardiol* 1996;54 suppl:111-6.
9. Panja M, Mondal PC. Current status of aortoarteritis in India. *J Assoc Physicians India* 2004;52:48-52.
10. Moriwaki R, Noda M, Yajima K, Sharma BK, Numano F. Clinical manifestation of Takayasu arteritis in India and Japan-new classification of angiographic findings. *Angiology* 1997;48:369-70.
11. Hata A, Noda M, Moriwaki R, Numano F. Angiographic findings of Takayasu arteritis-new classification. *Int J Cardiol* 1996;54:155-63.
12. Arend WP, Michel BA, Bloch DA, Hunder GG, Calabrese LH, Edworthy SM, et al. The American college of Rheumatology 1990 criteria for the classification of Takayasu's arteritis. *Arthritis Rheum* 1990;33:129-34.

How to cite this article: Patil BS, Rajoor UG. Takayasu arteritis in young male. *Niger J Clin Pract* 2013;16:548-50.

Source of Support: Nil, **Conflict of Interest:** None declared.