

Angiodysplasia of the colon: A report of two cases and review of literature

AB Olokoba, OA Obateru, SA Olatoke¹

Departments of Medicine, ¹Surgery, University of Ilorin Teaching Hospital, Ilorin, Nigeria

Abstract

Angiodysplasias of the colon are enlarged and fragile blood vessels in the colon result in occasional loss of blood from the lower gastrointestinal tract. It may be observed incidentally at colonoscopy or patients may present with lower gastrointestinal bleeding. The objective of this case report is to highlight two cases of colonic vascular ectasia seen using a Pentax video colonoscope at the Endoscopy unit of Crescent hospital, Ilorin. The first patient is an 85-year-old man, who presented with constipation, left-sided abdominal pain, and weight loss of two weeks duration. There was no anorexia, abdominal swelling, diarrhea, or hematochezia. Abdomino-pelvic ultrasonography showed normal findings. Colonoscopy done, reaching the ileo-cecal valve and caecum, showed an area of dilated tortuous blood vessel (vascular ectasia) in the wall of the descending colon approximately 45 cm from the anal verge, with no features of bleeding. No ulcers or mass lesion was seen. Colonoscopy showed angiodysplasia of the colon. The second patient is a 30-year-old female trader who presented with two days history of massive hematochezia of about 7 episodes prior to presentation with an estimated blood loss per episode of about 300 ml. There were clinical features of shock. Packed cell volume at presentation was 14%. She was transfused with 4 units of fresh whole blood. Post stabilization, colonoscopy was done 5 days after bleeding had stopped, which revealed an area of erosion with mucosal blood clot about 27 cm from the anal verge. An area of angiodysplasia was seen. No hemorrhoids or mass lesion was seen anywhere in the colon. Angiodysplasia is an uncommon finding in Ilorin. These are the first reported cases of angiodysplasia of the colon from Ilorin, Nigeria.

Key words: Angiodysplasia, bleeding, colon, colonoscopy

Date of Acceptance: 22-Apr-2011

Introduction

Angiodysplasias, arteriovenous malformations or angiomas are the commonest vascular lesions of the gastrointestinal (GI) tract.^[1] They are enlarged, fragile blood vessels in the colon. It is a common cause of lower GI bleeding in the elderly.^[1,2] It may be asymptomatic and discovered incidentally during colonoscopy.^[3] Patients may present with hematochezia, melena, positive occult blood test or iron deficiency anemia.^[4] It may present as an isolated lesion or multiple vascular lesions.^[5] The exact cause of vascular ectasia is not known but it is thought to occur due to ageing

and degeneration of blood vessels.^[1] An hypothesis states that it is due to contraction of the muscular layer leading to partial occlusion of the sub-mucosal veins of the intestinal wall, subsequently the veins become tortuous and dilated.^[1] It predominantly affects the cecum and right side of the colon.^[3,4] It could also affect any part of the large bowel.^[5] Angiodysplasias have been reported in association with aortic stenosis, chronic renal failure, Von willibrand's disease and cirrhosis of the liver.^[6,7] The incidence of angiodysplasias is 0.8% in healthy people undergoing screening with

Address for correspondence:

Dr. AB Olokoba,
Department of Medicine, Division of Gastroenterology,
University of Ilorin Teaching Hospital, P.M.B 1459, Ilorin,
Kwara state, Nigeria
E-mail: drabolokoba@yahoo.com

Access this article online

Quick Response Code:



Website: www.njcponline.com

DOI: 10.4103/1119-3077.94110

PMID: 22437102

colonoscopy in the US.^[5,8] The incidence in other parts of the world is not known because of paucity of data.

There is no sex predilection. It is found predominantly in elderly people above the age of 65 years.^[5] Diagnosis of angiodysplasias may be made using colonoscopy, angiography, and computed tomography (CT) scan and endoscopic forceps biopsy, which may reveal characteristic histopathologic features of dilated, distorted, thin-walled vessels, however they are not generally recommended because of low diagnostic yield and risk of bleeding.^[9] Treatment could be conservative, medical, endoscopic or surgical treatment, but because of risk of re-bleeding surgical treatment is thought to be the best modality of treatment.^[4] However, treatment should be individualized depending on severity.^[4]

Case Reports

Case 1

The patient is an 85-year-old Nigerian farmer who presented with constipation, left-sided abdominal pain and weight loss all of two weeks duration. There was no anorexia, abdominal swelling, diarrhoea or haematochezia. A physical examination was unremarkable. No abnormality was detected on digital rectal examination. Abdomino-pelvic ultra- sonography showed normal findings. Colonoscopy done, reaching the ileo-cecal valve and caecum, showed an area of dilated tortuous blood vessel (vascular ectasia) in the wall of the descending colon approximately 45cm from the anal verge, with no features of bleeding [Figures 1 and 2], with no other abnormalities seen in the bowel mucosa. No ulcers or mass lesion was seen. Upper gastrointestinal tract endoscopy done was normal. The patient is presently being followed up.

Case 2

The second patient is a 30-year-old female trader who presented with two days history of massive hematochezia of about 7 episodes prior to presentation with an estimated blood loss per episode of about 300 ml. There were clinical features of shock. Packed cell volume at presentation was 14%. She was transfused with 4 units of fresh whole blood. After stabilization, colonoscopy was done 5 days after bleeding had stopped, which revealed an area of erosion with mucosal blood clot about 25 cm from the anal verge [Figure 3]. An area of angiodysplasia was seen. There was no evidence of further bleeding. No hemorrhoids or mass lesion was seen anywhere in the colon. Upper gastrointestinal tract endoscopy done was normal. She was however discharged on request for follow-up on account of financial constraints.

Discussion

Angiodysplasia though rare in this part of the world, is known to be one of the commonest causes of lower GI

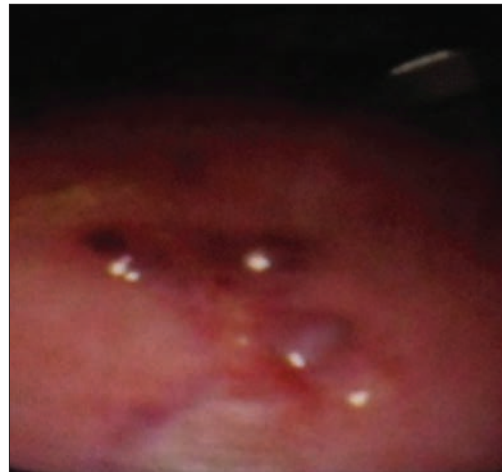


Figure 1: Dilated and tortuous blood vessels in the colon

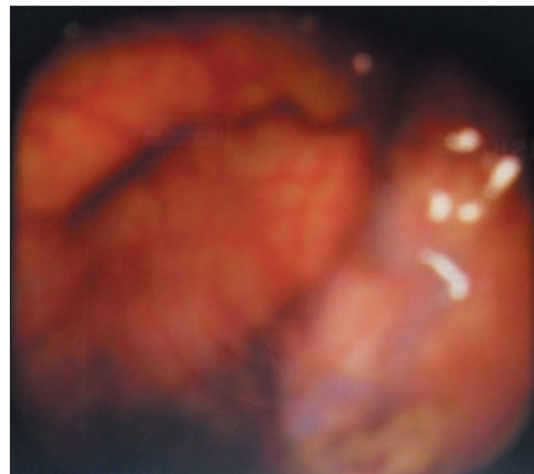


Figure 2: Dilated and tortuous vessels in the colon

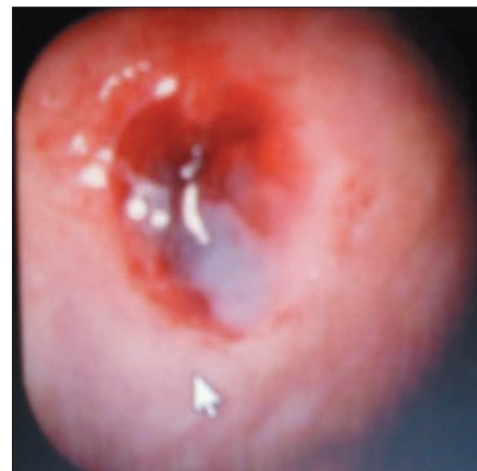


Figure 3: An area of mucosa blood clot (angiodysplasia) in the colon

bleeding in the elderly above 65 years of age. Cases of angiodysplasia in individuals less than 40 years have been documented in the literature.^[5,10] It may be asymptomatic, or present with iron deficiency anemia or positive occult

blood. It could also be a cause of massive lower GI bleeding. In our report, the first patient was an 85-year-old man who had left-sided abdominal pain, constipation, and weight loss with no symptoms of blood loss. The second patient was a 30-year-old woman who presented with a life threatening lower GI bleeding. The vascular lesions may be single or multiple. In our report, the first case was multiple while the second was single. Angiodysplasias are incidental findings in 2% of non-bleeding elderly people above 65 years.^[5] Most angiodysplasias are located at the cecum and right side of the colon. However, the first case was seen on the left side of colon, while the second was seen in the region of the sigmoid colon about 25 cm from the anal verge. Both patients need to be followed up in case they eventually require endoscopic intervention (injection therapy, multipolar coagulation, contact probes, and lasers) or surgical resection of the left colon and rectum, which is the definitive treatment for the condition especially for life threatening lower GI hemorrhage due to angiodysplasias.^[5]

Upper gastrointestinal tract endoscopy carried out in both patients were normal. However, further evaluation of the two cases using imaging techniques such as CT scan and angiography could not be done.

Conclusion

Colonic vascular ectasia may be asymptomatic or cause life threatening lower GI bleeding. Therefore, treatment

should be individualized. These are the first reported cases of colonic vascular ectasia from Ilorin.

References

1. de La Fuente SG, Mantyh RC. Colonic arteriovenous malformations. In: Prayor AD, editor. Gastrointestinal bleeding part 2. Durham (USA): Springer science; 2010. p. 151-61.
2. Brandt LJ, Spinnell MK. Ability of naloxone to enhance the colonoscopic appearance of normal colonic vasculature and colonic vascular ectasia. *Gastrointest Endosc* 1999;49:79-83.
3. Regular J, Wronsa E, Pachlewski J. Vascular lesions of the gastrointestinal tract. *Best Pract Res Clin Gastroenterol* 2008;22:313-28.
4. Sharma R, Gorbien MJ. Angiodysplasia and lower gastrointestinal tract bleeding in elderly patients. *Arch Intern Med* 1995;155:807-12.
5. Siddique K, Ali Q, Mirza S, Malik AZ. Massive lower gastrointestinal hemorrhage in a patient with colonic angiodysplasia. *Int J Surg* 2009;20.
6. Foutch PG. Angiodysplasias of the gastrointestinal tract. *Am J Gastroenterol* 1993;88:807-9.
7. Naveau S, Leger-Ravet MB, Houdayer C, Bedossa P, Lemaigre G, Chaput JC. Non hereditary colonic angiodysplasias: Histomorphometric approach to their pathogenesis. *Dig Dis Sci* 1993;40:839-42.
8. Kakushimi N, Fujishiro M, Yahaji N, Oka M, Kobayashi K, Hashimoto T, et al. An unusual case of polypoid angiodysplasia. *Endoscopy* 2004;36:379.
9. Duchini A, Godino J, Wong P, Patti M, Talavera F, Achord JL, et al. Angiodysplasia of colon. Available from: <http://www.emedicine.com/med/topic134.htm> [last accessed on 2008 Jul 17].
10. Greason KI, Costa JA, Magrino TJ, Cheo M. Angiodysplasia as a cause of massive lower gastrointestinal bleeding in young adults. Report of a case. *Dis Colon Rectum* 1996;39:702-4.

How to cite this article: Olokoba AB, Obateru OA, Olatoke SA. Angiodysplasia of the colon: A report of two cases and review of literature. *Niger J Clin Pract* 2012;15:101-3.

Source of Support: Nil, **Conflict of Interest:** None declared.

Announcement



Download
iPhone, iPad
application

FREE

A free application to browse and search the journal's content is now available for Android based mobiles and devices. The application provides "Table of Contents" of the latest issues, which are stored on the device for future offline browsing. Internet connection is required to access the back issues and search facility. The application is compatible with all the versions of Android. The application can be downloaded from <https://market.android.com/details?id=comm.app.medknow>. For suggestions and comments do write back to us.