

Immunohistochemical detection of Her-2/neu overexpression in breast carcinoma in Nigerians: A 5-year retrospective study

EE Ugiagbe, AN Olu-Eddo, DE Obaseki

Department of Pathology, University of Benin Teaching Hospital, Benin City, Nigeria

Abstract

Objective: To determine the pattern of Her-2/neu status among breast carcinoma in the University of Benin Teaching Hospital, Benin City, Nigeria.

Materials and Methods: Immunohistochemical staining for Her-2/neu was performed on 10% formalin-fixed, paraffin-embedded primary carcinoma of the breast from 83 patients, between 2003 and 2007 using anti-Her-2/neu rabbit polyclonal antibody (DakoCytomation, CA, USA) and reactivity detected by an avidin-biotin immunoperoxidase method. The clinicopathologic parameters analyzed were patients' age, histological types, and tumor grade. The Her-2/neu Dako scoring system was used.

Results: During the 5-year period, 83 histologically confirmed cases of invasive breast carcinoma were assessed for Her-2/neu status. These included 67 (80.7%) cases of invasive ductal carcinoma, nine cases of invasive lobular carcinoma (10.8%), three cases of medullary carcinoma (3.6%), two cases of papillary carcinoma (2.4%), and a case each of mucinous and clear cell carcinoma (1.2%). Mean age of patients was 48.9 ± 13.6 years with an age range of 25 to 83 years. Only nine (10.8%) cases showed immunopositivity for Her-2/neu. Seven of these were cases of invasive ductal carcinoma, while two were invasive lobular carcinoma. Tumors were predominantly high grade with grade III, II, and I accounting for 42, 28, and 13 cases, respectively. There was no significant correlation between patient age, the various histological types, tumor grade, and Her-2/neu positivity.

Conclusions: This study indicates that Her-2/neu may not be useful in defining the prognosis of breast cancer in this environment. Nevertheless, it highlights the need for routine immunostaining for Her-2/neu before institution of trastuzumab (Herceptin) therapy.

Key words: Breast cancer, Her-2/neu, immunohistochemistry

Date of Acceptance: 8-Feb-2011

Introduction

Breast cancer is the commonest site-specific malignancy affecting women in Nigeria and worldwide with several reports indicating a rising incidence.^[1,2] The increasing incidence and significance of breast cancer mortality highlights the need for development of new therapeutic, highly targeted treatment. A humanized monoclonal antibody, trastuzumab (Herceptin), targeting the Her-2/

neu gene product, is a prime example of this new class of treatment.^[3]

The Her-2/neu gene (*c-erb-2*), a proto-oncogene located on chromosome 17q21, encodes a 185-kDa transmembrane glycoprotein with intracellular tyrosine kinase activity. It is

Address for correspondence:

Dr. Ezekiel Enoghama Ugiagbe,
Department of Pathology, University of Benin Teaching Hospital,
Benin City, Nigeria.
E-mail: ugiagghama@yahoo.com

Access this article online

Quick Response Code:



Website: www.njcponline.com

DOI: 10.4103/1119-3077.86779

PMID: 22037080

a member of the epidermal growth factor receptor family.^[4,5] There are four known members of this gene, HER-1, HER-2, HER-3, and HER-4.^[4,6] Several peptide growth factors bind to different members of this family. Depending on the relative concentrations of ligands and receptors, the four members of the family interact to create hetero- or homodimers, resulting in activation of diverse subcellular signal transduction pathways. Her-2/neu gene is thus critical in the control of growth, differentiation, and mobility of many normal and transformed epithelial cell types.^[4]

Several methods have been employed to evaluate Her-2/neu gene amplification or overexpression;^[4] of these, the fluorescent in-situ hybridization (FISH) and immunohistochemistry (IHC) are the most commonly used. Various studies have shown an 80 to 90% concordance between IHC and FISH methods.^[7] Significantly, Huang *et al.*^[8] in Belgium assessed the Her-2/neu expression of 1 688 cases of breast cancer and found a 100% concordance rate between IHC and FISH. The FISH method has the advantage of low interobserver variability and a high degree of reproducibility. Nevertheless, FISH is expensive and generally too labor intensive to be performed routinely in most hospital settings.^[7] Immunohistochemical evaluation of Her-2/neu gene overexpression therefore represents a clinically attractive choice because of its low cost, biological relevance, and technical availability in most pathology laboratories including those in low resource settings.^[3]

Population-based studies have shown that overexpression of Her-2/neu gene is an adverse prognostic factor commonly associated with poorly differentiated high-grade tumors with high rates of cell proliferation and lymph node involvement. These tumors have relative resistance to endocrine therapy and alkylating agent-based chemotherapy and benefit greatly from anthracycline-based chemotherapy.^[4,9,10] In addition to the prognostic value of Her-2/neu, trastuzumab (Herceptin), a humanized monoclonal antibody against Her-2/neu, has been shown to be an effective breast cancer therapeutic agent and is presently approved by the Food and Drug Administration for the treatment of breast cancer.^[3,5] Combining Herceptin with either single or multiple chemotherapeutic agents increases therapeutic efficacy and prolongs patients' survival.

Though many studies on the patterns of breast cancer have been carried out in this environment using routine hematoxylin and eosin (H and E)-based morphological diagnosis with occasional special histochemical staining method, ancillary investigations such as IHC were hardly ever used. In the University of Benin Teaching Hospital (U.B.T.H), as in most other centers in Nigeria, no immunohistochemical determination of Her-2/neu overexpression in breast carcinoma has been done. The aim of this study is to establish a preliminary data on the pattern of Her-2/neu status in breast carcinoma in this

environment. Information derived would provide a baseline for research and help in formulating management policies for breast cancer.

Materials and Methods

All breast specimens (biopsy or mastectomy) received in the Department of Pathology, University of Benin Teaching Hospital, Benin City, Nigeria for a 5-year period (January 2003 - December 2007) were reviewed. All histologically confirmed cases of carcinoma of the breast formed the focus of this retrospective study.

Clinical and demographic data regarding age, gender, and clinical information were obtained from request cards and the surgical day books of the department. Slides were retrieved from the archives of the Department of Pathology. When necessary, new slides were made from formalin-fixed, paraffin-embedded blocks.

Classification and grading

H and E slides of the cases were classified histologically using the World Health Organization Classification of Breast Cancer 2003, and graded using the Nottingham modification of the Bloom-Richardson grading system.^[11,12] Paraffin blocks were cut to produce fresh H and E-stained sections where the already prepared slides were faded or missing.

Immunohistochemical staining

Representative formalin fixed, paraffin-embedded blocks (by H and E slides assessment) of the cases were retrieved and fresh sections, 3- μ m thick, were produced on lysine-coated slides and deparaffinized in xylene, rehydrated in graded series of alcohol, and were immunostained using avidin-biotin immunoperoxidase staining method. For antigen retrieval, sections were then placed in 0.01M citrate buffer at pH 6.0 and heated in a steamer for 40 minutes at 95°C. Endogenous peroxidase activity was eliminated by incubation in 3% hydrogen peroxide for 10 minutes. Anti-Her-2/neu rabbit polyclonal antibody (DakoCytomation, CA, USA) was used as the primary antibody at a dilution of 1 : 3 000. A secondary biotinylated goat anti-rabbit antibody at a dilution of 1 : 1 000 was used and reactivity detected by an avidin-biotin immunoperoxidase system employing 3'-diaminobenzidinetetrahydrochloride as the chromogen. Previously stained slides which accompanied antibody batches obtained from the USA served as positive and negative controls.

Staining intensity of immunohistochemically stained sections was semiquantitatively evaluated using the DAKO scoring system for Her-2/neu. A zero score defines tumors with no staining or membrane staining in less than 10% of the tumor cells, while 1+ refers to tumors with a faint membrane staining in more than 10% of the tumor cells.

A weakly positive result characterized by weak to moderate complete membrane staining in more than 10% of the tumor cells is represented by a 2+ score, while a strongly positive result defined as strong complete membrane staining in more than 10% of the tumor cells is represented as 3+. Scores of 0, 1+, or 2+ were classified as negative, while a score of 3+ was regarded as positive.

Statistical analysis was done using the SPSS (15) statistical package.

Ethical clearance was obtained from the Ethical Committee of the University of Benin Teaching Hospital to carry out this study.

Results

During the 5-year study period, 662 mastectomy and breast biopsy specimen were received in the Department. Of these, 273 (41%) cases were malignant, while 387 (59%) cases were benign. Of the 273 cases of breast cancer, 83 (30.4%) cases were enrolled for this study, having met the requirement for immunohistochemical studies. All cases with inadequate clinical information and poorly preserved blocks were deleted from the study.

Table 1 shows the frequency of Her-2/neu staining of the cases studied. Most of the cases (67 [80.7%]) had no (0) staining. There were three (3.6%) cases with 1+ staining, four (4.8%) cases with 2+ staining, while nine (10.8%) cases had 3+ staining pattern. In all, 74 (89.2%) cases were classified negative with a staining of 0, 1+, or 2+, while nine (10.8%) cases were regarded as positive with a 3+ staining.

Table 2 shows the age and sex distribution of patients and their Her-2/neu status. There were 81 (97.6%) females and two (2.4%) males. The mean age of the cases studied was

48.9 ± 13.6 with an age range of 25 to 83 years. The mean age of Her-2/neu-positive cases was 49.8 ± 15.6 years with an age range of 30 to 75 years, while the mean age of Her-2/neu-negative cases was 48.8 ± 13.4 years with an age range of 25 to 83 years. The highest number of Her-2/neu-positive cases occurred in the 30 to 39 years age group.

Of the 81 cases of breast carcinoma in females, nine (10.8%) cases showed Her-2/neu positivity, while 72 (86.8%) cases demonstrated negative staining. The two (2.4%) cases of male breast carcinoma encountered showed negative immune staining for Her-2/neu.

Table 3 depicts the immunostaining pattern of the various histological types of breast carcinoma. Of the 67 (80.9%) cases of invasive ductal carcinoma encountered, seven cases showed positivity for Her-2/neu, while 60 cases were negative. Invasive lobular carcinoma accounted for nine (10.8%) cases. Two of these cases were Her-2/neu positive, while seven cases were Her-2/neu negative. Medullary, papillary, mucinous, and clear cell carcinoma constituted three (3.6%), two (2.4%), one (1.2%), and one (1.2%) case, respectively, and were all negative for Her-2/neu. There was no significant correlation between the various histological types and Her-2/neu positivity ($\chi^2 = 2.068$, $df = 5$, $P = 0.840$).

Table 4 shows the correlation of Her-2/neu status with the histological grade of tumors. Grade III tumors predominated accounting for 42 (50.6%) cases. These included four cases showing Her-2/neu positivity and 38 cases showing negative staining. Grade II tumors accounted for 28 (33.7%) cases. Three of these showed positive immune staining for Her-2/neu, while 25 were negative. Only 13 (15.7%) cases of grade I tumors were encountered, of which, two were Her-2/neu positive, while 11 were negative. There was no statistically significant association between tumor grade and Her-2/neu status ($\chi^2 = 0.353$, $df = 2$, $P = 0.838$).

Figures 1-4 show the immunohistochemical staining pattern of some of the cases studied.

Table 1: Frequency of Her-2/neu staining pattern

Her-2/neu staining	Frequency	Percentage
0	67	80.7
1+	3	3.6
2+	4	4.8
3+	9	10.9
Total	83	100.0

Table 2: Age and sex distribution of Her-2/neu status

Sex Her-2/neu status	Age group							Total
	20-29	30-39	40-49	50-59	60-69	70-79	80-89	
Female								
HER/2 positive	-	3	1	2	2	1	-	9
HER/2 negative	2	18	20	18	11	2	1	72
Male								
HER/2 positive	-	-	-	-	1	1	-	2
HER/2 negative	-	-	-	-	-	-	-	-
Total	2	21	21	20	14	4	1	83

Discussion

The incidence of breast cancer is increasing in many developing countries, and in Nigeria, it has overtaken

Table 3: Distribution of Her-2/neu among histological types of breast carcinoma

Diagnosis	Her-2/neu staining		
	Positive	Negative	Total
Invasive ductal carcinoma	7	60	67
Invasive lobular carcinoma	2	7	9
Invasive medullary carcinoma	0	3	3
Invasive papillary carcinoma	0	2	2
Mucinous carcinoma	0	1	1
Clear cell carcinoma	0	1	1
Total	9	74	83

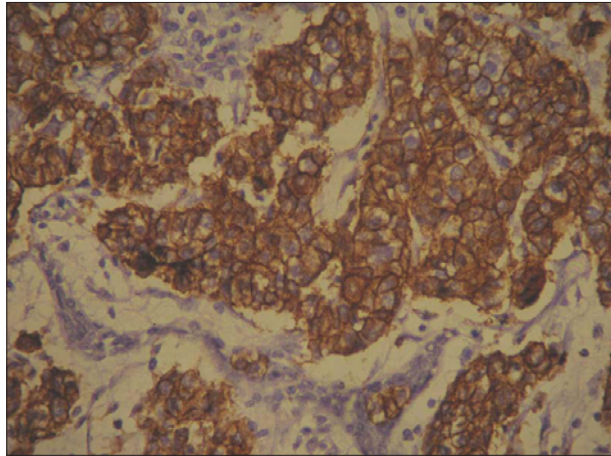


Figure 1: Photomicrograph of a grade III invasive ductal carcinoma showing positive membrane staining for Her-2/neu. (Her-2/neu +ve immunohistochemical stain, ×40).

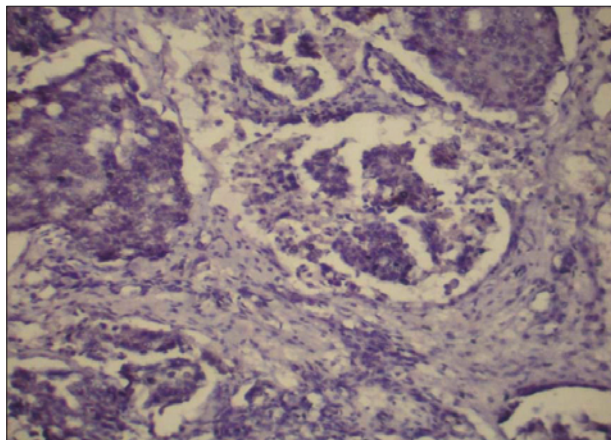


Figure 3: Photomicrograph of a grade II invasive ductal carcinoma showing negative membrane staining for Her-2/neu. (Her-2/neu -ve immunohistochemical stain, ×40).

cervical cancer as the leading cause of cancer mortality in women.^[2,13] Studies have shown that immunohistochemical determination of Her-2/neu positivity followed by trastuzumab administration is useful in the treatment of breast cancer.^[14] It is expected that routine use of trastuzumab following immunostaining for Her-2/neu should significantly increase patient survival and reduce mortality associated with breast cancer. IHC is presently

Table 4: Correlation of Her-2/neu status with the histological grade of the tumor

Grade	Her-2/neu status		
	Positive	Negative	Total
I	2	11	13
II	3	25	28
III	4	38	42
Total	9	74	83

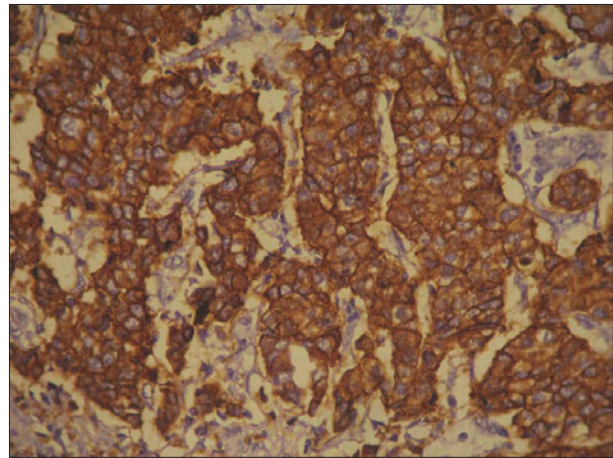


Figure 2: Photomicrograph of a grade III invasive ductal carcinoma showing positive membrane staining for Her-2/neu. (Her-2/neu +ve immunohistochemical stain, ×40)

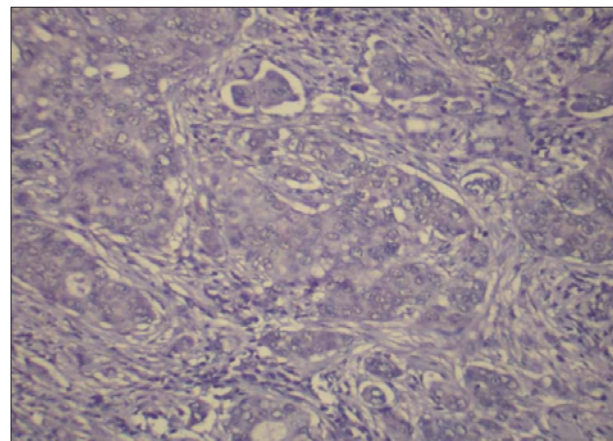


Figure 4: Photomicrograph of a grade III invasive ductal carcinoma showing negative membrane staining for Her-2/neu. (Her-2/neu -ve immunohistochemical stain, ×40).

the most frequently used method in assessing Her-2/neu status, because of its relatively low cost and technical availability in most pathology laboratories.^[7] Moreover, it can be performed on archival formalin-fixed, paraffin-embedded tissues with no particular need for specialized equipment and personnel. However, some studies have suggested FISH as the best technique for determining Her-2/neu status because of its reliability and reproducibility.^[3,7] This method of detection also corresponds well with tumor response and patients' survival resulting

from trastuzumab treatment. Nevertheless, its expensive and routine use is not feasible, particularly in low resource settings as ours.

Previous studies have shown that using various molecular and IHC procedures, the frequency of amplification or overexpression of Her-2/neu is 10 to 52% with an average of 15 to 25%.^[7,15] Jones *et al.* found no statistical significant difference in Her-2/neu expression in breast carcinoma occurring in African Americans and Caucasians, having recorded figures of 38.7% and 40% positivity for Her-2/neu, respectively.^[15] In this study, immunopositivity of breast carcinoma for Her-2/neu was 10.8%. Though comparable with the 8.2% recorded in Ile-Ife, it is much lower than the 17.1% and 25% documented in Ibadan and Jos, respectively.^[16-18] These figures are within the range of 10 to 52% documented in most studies worldwide. Nevertheless, only a few studies have been done to ascertain the pattern of Her-2/neu status in African breast cancer cases. Further studies are required to establish the true incidence of Her-2/neu status among the African population.

In this study, the mean age of Her-2/neu-positive breast carcinoma was 49.8 ± 15.6 years and that of Her-2/neu-negative tumors was 48.9 ± 13.4 . This age difference was not statistically significant ($\chi^2 = 31.62$, $df = 38$, $P = 0.785$). Prati *et al.*,^[3] while analyzing 199 cases of breast cancer in California, USA, had a similar observation. He found a mean age of 53.9 years and 57.6 years for Her-2/neu-positive and Her-2/neu-negative breast cancer patients, respectively. In a similar study, Rosen *et al.*,^[19] while studying 474 patients with lymph node negative breast cancer in New York, USA, observed that age did not predict or determine the likelihood of Her-2/neu positivity. The highest occurrence of Her-2/neu positivity in this study was in the 30 to 39 years age group. This is not surprising as the majority of breast cancer cases were found in this age range.

The various histological types of breast cancer did not show a statistically significant association with Her-2/neu status in this study. Invasive ductal and invasive lobular carcinomas were the only Her-2/neu-positive breast lesions demonstrating positivity in seven of 67 cases and two of nine cases, respectively. Invasive medullary, papillary, mucinous, and clear cell carcinomas were all negative for Her-2/neu. Several investigators have correlated Her-2/neu with histological type of breast carcinoma. Some have reported a lower frequency of Her-2/neu in invasive lobular carcinoma than in invasive ductal carcinoma, while the converse is true in other studies.^[19-21]

As an adverse prognostic factor, Her-2/neu positivity has been associated with poorly differentiated high-grade tumors, high proliferation rate, metastasis to lymph node,

and resistance to certain types of chemotherapy.^[22-24] The present study, however, did not find a significant relationship between tumor grade and the IHC detection of Her-2/neu ($\chi^2 = 0.352$, $df = 2$, $P = 0.838$). Grades I, II, and III tumors showed positivity in two of 13 cases, three of 28 cases, and four of 42 cases, respectively. Although this finding agrees with some investigators who found no association between Her-2/neu and tumor grade, the converse is true in other studies.^[19] Prati *et al.*^[3] found that poorly differentiated invasive ductal carcinoma had a higher frequency of Her-2/neu-positive tumors than moderately and well-differentiated tumors (36%, 10.2%, and 5.8%, respectively). Another study by Tsuda *et al.* in Tokyo, Japan, that included 176 cases using a modified Bloom-Richardson criteria for histological grading also found a strong correlation between Her-2/neu expression and tumor grade. He observed that poorly differentiated tumors overexpressed the Her-2/neu protein more frequently than the well-differentiated tumors.^[25]

Her-2/neu overexpression has been recognized as both a marker for aggressive disease and a target for treatment. There is often an inverse relationship between Her-2/neu positivity and hormone receptors. Studies have shown that women with Her-2/neu-positive breast cancers have relatively lower or absent hormone receptors in their tumors.^[8,23] This is probably one of the reasons why women who overexpress Her-2/neu in their breast cancers are resistant to tamoxifen.^[8] However, anthracycline-based adjuvant therapy is particularly beneficial to these patients.^[23]

About 35% of women with Her-2/neu-positive breast cancer have been found to respond to trastuzumab (Herceptin) therapy (a humanized monoclonal antibody against Her-2/neu).^[23] Studies indicate that combining trastuzumab with either single or multiple chemotherapeutic agents increases the therapeutic efficacy and prolongs patient's survival.^[23,4] Trastuzumab has not been shown to have clinical benefit in Her-2/neu-negative breast cancer.^[23] However, trastuzumab has an adverse effect of causing cardiac dysfunction. It is therefore essential to carefully determine the Her-2/neu status of patients with breast cancer using before institution of trastuzumab therapy.

Conclusions

The frequency of Her-2/neu status in this study is within the range of what has been reported all over the world. This study did not find associations of Her-2/neu status with patients' age, histological types, and tumor grade. This may be related to the sample size. Comprehensive, interinstitutional studies will be required to determine the exact frequency of Her-2/neu status in breast cancer patients in Nigeria. More so with such studies, important variables with prognostic significance may be identified.

Acknowledgment

We are very grateful to the Institute of Post-Graduate Medical Research and Training (IMRAT), College of Medicine, University of Ibadan, for taking full responsibility for the immunohistochemistry aspect of this work. Thanks to Professors Sola and Fummi Olopade for the funding of IMRAT. Special thanks to Mr. Abayomi and Miss Sola who did the bench work and especially to Dr. A.O Adeoye who created time out of his busy schedule to interpret the IHC slides. We are also indebted to Mrs. Adeyemi, Mr. Akimbo, and other laboratory staff for their support and cooperation.

References

- Veronesi U, Boyle P, Goldhirsch A, Orecchia R, Viale G. Breast cancer. *Lancet* 2005;365:1727-41.
- Adebamowo CA, Ogundiran TO, Adenipekun AA, Oyeseun RA, Campbell OB, Akang EE, *et al.* Waist-hip ratio and breast cancer risk in urbanized Nigerian women. *Breast Cancer Res* 2003;5:R18-23.
- Prati R, Apple SK, He J, Gornbein JA, Chang HR. Histopathologic characteristics predicting Her-2/neu Amplification in Breast Cancer. *Breast J* 2005;11:433-9.
- Yamauchi H, Stearns V, Hayes DF. When is a tumour marker ready for prime time? A case study of c-erbB-2 as a predictive factor in breast cancer. *J Clin Oncol* 2001;19:2334-56.
- Tawfik OW, Kimler BF, Davis M, Danahue JK, Persons DL, Fan F, *et al.* Comparison of immunohistochemistry by automated cellular imaging system (ACIS). Versus fluorescence *in-situ* hybridization in the evaluation of Her-2/neu expression in primary breast carcinoma. *Histopathology* 2006;48:258-67.
- Konecny G, Pauletti G, Pegram M, Untch M, Dandekar S, Aguilar Z, *et al.* Quantitative association between Her-2/neu and steroid receptors in hormone receptor-positive primary breast cancer. *J Natl Cancer Inst* 2003;95:142-53.
- Harris LN, Liotcheva V, Broadwater G, Ramirez MJ, Maimonis P, Anderson S, *et al.* Comparison of methods of measuring Her-2/neu in metastatic breast cancer patients treated with high dose chemotherapy. *J Clin Oncol* 2001;19:1698-706.
- Huang HJ, Neven P, Paridaens R, Amant F, Wildiers H, Berteloot F, *et al.* Association between tumour characteristics and Her-2/neu by immunohistochemistry in 1362 women with primary operable breast cancer. *J Clin Pathol* 2005;58:611-8.
- Burstein HJ. The distinctive nature of Her-2/neu positive breast cancers. *N Engl J Med* 2005;355:1652-4.
- Pritchard KI, Shepherd LE, O'Malley FP, Andrulis IL, Tu D, Levine MN, *et al.* Her-2/neu and responsiveness of breast cancer to adjuvant chemotherapy. *N Engl J Med* 2006;354:2103-11.
- World Health Organization. Pathology and genetics: Tumours of the breast and female genital organs. In: Tavassoli FA, Devilee P, editors. IARC Press; 2003. p. 10.
- Breast In Rosai and Ackerman's Surgical Pathology, 9th Ed. CV Mosby Company; 2004. p. 1763-876.
- Adesunkanmi AR, Lawal OO, Adelusola KA, Durosimi MA. The severity, outcome and challenges of breast cancer in Nigeria. *Breast J* 2006;15:399-409.
- Francis GD, Dimech M, Giles L, Hopkins A. Frequency and reliability of oestrogen receptor, progesterone receptor and Her-2/neu in breast carcinoma determined by immunohistochemistry in Australasia: Result of the RCPA quality assurance programme. *J Clin Pathol* 2007;60:1277-83.
- Jones BA, Kasi SV, Howe CL, Lachman M, Dubrow R, Curnen MM, *et al.* African-American/White differences in breast carcinoma. *Cancer* 2004;101:1293-301.
- Titiloye W. Histological pattern of epithelial breast cancer in Ile-Ife (OAUTH). A dissertation submitted to the National Postgraduate Medical College of Nigeria. May 2008.
- Adeoye AO. Histological and immunohistochemical patterns of breast cancer at the University College Hospital, Ibadan. A dissertation submitted to the West African College of Physicians. Oct 2007.
- Gukes ID, Jennings BA, Mandong BM, Igun GO, Girling AC, Manasseh AN, *et al.* Clinicopathological features and molecular markers of breast cancer in Jos Nigeria. *West Afr J Med* 2005;24:209-13.
- Rosen PP, Lesser ML, Arroyo CD, Crano M, Borgen P, Norton L. Immunohistochemical detection of Her-2/neu in patients with axillary lymph node negative breast carcinoma. *Cancer* 1995;75:1320-526.
- Van de Vijver MJ, Peterse JL, Mooi WJ, Wisman P, Lomans J, Dalesio O, *et al.* Neu-protein overexpression in breast cancer: Association with comedo-type ductal carcinoma *in situ* and limited prognostic value in Stage II breast cancer. *N Engl J Med* 1988;319:1239-45.
- Marx D, Schauer A, Reiche C, May A, Ummemhofer L, Reles A, *et al.* C-erbB2 expression in correlation to other biological parameters of breast cancer. *J Cancer Res Clin Oncol* 1990;116:15-20.
- Yamauchi H, Stearns V, Hayes DF. When is a tumour marker ready for prime time? A case study of c-erbB-2 as a predictive factor in breast cancer. *J Clin Oncol* 2001;19:2334-56.
- Burstein HJ. The distinctive nature of Her-2/neu positive breast cancers. *N Engl J Med* 2005;355:1652-4.
- Pritchard KI, Shepherd LE, O'Malley FP, Andrulis IL, Tu D, Levine MN, *et al.* Her-2/neu and responsiveness of breast cancer to adjuvant chemotherapy. *N Engl J Med* 2006;354:2103-11.
- Tsuda H, Hirohashi S, Shimosato Y, Hirota T, Tsugano S, Watanabe S, *et al.* Correlation between histologic grade of malignancy and copy number of c-erbB-2 gene in breast carcinoma. *Cancer* 1990;65:1794-800.

How to cite this article: Ugiagbe EE, Olu-Eddo AN, Obaseki DE. Immunohistochemical detection of Her-2/neu overexpression in breast carcinoma in Nigerians: A 5-year retrospective study. *Niger J Clin Pract* 2011;14:332-7.

Source of Support: Nil, **Conflict of Interest:** None declared.