

Cephalometric Assessment of the Fourth Ventricles Using Computerized Tomography: A Five Year Study in Usmanu Danfodiyo University Teaching Hospital (UDUTH), Sokoto, North-Western Nigeria

*¹J.D. Usman, ²G.H. Yunusa, ²S.A. Saidu, ¹A.D. Zagga, ¹A. Bello, ¹A. Abdulhameed, ¹S.S. Bello, ¹A.A. Tadros and ¹S.M. Bello

¹Departments of Anatomy, College of Health Sciences, Usmanu Danfodiyo University, Sokoto, Nigeria

²Departments of Radiology, College of Health Sciences, Usmanu Danfodiyo University, Sokoto, Nigeria

[*Corresponding Author: Email: ssbello2009@hotmail.com; ☎: +234(0)8030797690]

ABSTRACT: The fourth ventricle is usually affected in posterior cranial fossa tumours and other intracranial and ventricular disorders. Therefore, accurate measurement of the fourth ventricle will go a long way in evaluating brain disorders and decision making prior to neurosurgical procedures. This, therefore, places high premium on the accuracy in the technique and equipment used in obtaining a good Computerised Tomography (CT) Scan of the brain. To provide baseline data for measurements of normal fourth ventricle using computed tomographic Scan. Measurement was made with Dragon V3.1.1. A total of 652 scan examinations of subjects were analyzed in this study. 434 (65.79%) of the subjects were males while 217 (34.21%) were females. (M: F ratio = 2:1). The mean length of the fourth ventricles was 9.55mm and mean width was 12.86mm. Maximum length was 13.95mm and minimum length was 5.1mm. Least width was 2.65mm and greatest width was 17.28mm. Thus, the difference between the lengths of the fourth ventricles was not statistically significant ($p > 0.05$), so also there was no statistically significant difference ($p > 0.05$) between the width of the fourth ventricles in males and females. In conclusion, this study has provided reference ranges for the normal values of the length and width of the fourth ventricle in male and female Nigerians.

Keywords: Cephalometry, assessment, fourth ventricles, CT, Nigeria.

INTRODUCTION

Since its introduction by Broadbend and Hafrath in 1931 cephalometry has been one of the most important measurement tools in Orthodontics and Craniofacial surgery (Vancarter *et al.*, 2003). Radiographic cephalometry is based on two dimensional representations of a three dimensional structure. Therefore, several disadvantages are associated with this approach, such as overlap effect due to superimposition of anatomic structures, difficult analysis of asymmetrical anatomies, image quality and inter observer differences due to tracing variance (Okkers, 2009).

The need to study complete abnormal anatomies such as asymmetry caused interest for three- dimensional computed tomography (3D CT) to have risen over the last two decades (Vandersloten *et al.*, 2008). Three dimensional computed tomography (3D CT) cephalometry has gain popularity, because contours and surface details are presented in fine details (Gomeri *et al.*, 1984). Many methods have been described for measuring the fourth ventricular size as a means to evaluate brain atrophy during the normal

aging process and diseases (Huber *et al.*, 1990). The planimetric method requires special equipment, is not universally available and has many common sources of error with the linear measurement (Sabattini *et al.*, 2004).

According to Fox *et al.* (1975), Huckman *et al.* (1975), Lemay (1984) and Lee and Krishna (1987), modern computerized tomography allows easy and safe noninvasive study of the ventricular system, without complications.

Cephalometric analysis is used in dentistry, and especially in orthodontics, to gauge size and the special relation of the teeth, jaw and cranium. This analysis informs treatment plan and provides data for clinical research (Huber *et al.*, 1990). Ultrasound cephalometry is useful for determining the growth of the foetus in utero, and also to determine if the unborn child can pass through the birth canal, (Walkins, 2004). Studies by Gawler *et al.* (1976) revealed that the greatest distance between the roof and the floor of the fourth ventricle was less than 1.2cm with a mean of 1.08cm. According to Glydensted (1977), Gomori *et al.* (1984),

Takeda and Matsuzawa (1985) and Goldstein *et al.* (2001) normally the left ventricle was larger than the right one and both were larger in males among Caucasians.

However, in their study Medora and Natekar (2007), reported the height of the fourth ventricle to be greater in males (1.18cm, + 0.27, 95% CI, 0.65-1.71cm), than in females (1.11cm, + 0.24, 95% CI 0.65-1.58cm) and the width of the fourth ventricle was greater than the height in both genders and was more in males (1.31 +0.23, 95% CI, 0.85-1.77cm) than in females (1.21+ 0.22, 95% CI 0.79-1.64cm).

The aim of this morphometric study was to examine the range in size of the normal fourth ventricles of the brain, in both males and females, and to find any relationship with gender

MATERIALS AND METHOD

This study was carried out among 652 patients (434 males and 218 females) in the age group of 1 to 70 years, attending the Department of Radiology Usmanu Danfodiyo University Teaching Hospital Sokoto. The patients were selected randomly and had no history of head injury, local mass lesion, hydrocephalus or previous intra-cranial surgery.

Inclusion Criteria

Selection of the Brain CT scan for the study was based on the following:

- (a) Perfect positioning of the patient. With the Passage of the lowest tomographic section through a line 15–20 degrees to and 1cm above the cantho-meatal line which represent the base of the skull.
- (b) Distinct and clear limits of fourth ventricle.

Exclusion criteria:

- (a) All brain CT Scans showing pathological changes affecting the normal anatomy of the fourth ventricles.
- (b) All films that showed alteration of the ventricular size and shape of the ventricle by the pathological condition.
- (c) All brain CT scans with poor positioning of the patients.
- (d) All brain CT scans with poor quality of the scan images.

All the CT scans were ascertained to have been taken by a trained and experienced radiographer, in a standardized condition and manner. The patients were

placed on the CT table and the head was centralized and supported for correct alignment with head pads thus reducing blurring of images. A cantho-meatal line was drawn at an angle of 15-20 degree to and 1 cm above it, representing the lowest tomographic section which passed through the base of the skull.

Brain CT scans studied were of good quality and clearly showed the anatomical features of the fourth ventricles. Only radiographs interpreted by experienced radiologists were studied. Thus, the CT scans for measurement were selected on the basis of good positioning and absence of visible evidence of pathology, which may affect the normal anatomy of the fourth ventricles.

CT scan of all patients were reported by individual radiologist scoring as normal. The CT scanner used in this study was a NEUSOFT C 3000 dual slice helical CT (2005) model.

Brain CT Scans were obtained from the local data base of the CT machine and back up compact discs from the CT archives. Films were viewed on the computer monitor. Presence or absence of pathology was noted. The fourth ventricle was seen as an oval area at the center of the posterior fossa lower down, between the cerebellum and pons. Measurement was made with Dragon V3.1.1 (Philips and Neusoft Medical System Company Limited software). The software provides a meter rule with which measurements were done, based on the method employed by (Medora and Natekar, 2007).

Greatest height of fourth ventricle was measured from the roof and floor of the fourth ventricle and the width measured at the midpoint of the ventricle.

RESULTS

This study was carried out among 652 patients (434 males and 217 females) in the age group of 1 to 70 years. The height of the fourth ventricle was larger in males (10.15mm \pm 2.06, 95% CI) as compared to females (8.38mm \pm 1.69, 95%CI), which was not significant ($p > 0.05$). The width of the fourth ventricle was also observed to be greater in males (13.23mm \pm 1.99, 95%CI) than in females (12.17mm \pm 2.92, 95% CI), the difference is not significance ($p > 0.05$). The maximum height (13.95mm) in males and (11.03mm) in females, were seen in the age 75years and 46years respectively. The Least height recorded was (6.91mm)

Usman *et al.*: Cephalometric Assessment of the Fourth Ventricles Using Computerized Tomography:.....

in males and (5.1mm) in females. The greatest width recorded was (17.28mm) for males and (16.77mm) for females, while the least width was (9.35mm) males and

(2.65mm) females, seen in the ages 25years, 40years, 4years and 43years respectively.

Table 1: Dimensions of the Fourth Ventricles in Subjects in Sokoto

Parameter	Gender	
	Males(n=434)	Females(n=217)
Fourth ventricle height	10.15 ±2.06 (0.634)	8.38 ±1.69 (0.678)
Fourth ventricle width	13.23 ±1.99 (0.432)	12.17 ±2.92 (0.563)

Values are mean ± Standard Deviation. Values in parentheses are p-values at $p < 0.05$

DISCUSSION

The Human nervous system is the most complex, widely investigated and yet poorly understood physical system (Williams *et al.*, 1999). Studies revealed that brain regression involving both the cerebrum and the cerebellum usually begins by the seventh decade and thereafter accelerated with advancing age (Ellis, 1920; Volgt and Pakkenberg, 1964; Barron *et al.*, 1976; DeKaban and Sadowsky, 1978).

Studies by Gawler *et al.* (1976) revealed that the greatest distance between the roof and the floor of the fourth ventricle was less than 1.2cm. Medora and

Natekar (2007), reported the height of the fourth ventricle to be greater in males (1.18cm, + 0.27, 95% CI, 0.65-1.71cm), than in females (1.11cm, + 0.24, 95% CI 0.65-1.58cm). These values are slightly higher than what was observed in our study. The height of the fourth ventricle was larger in males (10.15mm ± 2.06, 95% CI) compared to females (8.38mm ± 1.69, 95%CI). In the present study, the width of the fourth ventricle was greater than the height in both gender and was more in males (13.23mm ± 1.99, 95%CI) than in females (12.17mm ±2.92, 95% CI). This is similar to those reported by Medora and Natekar (2007).

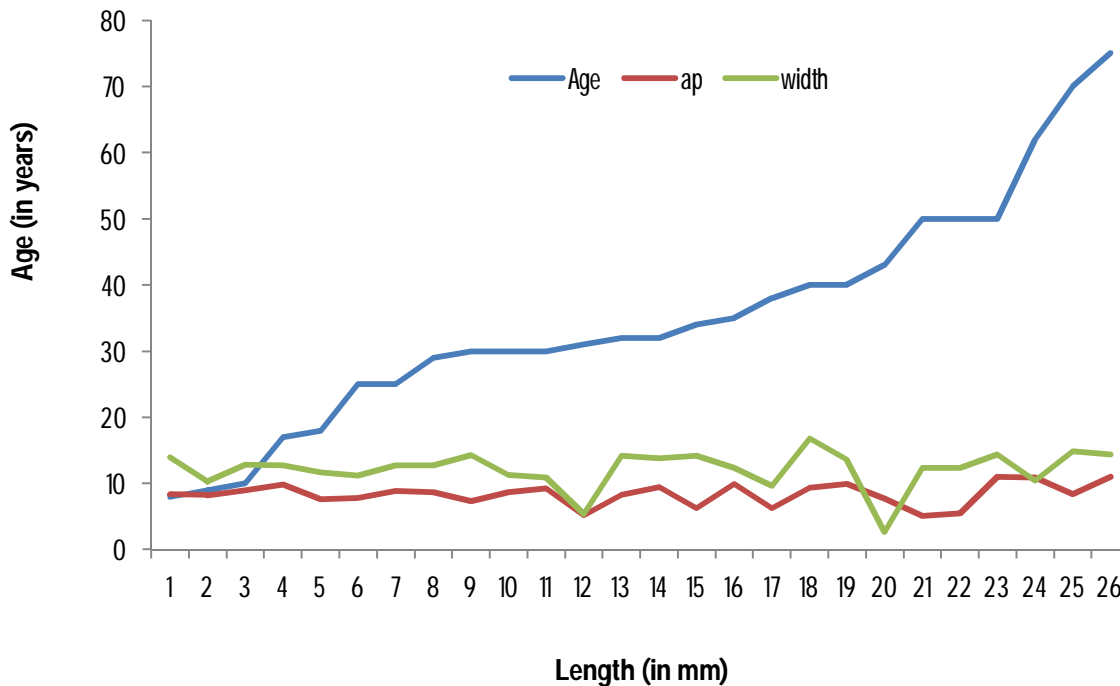


Figure 1: Variation of width and AP diameter of fourth ventricle with Age in females.

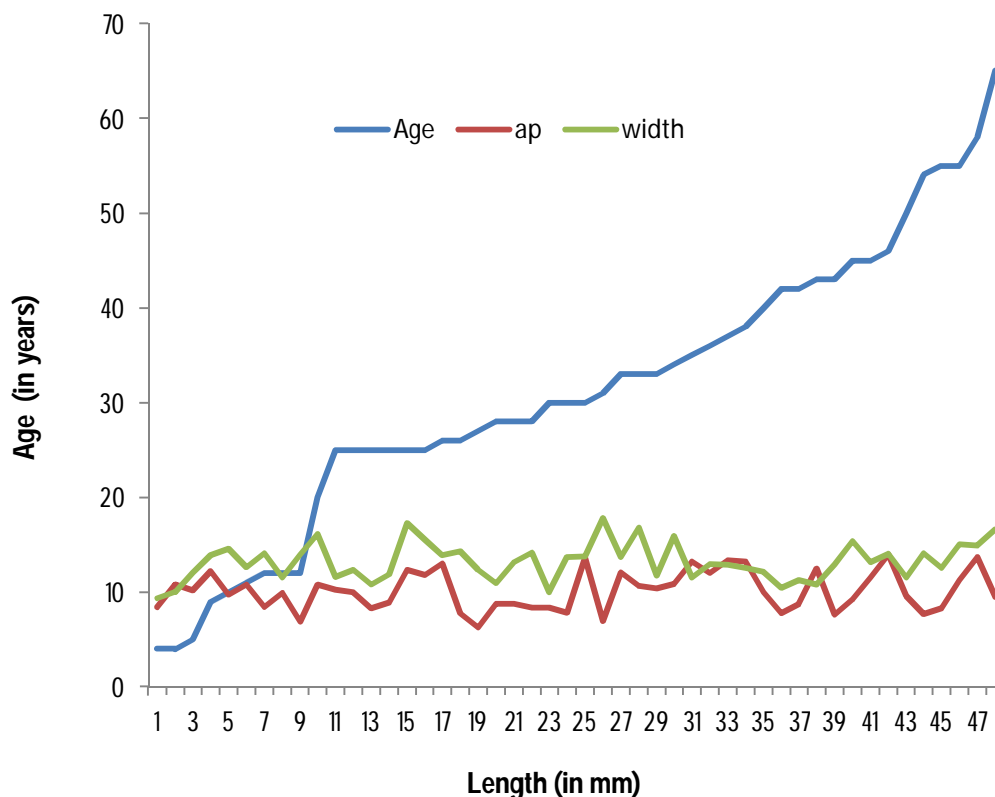


Figure 2: Variation of width and AP diameter of fourth ventricle with Age in males.

CONCLUSION

The study has generated baseline morphometric measurement of the fourth ventricle. The results indicate that there is no significance difference between the fourth ventricle (height and width) of male and female.

REFERENCES

- Barron, S.A., Jacobs, L. and Kinkel, W.R. (1976). Change in size of normal lateral ventricles during ageing determined by Computerised Tomography. *Neurology*, **26**:11-1013.
- Dekaban, A.S. and Sadowsky, D. (1978). Changes in brain weight during the span of human life: *Relation of brain weight to body height and body weight*. *Annals of Neurology* **4**: 345-356.
- Ellis, R.J. (1920). Norms for some structural changes in the human cerebellum from birth to old age. *Journal Comparative Neurology*, **32**: 1-33.
- Fox, J.H., Huckman, M.S. and Topel, J.L. (1975): The use of Computerised tomography in senile dementia. *Journal of Neurology Neurosurgery and Psychiatry*, **38**: 948-953.
- Gawler, J., Bull, J.W.D., duBoulay, G.H. and Marshall, J. (1976). Computerised axial tomography: The normal Electro Magnetic Imaging scan. *Journal of Neurosurgery and Psychiatry*, **38**: 935-947.
- Glydensted, C. (1977). Measurement of ventricular system and hemispheric sulci of 100 adults with Computerised tomography. *Neuroradiology*, **14**: 187-192.
- Goldstein, J.M., Seiman, L.J., Horton, N.J., Makris, N., Kennedy, D.N., Caviness, Jr, V.S. and Tsuang, M.T. (2001). *Normal sexual dimorphism of the adult human brain assessed by in vivo Magnetic Resonance Imaging*. *Cerebral Cortex*, **11(6)**: 490-497.
- Gomeri, J.M., Steiner, I. and Melamed, E. (1984). The assessment of changes in brain volume using combined linear measurement: A Computerised tomography study. *Neuroradiology*, **26**: 21-24.
- Huckman, M.S., Fox, J. and Topel, J. (1975). The validity of criteria for the evaluation of cerebral atrophy by Computerised tomography. *Radiology*, **116**: 85-92.
- Huber, S. J.; Chakeres, D. W.; Paulson, G. W. Jimmy, W. (1990): Magnetic resonance imaging in Parkinson's disease. *Arch. Neuro.* **47**; 735-737.

Usman et al.: Cephalometric Assessment of the Fourth Ventricles Using Computerized Tomography:.....

- Lee, S.H. and Krishna, C.U.G. (1987). *Computerised tomography and Magnetic resonance Imaging*. McGraw-Hill, New York.
- LeMay, M. (1984). Radiological changes of ageing brain and skull. *American Journal of Roentogenology*, **5**: 383-389.
- Medora, D.C. and Natekar P.E. (2007): Morphometric study of the ventricular system of brain by Computerised tomography: *Jour. Anat. Soc. India*. **56**(1): 19-24.
- Okkers, W. (2009): *Imaging of the head and neck*, 2ndedn. Raven press, New York. 735-737.
- Sabattini D., Helmke, K. and Winkler, P. (2004). The use of CT in senile dementia. *Jour. of Neurol. Neurosurgery and Craniofacial Surgery*,. **38**: 948-953.
- Takeda, S. and Matsuzawa, T. (1985). Age related changes in volume of the ventricles, cisternae and sulci: A quantitative study using Computerised tomography. *Journal of American German Society* **33**: 264-268.
- Vancarter J., Gillespie J.E. and Gholkar, M. (2003). *Magnetic resonance imaging and computed tomography of head and neck*. Chapman and Hall Medical, London 15: 525-527.
- Vandersloten, E., Bertrand, P.G., Vaillant, M.C. and Laugier, J. (2008). Area of lateral ventricles on cranial ultrasonography in preterm infants: reference range. *Arch Dis Child*, **65**: 1029-1032.
- Volgt, W. (1964). *Development of the nervous system*. New York , Academic press.
- Walkins, J. (2004). *Prediction of neurodevelopmental impairment at four years from brain ultrasound appearance of very preterm infants*. *Developmental Med Child Neurology* 30:711-22.
- Williams, P.L., Bannister, H., Berry, M.M., Collins, P., Dyson, M., Dssek, J.E. and Fergusson, M.W.J. (1999) (eds): *Gray's Anatomy*. 38th edition, Churchill Livingstone. London. Pp123-126, 486-490, 1205-1206.