

## Hepato-Protective Activities of Ethanol Extracts of African Eggplant and Bitter Leaf in Alloxan Induced Diabetic Rats

\*E. T George, O. A Oyesola, E. O Taiwo and I. I Owoye

Department of Physiology, Faculty of Basic Medical Science, Olabisi Onabanjo University

[\*Corresponding Author: E-mail: [georgeayoku@gmail.com](mailto:georgeayoku@gmail.com)]

### ABSTRACT

Diabetes is a metabolic disorder, which affect all system of the body including the liver. This study focused on the effect of the ethanol extract of African eggplant and bitter leaf and their combination on the liver structure, antioxidant enzymes activities and biochemical parameters in the liver of alloxan induced diabetic rats. Twenty-five male wistar rats were grouped into normal control group A, diabetic control group B, 100 mg/kg African eggplant extract treated group C, 100 mg/kg bitter leaf extract treated group D and combination of 100 mg/kg of African eggplant and 100 mg/kg bitter leaf treated group E. The results study showed that group E rats showed significant reduction in the activity of AST, ALP and AST. In the antioxidant enzyme activity, the administered extracts increased the antioxidant enzyme activities and reduced lipid peroxidation, thereby protecting the cells from oxidative stress. The micro- histo-architecture of the liver showed improvement and regenerative changes across the treated groups. The study reveal that combination of the ethanol leaf extract of bitter leaf and African eggplant can manage liver malfunction caused by diabetes.

**Keywords:** African-eggplant, Alloxan, Bitter-leaf, Diabetes, Liver

### INTRODUCTION

Diabetes mellitus (DM) is a severe, persistent, and complicated metabolic condition with various aetiologies that has severe acute and chronic complications (Soumya and Srilatha, 2011), Diabetes develops when the cells of the body are unable to adequately breakdown sugar due to the lack of insulin activity on target tissues caused by insulin insensitivity or insulin deficiency. The failure of insulin to metabolize sugar occurs when the pancreas does not produce enough insulin or when the body cannot effectively use the insulin that is produced, resulting in excessive blood sugar levels and the production of excess by-products known as ketones by the liver (Buowari, 2013; Folorunso and Oguntibeju, 2013). It is reported that this disorder affects 25% of the world's population (Arumugam *et al.*, 2013). Diabetes complications can disrupt numerous essential organ systems, resulting in more serious adverse disease states such as nephropathy, retinopathy, vasculopathy, neuropathy, cardiovascular disease, and hepatopathy (Reid, 2006).

Diabetes mellitus is becoming a severe hazard to human health in all parts of the world due to its fast-increasing prevalence. Furthermore, in recent years, due to the financial implications of treating diabetes, it related complications and the greater efficacy of some medicinal plants than oral hypoglycaemic medications commonly used in clinical therapy, many people in developing and developed countries have resorted to the use of medicinal plant in treatment and management of diabetes (Malviya *et al.*, 2010). Some medicinal plants have been reported in traditional medicine to be useful in the treatment and management of diabetes worldwide and have been used empirically as anti-diabetic and anti-hyperlipidemic remedies. The hypoglycemic influences of different medicinal plants are attributed to their ability to restore the

function of pancreatic tissues by causing an increase in insulin output or inhibit the intestinal absorption of glucose (Malviya *et al.*, 2010). African eggplant and bitter leaves are two vegetables which also serve as medicinal plant in tropical Africa. Traditionally bitter leaf plant is used to treat fever, hiccups, stomach aches, and diabetes mellitus (Asante *et al.*, 2016). African eggplant is used in traditional medicine as an anti-hyperlipidemic agent (Burkill, 1985), renal and protective effect (Sodipo *et al.*, 2008). African eggplant has been shown to have anti-inflammatory, anti-asthmatic, anti-glaucoma activities (Odetola *et al.*, 2004; Oboh *et al.*, 2005; Komlaga *et al.*, 2014). The liver is an insulin dependent tissue that plays an important role in glucose and lipid homeostasis, the liver is one of the major organs severely affected during diabetes. The liver participate in the uptake, oxidation and metabolic conversion of free fatty acids, synthesis of cholesterol, phospholipids and triglycerides. Since African eggplant and bitter leaf are two commonly consumed vegetables in tropical Africa and are claimed to have both anti-diabetic potential, this study evaluates the hepato- protective effect of the combination of ethanol leaf extract of African eggplant and bitter leaf on the liver structure, antioxidant enzyme activity, and liver enzymes in alloxan induced diabetes rats.

### MATERIALS AND METHODS

#### Chemical and Reagent

Analytical grade laboratory chemicals and reagents were used for this study. Alloxan monohydrate was purchased from Elabscience biotechnology Inc. USA. Absolute ethanol was purchased in Nigeria and was produced by Scharlab S. L, Spain. Liver enzymes assay kits were purchased from Randox from Laboratories Ltd. Antrim U.K.

### Plants Material

Matured leaves of bitter leaf plant were collected from an indigenous farm in Ikenne/Sagamu area of South-West Nigeria, while matured leaves of African eggplant were bought from a local market in Ikenne/Sagamu area of South-West Nigeria. These samples were identified and authenticated at the Department of Plant Science, Olabisi Onabanjo University, Ago-Iwoye, Ogun State, Nigeria.

### Preparation of the Ethanol Extract of African Eggplant and Bitter Leaf Plant

Leaves of African eggplant and bitter leaf plant were air-dried and powdered using a blender. Weighed powdered form of 150 g was soaked in 750 ml of ethanol (70% ethanol and 30% water) for 3 days inside a refrigerator. The resultant liquid was filtered using a funnel plugged with glass wool. After filtration, the filtrate was heated at a temperature of 40 °C for 5 min to allow ethanol to evaporate.

### Animal care and Induction of Diabetes

Twenty-five healthy male adult wistar rats weighing between 160 g and 200 g were used for this study. The rats were bred in plastic and wire gauze cages in the animal house of the Obafemi Awolowo College of Health Science, Sagamu Campus, Olabisi Onabanjo University, Ogun State, Nigeria. The rats were maintained on Growers' feed from Joyful Feed and Flour Mill Ltd, Ogun State. Food and water were provided *ad libitum*. Diabetes was induced by administering 150 mg/kg intra-peritoneal injection of alloxan monohydrate, before this, the animals fasted overnight and their fasting blood glucose levels were measured. Then, 48 h after administration of alloxan monohydrate, fasting blood glucose was evaluated with the aid of a glucometer (ACCU-CHECK, Roche, Germany) and animals with fasting blood glucose level  $\geq 200$  mg/dL were selected and used for the study

### Experimental Design

The rats were allowed to acclimatize for two weeks after which they were randomly grouped into five groups with five rats per group: Group A: normal rats, food and water only (normal control), Group B: diabetic control group (150 mg/kg of alloxan monohydrate), Group C: 150 mg/kg of alloxan monohydrate + 100 mg/kg of African eggplant ethanol leaf extract, Group D: 150 mg/kg of alloxan monohydrate + 100 mg/kg of bitter leaf plant ethanol leaf extract, Group E: 150 mg/kg of alloxan monohydrate + 100 mg of bitter leaf plant ethanol leaf extract (administered in the morning) and 100 mg/kg of African eggplant ethanol leaf extract (administered in the evening) (co-administration groups). Treatment was done for 14 days after which the rats were humanely sacrificed and blood collected for further analysis

### Blood Collection

Blood was collected from the orbital venous sinus. A capillary tube was inserted dorsally into the eye and blood was allowed to flow by capillary action through the capillary tube into a lithium heparinized sample bottle.

### Determination of Liver Function Parameters

The activity of aspartate aminotransferase (AST) was determined by kinetic method as reported by Young (1990). The alanine aminotransferase (ALT) activities were assayed by colorimetric endpoint method as described by Young *et al.*, (1975). The activity of alkaline phosphatase (ALP) was determined by colorimetric endpoint method (Kochmar and Moss, 1974).

### Determination of Antioxidant Enzymes

The liver tissues were homogenized in phosphate buffer in ratio 4:1. Superoxide dismutase (SOD) activities, glutathione reductase (GSH) activities, catalase (CAT) activities and malondialdehyde levels were determined. Superoxide dismutase activities were determined according to the method of Valerino and McCormack (1971). The activity of SOD was expressed as  $\mu\text{g}/\text{mg}$  protein. Reduced glutathione was determined using the method of Sedlak and Lindsay (1968). The amount of GSH was expressed as  $\mu\text{g}/\text{mg}$  protein (Jollow *et al.*, 1974). Catalase activity expressed as mmoles of  $\text{H}_2\text{O}_2$  consumed per minute per mg protein was determined following method described by Sinha (1972). Malondialdehyde (MDA) was determined spectrophotometrically from the pink color product of thiobarbituric acid (TBA) reactive substances complex and expressed as  $\mu\text{g}/\text{mg}$  protein (Ádám-Vizi and Sergi, 1982).

### Histological Examination

The liver tissue was fixed in 10% neutral buffered formalin, embedded in paraffin, and 5  $\mu\text{m}$  thick sections were prepared and stained with haematoxylin and eosin using standard procedures. The slides were viewed under light microscope and photomicrographs were taken (200 $\times$ )

### Statistical Analysis

The statistical analysis of data collected from twenty-five (25) male wistar rats was done using the SPSS statistical software package for windows (version 8.0) for data analysis. The data was presented as Mean  $\pm$  Standard Error of Mean (SEM) and statistical analysis was carried out using analysis of variance (ANOVA). Values were considered to be statistically significant when  $p < 0.05$

## RESULTS AND DISCUSSION

### Effect of the Administration of Ethanol Extracts of African Eggplant and Bitter Leaf Singly and in Combination on Liver Function of Diabetic Rats

Results of the effects of extract treatment on diabetic rats are presented in Table 1. There was significant increase in the liver enzyme activities of the diabetic group All

treatment groups were compared with the normal control and diabetic control, and the level of significance set at  $p < 0.05$ . The co-administration treatment showed significant reduction in the activities of liver enzymes. Bitter leaf plant extract treated group showed significant reduction in AST and ALT activities but increase in ALP activity. Group that received African eggplant leaf extract showed decrease in AST activity and increase in ALT and ALP activity.

**Table 1:** Effect of single and combined administrations of ethanol extracts of African eggplant and bitter leaf on liver function of diabetic rats

Group	AST (U/L)	ALT (U/L)	ALP (U/L)
A	9.67±2.19	17.33±2.74	34.33±6.03
B	29.40±6.84 <sup>a</sup>	41.0±4.18 <sup>a</sup>	74.4±7.09 <sup>a</sup>
C	16.20±6.98 <sup>a</sup>	47.2±13.86 <sup>a</sup>	81.2±20.67 <sup>a</sup>
D	7.00±0.00 <sup>a,b</sup>	28.40±12.08 <sup>a,b</sup>	75.4±10.69 <sup>a</sup>
E	7.00±0.00 <sup>a,b</sup>	25.80±5.02 <sup>a,b</sup>	26.4±9.50 <sup>a,b</sup>

Values are Mean ± SEM of replicate determinations. Superscript values a and b in a given column are significant ( $p < 0.05$ ) when compared with groups A and B respectively; AST: aspartate aminotransferase; ALT: alanine aminotransferase, ALP: alkaline phosphatase. Group A: normal control; Group B: diabetic control; Group C: diabetic group + 100 mg/kg ethanol extracts of African eggplant. Group D: diabetic group + 100 mg/kg of ethanol extract of bitter leaf; Group E: diabetic group + 100 mg/kg of co-administered ethanol extracts of bitter leaf and African eggplant

The increase observed in liver enzymes activities of the diabetic rats indicated liver malfunction. The activity of some basic liver function enzymes in the serum, such as AST, ALT, and ALP can be used to indirectly evaluate liver function and the degree of damage after exposure to a pharmacological substance like Alloxan (Ravikumar *et al.*, 2010). As observed in this study, hepatotoxicity is characterized by abnormal increased activities of liver enzymes ALT, AST, and ALP as detected in the plasma (Woodman, 1966; Vozarova *et al.*, 2002; Senior, 2009; Eze *et al.*, 2012). The co-administered extract treated group and bitter leaf plant extract treated group showed significant reduction in the activities of AST and ALT when compared to the diabetes control, suggesting co-administration of 100 mg/kg bitter leaf and African eggplant probably had hepatoprotective effect on the liver in diabetic rats.

#### Effect of Administration of Ethanol Extracts of African Eggplant and Bitter Leaf Singly and in Combination on Antioxidant Enzymes Activities in the Liver of Diabetic Rats

As presented in Table 2, the GSH activity in the liver increased across all treatment groups, but these changes were not significant however, SOD and CAT activities increased significantly in the liver across all treatment groups when compared to the normal control as well as the diabetic control groups. The results also show MDA levels of the diabetic control group significantly increased when compared with the normal control group. However, except for group E animals that received extract co-administration, the other diabetic groups that received extracts treatments singly did not show any difference in MDA levels when compared with the untreated diabetic control group.

Diabetes is widely recognized as one of many chronic illnesses that causes oxidative stress. The reduction of antioxidant enzymes activities and an elevation in free radical production led to increases in oxidative stress (Baynes and Thorpe, 1999). Furthermore, over production of MDA is caused by an increase in free radicals (Gawel *et al.*, 2004). As shown in this study co-administration of African eggplant and bitter leaf ethanol extracts decreased the MDA levels suggesting the extracts may play a role in ameliorating lipid peroxidation in liver tissues of diabetic rats. Moreover, the activities of SOD, GSH and CAT increased after 14 days treatment when compared to the diabetic control group which supports the observed decrease in MDA levels as an indicator of improved oxidative status following treatment.

#### Histopathological Examination of Liver of Diabetic Rats Treated with Ethanol Extracts of African Eggplant and Bitter Leaf

Figure 1 shows the effect of the ethanol extracts of African eggplant and bitter leaf plant on the liver of diabetic rats, Figure 1 (A) represent the normal control liver showing normal liver tissue well defined hepatocytes (red circle), central vein (black thick arrow), sinusoid (black thin arrow) and well-organized hepatic plate. The untreated diabetic group (Figure 1B) shows degeneration of liver cells, disorientation and congested central vein (black thick arrow), disoriented hepatic plate with progressive constriction of the sinusoids (black thin arrow). Liver photomicrograph (Figure 1C) of diabetic rats administered with African eggplant extract (group C) reveal a restoration in liver cell morphology (yellow thin arrow), congested central vein (black thick arrow), with well-organized hepatocytes (black circle) and hepatic plates while Figure 1D also shows restored liver cell morphology with congested central vein (black thick arrow), well differentiated hepatocytes (blue circle) sinusoids (black thin arrow) and hepatic plates for group that received bitter leaf ethanol extract.

**Table 2:** Effect of administration of ethanol extracts of African eggplant and bitter leaf on antioxidant indices of the liver in alloxan induced diabetic rats

Group	GSH ( $\mu\text{g}/\text{mg}$ protein)	SOD ( $\mu\text{g}/\text{mg}$ protein)	CAT ( $\mu\text{mol}/\text{ml}/\text{min}/\text{mg}$ pro)	MDA ( $\mu\text{g}/\text{mg}$ protein)
A	128.6 $\pm$ 14.69	1.89 $\pm$ 0.05	8.10 $\pm$ 0.50	1.19 $\pm$ 0.01
B	106.09 $\pm$ 36.4	1.11 $\pm$ 0.26 <sup>a</sup>	7.47 $\pm$ 1.79	1.91 $\pm$ 0.85 <sup>a</sup>
C	128.7 $\pm$ 9.02	2.62 $\pm$ 0.42 <sup>a,b</sup>	10.4 $\pm$ 0.61 <sup>a</sup>	1.28 $\pm$ 0.08 <sup>a</sup>
D	133.3 $\pm$ 18.7	2.82 $\pm$ 0.62 <sup>a,b</sup>	12.08 $\pm$ 2.17 <sup>a,b</sup>	1.81 $\pm$ 0.61 <sup>a</sup>
E	142.4 $\pm$ 28.90	3.88 $\pm$ 0.43 <sup>a,b</sup>	15.42 $\pm$ 0.89 <sup>a,b</sup>	1.16 $\pm$ 0.52

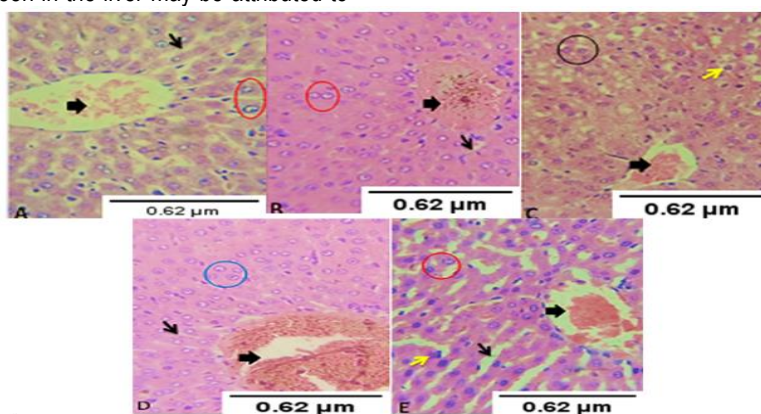
Values are Mean  $\pm$  SEM of replicate determinations. Superscript values a and b in a given column are significant ( $p < 0.05$ ) when compared with groups A and B respectively; GSH: glutathione, SOD: super oxide dismutase, CAT: catalase, MDA: malondialdehyde. Group A: normal control; Group B: diabetic control; Group C: diabetic group + 100 mg/kg ethanol extracts of African eggplant. Group D: diabetic group + 100 mg/kg of ethanol extract of bitter leaf; Group E: diabetic group + 100 mg/kg of co-administered ethanol extracts of bitter leaf and African eggplant.

In rats treated with co-administered extracts, a mild restoration of the hepatic tissue, dilated sinusoids (black thin arrow), congested central vein (black thick arrow), well defined hepatocytes (black circle) and regular hepatic plate were observed. The liver degeneration observed in the diabetic control indicate liver disorders ranging from steatosis to cirrhosis (Farrell and Larter, 2006; Smith and Adams, 2011; Ahmadieh and Azar, 2014). Dysfunction of the liver in diabetes causes disruptions including abnormal liver enzymes activities and oxidative stress as shown in this study and elsewhere (Doi *et al.*, 1997). The regenerative changes seen in the liver may be attributed to

the presence of phytochemicals with antioxidant properties in the administered plant extracts (Erasto *et al.*, 2007; Ho *et al.*, 2012; Komlaga *et al.*, 2014; Eletta *et al.*, 2017).

### CONCLUSION

Findings of this study reveal the co-administration of the ethanol extracts of African eggplant and bitter leaf probably has hepato-protective and antioxidant properties and has shown to be more effective in the management of diabetic rats compared to the individually administered extracts.



**Figure 1:** Photomicrograph of the liver of diabetic rats treated with African eggplant and bitter leaf ( $\times 200$ )  
a = normal control; b = diabetic control; c = diabetic rat + 100 mg/kg of african eggplant ethanol leaf extract. d = diabetic rat + 100 mg/kg of bitter leaf plant ethanol extract; e = diabetic rat + 100 mg/kg co-administration of extracts of african eggplant and bitter leaf.

### REFERENCES

- Ádám-Vizi, V. and Seregi, A. (1982). Receptor independent stimulatory effect of noradrenaline on Na, K-ATPase in rat brain homogenate: Role of lipid peroxidation. *Biochemical Pharmacology*, **31**(13): 2231-2236.
- Ahmadieh, H. and Azar, S. T. (2014). Liver disease and diabetes: Association, pathophysiology, and management. *Diabetes Research and Clinical Practice*, **104**: 53–62.
- Arumugam, G., Manjula, P. and Paari, N. (2013). A review: Anti diabetic medicinal plants used for diabetes mellitus. *Journal of Acute Disease*, **2**(3): 196-200.
- Asante, D., Effah-Yeboah, E., Barnes, P., Abban, H. A., Ameyaw, E. O., Boampong, J. N., Ofori, E. G. and Dadzie, J. B. (2016). Antidiabetic effect of young and old ethanolic leaf extracts of *Vernonia amygdalina*: A comparative study. *Journal of Diabetes Research*, Article ID 8252741.
- Baynes, J. W., and Thorpe, S. R. (1999). Role of oxidative stress in diabetic complications: a new perspective on an old paradigm. *Diabetes*, **48**(1), 1-9.
- Buowari, O. Y. (2013). Diabetes mellitus in developing countries and case series. Diabetes mellitus-insights and perspectives. Rijeka, Croatia: *InTechOpen*, 131.

- Burkill, H. M. (1985). The useful plants of West Tropical Africa. Vol. 1. Families AD (No.Ed. 2). *Royal Botanic Gardens*.
- Doi, K., Yamanouchi, J., Kume, E. and Yasoshima, A. (1997). Morphologic changes in hepatocyte nuclei of streptozotocin (SZ)-induced diabetic mice. *Experimental and Toxicologic Pathology*, **49**(3-4), 295-299.
- Eletta, O. A. A., Orimolade, B. O., Oluwaniyi, O. O. and Dosumu, O. O. (2017). Evaluation of proximate and antioxidant activities of Ethiopian eggplant (*Solanum aethiopicum* L) and Gboma eggplant (*Solanum macrocarpon* L). *Journal of Applied Sciences and Environmental Management*, **21**(5): 967-972.
- Erasto, P., Grierson, D. S. and Afolayan, A. J. (2007). Evaluation of antioxidant activity and the fatty acid profile of the leaves of *Vernonia amygdalina* growing in South Africa. *Food Chemistry*, **104**(2): 636-642.
- Eze, E. D., Dawud, F. A., Zainab, A. A., Jimoh, A., Malgwi, I. S. and Isa, A. S. (2012). Preliminary studies of effects of vitamin C and zinc on some liver enzymes in alloxan-induced diabetic Wistar rats. *Asian Journal of Medical Science*, **4**(1):17-22.
- Farrell, G. C. and Larter, C. Z. (2006). Nonalcoholic fatty liver disease: From steatosis to cirrhosis. *Hepatology*, **43**(S1): 99-112.
- Folorunso, O. and Oguntibeju, O. (2013). The role of nutrition in the management of diabetes mellitus. *Diabetes mellitus—insights and perspectives*, **83**.
- Gawel, S., Wardas, M., Niedworok, E. and Wardas, P. (2004). Malondialdehyde (MDA) as a lipid peroxidation marker. *Wiadomosci lekarskie (Warsaw, Poland: 1960)*, **57**(9-10), 453-455.
- Ho, W. Y., Liang, W. S., Yeap, S. K., Beh, B. K., Yousef, A. H. N. and Alitheen, N. B. (2012). In vitro and in vivo antioxidant activity of *Vernonia amygdalina* water extract. *African Journal of Biotechnology*, **11**(17): 4090-4094.
- Jollow, D. J., Mitchell, J. R., Zampaglione, N. and Gillette, J. R. (1974). Bromobenzene-induced liver necrosis. protective role of glutathione and evidence for 3, 4-bromobenzene oxide as the hepatotoxic metabolite. *Pharmacology*, **11**(3): 151-169.
- Kochmar, J. F. and Moss, D. W. (1974). *Fundamentals of Clinical Chemistry*, N.W. Tietz.
- Komlaga, G., Sam, G. H., Dickson, R. A., Mensah, M. L. K. and Fleischer, T. C. (2014). Pharmacognostic studies and antioxidant properties of the leaves of *Solanum macrocarpon*. *Journal of Pharmaceutical Sciences and Research*, **6**(1): 1.
- Malviya, N., Jain, S. and Malviya, S. A. P. N. A. (2010). Antidiabetic potential of medicinal plants. *Acta Poloniae Pharmaceutica*, **67**(2): 113-118.
- Oboh, G., Ekperigin, M. M. and Kazeem, M. I. (2005). Nutritional and haemolytic properties of eggplants (*Solanum macrocarpon*) leaves. *Journal of Food Composition and Analysis*, **18**(2-3): 153-160.
- Odetola, A. A., Iranloye, Y. O. and Akinloye, O. (2004). Hypolipidaemic potentials of *Solanum melongena* and *Solanum gilo* on hypercholesterolemic rabbits. *Pakistan Journal of Nutrition*, **3**(3):180-187.
- Ravikummar, R., Krishnamoorthy, P. and Kalidoss, A. (2010). Antidiabetic and antioxidant efficacy of *Andrographis paniculata* in alloxanized albino rats. *International Journal of Pharmacy and Technology*, **2**(4): 1016-1027.
- Reid, A. E. (2006) Non-alcoholic fatty liver disease. In: Feldman M, Friedman LS, Brandt LJ, editors. *Sleisenger and Fordtran's Gastrointestinal and Liver Disease: Pathophysiology/diagnosis/management*. 8th ed. St Louis, Missouri, USA: Saunders. pp. 1772-99.
- Sedlak, J. and Lindsay, R. H. (1968). Estimation of total, protein-bound, and nonprotein sulfhydryl groups in tissue with Ellman's reagent. *Analytical Biochemistry*, **25**: 192-205.
- Senior, J. R. (2009). Monitoring for hepatotoxicity: what is the predictive value of liver "function" tests? *Clinical Pharmacology & Therapeutics*, **85**(3):331-334.
- Sinha, A. K. (1972). Colorimetric assay of catalase. *Analytical Biochemistry*, **47**(2), 389-394.
- Smith, B. W. and Adams, L. A. (2011). Non-alcoholic fatty liver disease and diabetes mellitus: Pathogenesis and treatment. *Nature Reviews Endocrinology*, **7**: 456-465.
- Sodipo, O. A., Abdulrahman, F. I., Akan, J. C. and Akinniyi, J. A. (2008). Phytochemical screening and elemental constituents of the fruit of *Solanum macrocarpum* Linn. *Continental Journal of Applied Sciences*, **3**: 85-94.
- Soumya, D. and Srilatha, B. (2011). Latestage complications of diabetes and insulin resistance. *Journal of Diabetes & Metabolism*, **2**(9): 1000167.
- Valerino, D. M. and McCormack, J. J. (1971). Xanthine oxidase-mediated oxidation of epinephrine. *Biochemical Pharmacology*, **20**(1): 47-55.
- Vojarova, B., Stefan, N., Lindsay, R. S., Saremi, A., Pratley, R. E., Bogardus, C. and Tataranni, P. A. (2002). High alanine aminotransferase is associated with decreased hepatic insulin sensitivity and predicts the development of type 2 diabetes. *Diabetes*, **51**(6):1889-1895.
- Woodman, D. D. (1996). Assessment of hepatotoxicity. *Animal Clinical Chemistry: A Practical Handbook for Toxicologists and Biomedical Researchers*, 66.
- Young, D. S. (1990). Effects of drugs on clinical laboratory tests (Vol. 1). American Association for Clinical Chemistry, Incorporated.
- Young, D. S., Pestaner, L. C., and Gibberman, V. A. L. (1975). Effects of drugs on clinical laboratory tests. *Clinical chemistry*, **21**(5): 1D-432D.
- Zhang, X. F. and Tan, B. K. H. (2000). Antihyperglycaemic and anti-oxidant properties of *Andrographis paniculata* in normal and diabetic rats. *Clinical and Experimental Pharmacology and Physiology*, **27**(5-6): 358-363.