

Protective Effect of Vitamin E on Nicotine Induced Reproductive Toxicity in Male Rats

*¹W.A. Oyeyemi, ²S.T. Shittu, ³T.A. Kolawole, ³P. Ubancheand ¹A.O. Akinola

¹Igbinedion University, Department of Physiology, School of Basic Medical Sciences, Okada, Edo State, Nigeria

²University of Ibadan, Dept. of Physiology, Faculty of Basic Medical Sciences, College of Medicine, Ibadan, Nigeria

³Madonna University, Department of Physiology, Faculty of Basic Medical Sciences, Elele campus, Rivers state, Nigeria.

[*Corresponding author: Email oyeyemiwahab@gmail.com; ☎: +2347034891903]

ABSTRACT: The current study assessed the protective role of vitamin E in alleviating the detrimental effect of nicotine on reproductive functions in male rats. Twenty four male albino rats were divided into four groups of six rats. Control group was treated orally with 1.1 ml/kg body weight normal saline, nicotine treated group received 1.0 mg/kg body weight of nicotine, vitamin E treated group received 100 mg/kg body weight of vitamin E while nicotine plus vitamin E treated group received 1.0 mg/kg body weight of nicotine plus 100 mg/kg body weight of vitamin E. The administration of nicotine and vitamin E were done orally for 40 days. Nicotine caused a significant reduction ($p < 0.05$) in sperm count, sperm motility, sperm viability and normal sperm cells. It also caused a significant reduction ($p < 0.05$) in serum testosterone, follicle stimulating hormone and luteinizing hormone levels. There was impairment in testicular histology of rats treated with nicotine. Vitamin E improved the reduction in sperm characteristics, hormone levels and testicular alterations observed in nicotine treated rats. The study shows that nicotine exerts significant deleterious effects on male reproductive system and the concurrent administration of vitamin E ameliorated these detrimental effects.

Key words: Nicotine, Vitamin E, Sperm toxicity, FSH, LH, Testosterone

INTRODUCTION

Infertility affects approximately 15% of all couples trying to conceive. Male infertility is the sole or contributing factor in roughly half of these cases and no identifiable cause can be found in over 25% of infertile males (Yales *et al.*, 1989; Yeşilli *et al.*, 2005). However the etiology of male infertility is poorly understood. While some individuals may be genetically predisposed to be sub-fertile (Reijo *et al.*, 1996), there are major epigenetic factors which are implicated as potential causes of male infertility.

The male reproductive system is known to be highly sensitive to many chemicals and drugs which have been found to pose adverse effects on male reproductive capacity under certain conditions (Bonde, 1996). The health implications of cigarette smoking and the use of tobacco products are well known.

Tobacco smoke contains numerous compounds, the important substances of medical significance being the carcinogens, irritant substances, nicotine, carbon monoxide and other gases (Russell *et al.*, 1981). Nicotine is considered the primary chemical in tobacco that is responsible for engendering tobacco use and dependence (Armitage *et al.*, 1975; Stillman *et al.*, 1986). Some effects of nicotine on reproduction

have been reported (Di Chiara, 2000; Harvey *et al.*, 2004), Aydos *et al.* (2001) reported that nicotine adversely affected spermatogenesis, epididymal sperm count, motility and the fertilizing potential of sperms. There are a lot of controversies on the effect of nicotine on changes in testosterone level, but most studies have associated nicotine with decreased serum testosterone (Lambers and Clark, 1996; Iranloye and Bolarinwa, 2009).

The deleterious toxic effects of nicotine have been linked to increased production of reactive oxygen species (ROS) (Bandopadhyay *et al.*, 2008; Sudheer *et al.*, 2008). ROS damages DNA, proteins, carbohydrates, and lipids and affects enzyme activity and cellular genetic machinery (Bandopadhyay *et al.*, 2008). However, the biological systems possess a number of mechanisms to remove ROS, such as the integrated antioxidant defence systems (Seema *et al.*, 2007; Bandopadhyay *et al.*, 2008) and also, several studies have shown that vitamin supplement such as ascorbic acid and vitamin E reduce the oxidative stress induced by toxic substances in the testis (Luck *et al.*, 1995; Rajiet *et al.*, 2003; Krishnamoorthy *et al.*, 2007; Kutlubay *et al.*, 2007).

It has been shown in our previous study that vitamin E improves growth rate and reproductive functions in female rats exposed to nicotine (Okewumi *et al.*, 2012) and also several studies have shown that vitamin E reduced oxidative stress induced by toxic substances. This present study was designed to evaluate if vitamin E has any effect on reproductive toxicity induced by nicotine in male albino wistar rats.

MATERIALS AND METHODS

Nicotine

Nicotine hydrogen tartrate (product number 26140, 95% nicotine) was obtained from BDH Chemical Ltd Poole England. Nicotine stock solution was prepared at concentration of 1mg/ml and stored in foil-wrapped glass bottle at 4^o C for no longer than 10 days. The nicotine dosage freshly prepared in normal saline was delivered at 1.0mg/kg per body weight.

Animals and Experimental Design

Twenty four male albino wistar rats whose weight ranged between 160 and 180 g were used for this study. The animals were housed in plastic cages that were well ventilated with a 12/12-hour light/ dark condition at room temperature. They had free access to food and water. The experiment was conducted in accordance with the Guidelines of the U.S. National Institute of Health (NIH) on the care and use of laboratory animals. The animals were randomly divided into four groups and treated as follows; Group A (Control) received 1.1ml/kg bwt of vehicle, Group B (Nicotine) received 1.0 mg/kg bwt of nicotine, Group C (Vitamin E) received 100 mg/kg bwt of vitamin E, and Group D (Nicotine + Vitamin E) received 1.0mg/kg bwt of nicotine with 100mg/kg bwt of vitamin E. The administration of the vehicle, nicotine and vitamin E were done orally for 40 days consecutively.

The blood sample was collected from the animals on day 41 through cardiac puncture for hormone assay. The animals' testes with epididymis were dissected and used for sperm analysis and testicular histopathological study.

Sperm Analysis

Progressive sperm motility was tested immediately. Spermatozoa was squeezed from the cauda epididymis onto microscope slide, two drops of normal saline was added to it and then covered with a cover slip. The slide was examined and scored under the microscope using x40 objective with reduced light (Raji *et al.*, 2003).

Sperm viability study (percentage of live spermatozoa) was done using eosin/nigrosin stain. Epididymis sperm was squeezed onto a microscope slide and two drops of the stain was added to it. The motile (live) sperm cells were unstained while the non-motile (dead) sperms absorbed the stain. The stained and the unstained sperm cells were counted using x40 microscope objectives and an average value for each was recorded from which percentage viability was calculated (Acharya *et al.*, 2008).

Sperm count was done under a microscope with the aid of the improved Neubauerhemocytometer. The cauda epididymis was carefully separated from the testis and homogenized in 2 ml of normal saline and the suspension was obtained. The suspension was diluted with sodium bicarbonate-formalin in ratio 1 to 20. The improved Neubauerhemocytometer chamber was filled with well diluted sperm then the sperm were counted in 2 sq mm of Neubauerhemocytometer chamber. The sperm counts were calculated in 1 ml of fluid by multiplying the number counted by 100,000 (Acharya *et al.*, 2008).

Sperm morphology was evaluated by staining the sperm smears on microscope slides with two drops of Walls and Ewas stain after they were air dried. The slides were examined under the microscope under oil immersion with x100 objective. The abnormal sperm cells were counted and the percentage calculated according to the method described by Sarkar *et al.*, (2006).

Serum Hormonal Analysis

Serum was obtained from blood sample collected and used for testosterone, follicle stimulating hormone (FSH) and luteinizing hormone (LH) assay. The concentration of testosterone was measured by using DRG Diagnostics testosterone kit, Germany, while FSH and LH concentration were analyzed using Monobind CA kit, USA. The hormone analysis was done according to the manufacturer's protocol.

Testicular Histopathological Study

This was carried out according to Raji *et al.*, (2003). One testis of each rat was removed and quickly fixed in buoin's fluid for at least 24 hours and the fixed specimen was processed through the conventional paraffin embedding technique and later sectioned at 0.05mm thick and stained with Mayer's haematoxylin-eosin dye (H&E). Each slide was cleaned-blotted and

mounted in Canada balsam under a cover slip. A photomicrograph of the slide preparation was taken after examination under the microscope.

STATISTICAL ANALYSIS

The results are expressed as mean \pm SEM for six animals per group. Microsoft excel 2010 (Microsoft Corporation) and IBM SPSS (version 20) were used to analyze the data and one-way analysis of variance (ANOVA) and post hoc test (Least Significant Difference) were used to assess the statistical significance of the data. P value less than 0.05 was considered significant.

RESULTS

Sperm Characteristics

There was a significant ($p < 0.05$) reduction in sperm motility, viability, count and normal morphology in nicotine and nicotine with vitamin E treated rats when

compared with the control group. While vitamin E treated rats had significantly increased ($p < 0.05$) sperm motility but significant reduction ($p < 0.05$) in viability and counts compared to the control group. However, sperm motility, viability, count and percentage normal sperm were significantly improved ($p < 0.05$) in group co-treated with nicotine and vitamin E when compared with the nicotine group (Table 1).

Hormonal Level

As shown in Table 2, FSH, LH and testosterone were significantly decreased ($p < 0.05$) in the nicotine and nicotine with vitamin E groups compared to the control group. However, the reduction was less marked in rats co-treated with nicotine and vitamin E relative to nicotine group. Vitamin E group showed significant reduction in FSH and testosterone ($p < 0.05$), while LH was significantly increased compared to the control group.

Table 1: Effect of Vitamin E on Sperm Characteristics in Nicotine Induced Reproductive Toxicity in Male Rats

Groups	Motility (%)	Viability (%)	Counts (million/ml)	Morphology (%)
Control	67.2 \pm 1.59	77.0 \pm 1.82	47.4 \pm 2.79	79.0 \pm 2.86
Nicotine	38.8 \pm 1.74*	42.0 \pm 1.00*	17.2 \pm 1.80*	59.0 \pm 3.03*
Vitamin E	77.6 \pm 1.12*	67.0 \pm 2.03*	40.0 \pm 1.61*	80.8 \pm 0.80
Nicotine+ Vitamin E	49.6 \pm 2.79**	52.4 \pm 2.25**	28.8 \pm 1.39**	72.2 \pm 1.07**

Values are expressed as mean \pm SEM, *significant difference relative to control and nicotine respectively

Table 2: Effect of Vitamin E on FSH, LH and Testosterone in Nicotine Induced Reproductive Toxicity in Male Rats

Groups	FSH (miu/ml)	LH (miu/ml)	Testosterone (ng/ml)
Control	10.96 \pm 0.68	9.35 \pm 0.30	12.89 \pm 0.008
Nicotine	0.66 \pm 0.04*	2.58 \pm 0.04*	12.61 \pm 0.020*
Vitamin E	8.48 \pm 0.33*	21.04 \pm 0.24*	12.70 \pm 0.080*
Nicotine + Vitamin E	1.93 \pm 0.12**	3.88 \pm 0.15**	12.65 \pm 0.031**

Values are expressed as mean \pm SEM, **significant difference relative to control and nicotine respectively

DISCUSSION

This study was conducted to evaluate the effect of vitamin E on sperm motility, viability, count, morphology, serum FSH, LH, testosterone and testicular histology in nicotine induced reproductive toxicity of male rats. The markedly impaired sperm motility, viability, count and morphology in nicotine treated rats observed in this study is in agreement with earlier reports of Seema *et al.*, (2007), Reddy *et al.*, (1995), Oyeyipo *et al.*, (2011). The observed reduction in sperm indices may be due to the action of nicotine in generating reactive oxygen species and lipid peroxidation in the testes (Seema *et al.*, 2007; Aruldas *et al.*, 2005), these nicotine effect had been reported to

cause decrease in testicular germ cells and spermatogenesis in rats (Pigeolot *et al.*, 1990; Jana *et al.*, 2010). The susceptibility of sperm cell to lipid peroxidation is adduced to the abundance of unsaturated fatty acid in its plasma membrane and to a very low concentration of cytoplasmic antioxidants (Aitken *et al.*, 1993).

Decrease level of testosterone is one of the indicators of chemical toxicity in male reproduction (Yoshida *et al.*, 2002) as it is essential to maintain spermatogenesis, structure and function of the male accessory sex glands. Accordingly, decreased sperm indices are

accompanied with decrease testosterone level in this study.

The observed decrease level of testosterone noticed in nicotine treated rats may be as a result of the concomitant decreased levels of serum follicle stimulating hormone (FSH) and luteinizing hormone (LH), hormones produced by the anterior pituitary lobe which are necessary for maintaining testosterone level through the hypothalamo-pituitary-testicular axis. This impairment in the hypothalamo-pituitary-testicular axis may be due to oxidative stress induced in the brain of the rats by nicotine. Also, there are ample experimental

data that supported the adverse effect of nicotine on the hypothamic-pituitary-testicular axis (Zavos and Zarmakoupis-Zavos, 1999; Funabashi *et al.*, 2005). It has been proposed that the nicotine may acts on GABA neurons to inhibit the activity of GnRH (Knobil, 1980) which serve as a regulator of testosterone through FSH and LH feedback mechanism. Recently, the low level of testosterone followed nicotine exposure has been linked to the inhibition in the testicular expression of 3 and 17 β -hydrosteroid dehydrogenase as these are the key enzymes for testicular androgenesis (Jana *et al.*, 2010).

Testicular Histology

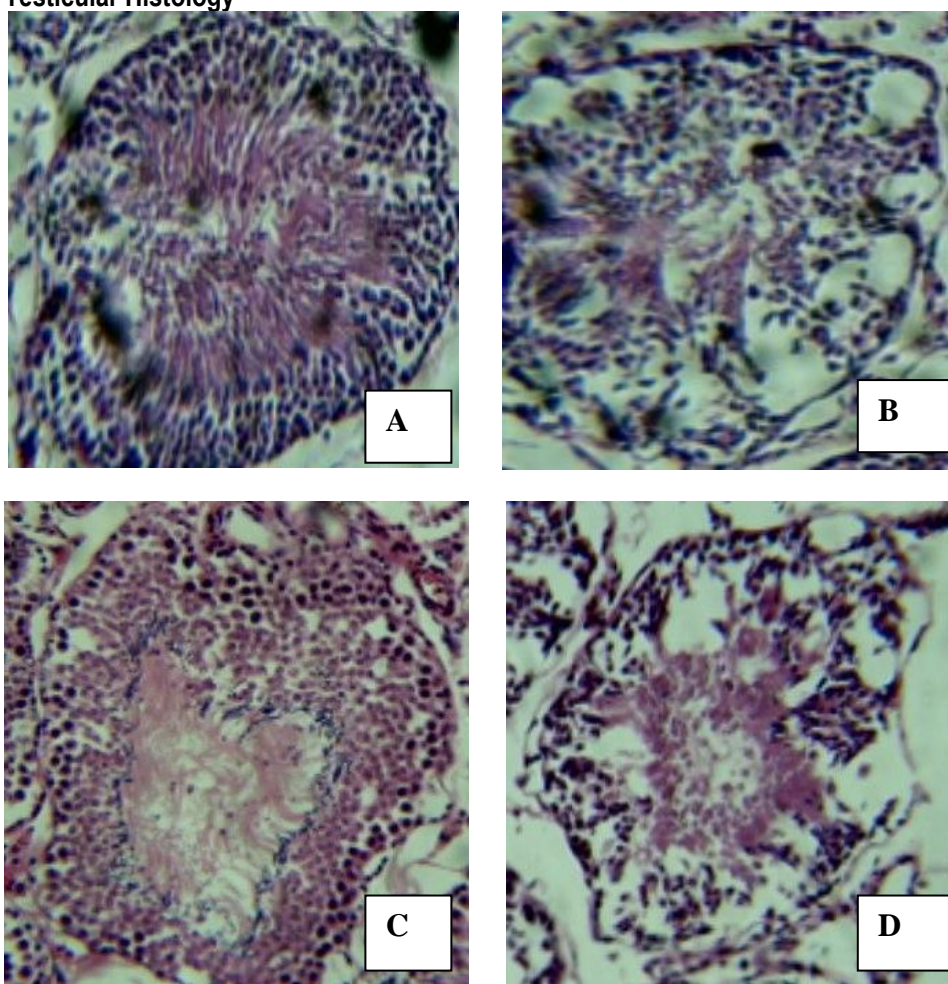


Figure 1: Photomicrograph showing H&E stained testes of (A) control rats showing normal testes histoarchitecture. (B) Nicotine treated rats showing shrunken, buckled, disorganized seminiferous tubules, vacuolation and sloughing of the germinal epithelium in the lumen of seminiferous tubules. (C) Vitamin E treated group with normal testes histoarchitecture. (D) Nicotine and vitamin E treated group showing few seminiferous tubules contained sloughed germinal epithelium, marked improvement of spermatogenesis.

The adverse effect of nicotine on sperm indices in this study could be supported by the testicular histopathological results (Figure 1). Nicotine provoked some histopathological changes in the testis such as degenerative changes of the majority of the seminiferous tubules. These changes were characterized by shrunken, disorganized seminiferous tubules with irregular, buckled basement membrane and incomplete spermatogenesis (Figure 1 A and B). Vacuolar degeneration of spermatogonia and sertoli cells was evident. Degenerated germinal epithelial cells were slough in the luminal of most seminiferous tubules. Other tubules showed coagulative necrosis and depletion of germinal epithelium with hyalination of the luminal. These testicular histological changes may be attributed to nicotine induced lipid peroxidation and the reduction in testosterone hormone (Oyeyipo *et al.*, 2011). Wherein, testosterone is needed for the attachment of different generations of germ cells in seminiferous tubules

Administration of vitamin E significantly improved the evaluated indices in nicotine treated rats, albeit not all were identical to the control levels. Vitamin E alleviated the reduction in sperm motility, viability, count, morphology, serum hormone levels and the histopathological degenerations of the testes that were observed in nicotine treated rats (Figure 1 C and D). Studies have shown that supplementation of Vitamin E in nicotine treated rats improve both sperm quality and quantity (Akiyama, 1990; Cerolini *et al.*, 2006; Yue *et al.*, 2010; Shittuet *et al.*, 2013). The beneficial effect of vitamin E is mostly due to its antioxidant potentials. It is a lipid soluble antioxidant which plays a major protective role against oxidative stress and prevents the production of lipid peroxides by scavenging free radicals which are toxic byproducts of many metabolic processes in biological membranes (Akiyama, 1990). Moreover, it is essential in maintaining the physiological integrity of testes, epididymis and accessory glands (Cerolini *et al.*, 2006), which has vital role in spermatogenesis and sperm maturation consequently improving sperm quality and quantity.

Also, significant increase in serum testosterone, FSH and LH levels were observed in nicotine treated rats supplemented with vitamin E. This may be due to the ability of vitamin E to mop up reactive oxygen species, and prevent lipid peroxidation of the sperm cells, hypothalamic-pituitary-testicular axis (Cerolini *et al.*, 2006; Aybek *et al.*, 2008). Several studies have shown

that vitamin E reduce the oxidative stress induced by toxic substances in the testis (Luck , 1995; Raji *et al.*, 2003; Krishnamoorthy *et al.*, 2007; Kutlubay *et al.*, 2007).

CONCLUSION

This study demonstrated the deleterious effect of nicotine on male reproductive hormones and sperm indices, which is however ameliorated by supplementation with vitamin E.

REFERENCES

- Acharya, U.R., Mishra, M., Patro, J. and Panda, M.K. (2008). Effect of vitamins C and E on spermatogenesis in mice exposed to cadmium. *Reproductive Toxicology*, **25**: 84-88.
- Aitken, R.J., Harkiss, D.U. and Buckingham, D.E. (1993). Analysis of lipid peroxidation mechanism in human spermatozoa. *Molecular Reproduction and Development*, **35**: 302-315.
- Akiyama, M. (1990). In vivo scavenging effect of ethylcysteine on reactive oxygen species in human semen. *Nippon Hinyokika Gakkai Zashi*, **90**: 421-428.
- Armitage, A.K., Dollery, C.T., George, C.F., Houseman, T.H., Lewis, P.J. and Turner, D.M. (1975). Absorption and metabolism of nicotine from cigarettes. *British Medical Journal*, **4**: 313-316.
- Aruldhas, M.M., Subramanian, S., Sekar, P., Vengatesh, G., Chandrahasan, G., Govindarajulu, P. and Akbarsha, M.A. (2005). Chronic chromium exposure-induced changes in testicular histoarchitecture are associated with oxidative stress: study in a non-human primate (*Macaca radiata* Geoffroy). *Human Reproduction*, **20**: 2801-2813.
- Aybek, H., Aybek, Z., Rota, S., Sxen, N. and Akbulut, M. (2008). The effects of diabetes mellitus, age, and vitamin E on testicular oxidative stress. *Fertility and Sterility*, **90**: 755-760.
- Aydos, K., Guven, M.C., Can, B. and Ergun, A. (2001). Nicotine toxicity to the ultra-structure of the testis in rats. *British Journal of Urology International*, **88**: 622-626.
- Bandopadhyay, G., Sinha, S., Chattopadhyay, B.D. and Chakraborty, A. (2008). Role of cucumin against nicotine induced genotoxicity on rat liver under restricted dietary protein. *European Journal of Pharmacology*, **588**: 151-157.
- Bonde, J.P. (1996). Environmental factors. In Comhaire, F.M. (ed.), *Male infertility, clinical*

- investigation, cause evaluation and treatment. Chapman and Hall, London. pp. 267-284.
- Cerolini, S., Zaniboni, I., Maldjian, A. and Gliozzi, T. (2006). Effect of docosahexanoic acid and α -tocopherol enrichment in chicken sperm on semen quality, sperm lipid composition and susceptibility to peroxidation. *Theriogenology*, **66**: 877-886.
- Di Chiara, G. (2000). Role of dopamine in the behavioural actions of nicotine related to addiction. *European Journal of Pharmacology*, **393**: 295-314.
- Funabashi, T., Sano, A., Matsushima, D. and Kimura, F. (2005). Nicotine inhibits pulsatile luteinizing hormone secretion in human males but not in human females, and tolerance to this nicotine effect is lost within one week of quitting smoking. *Journal of Clinical Endocrinology and Metabolism*, **90**: 3908-3913.
- Harvey, D.M., Yasar, J., Heishman, S.J., Panlilio, L.V., Henningfield, J.E. and Goldberg, S.R. (2004). Nicotine serves as an effective reinforce of intravenous drug taking behaviors in human cigarette smoking. *Psychopharmacology*, **175**: 134-142.
- Iranloye, B.O. and Bolarinwa, A.F. (2009). Effect of nicotine administration on weight and histology of some vital visceral organs in female albino rats. *Nigerian Journal of Physiological Sciences*, **24(1)**: 7-12.
- Jana, K., Samanta, P.K. and De, D.K. (2010). Nicotine diminishes testicular gametogenesis, steroidogenesis, and steroidogenic acute regulatory protein expression in adult albino rats: Possible influence on pituitary gonadotropins and alteration of testicular antioxidant status. *Toxicological Sciences*, **116(2)**: 647-659.
- Knobil, E. (1980). The neuroendocrine control of menstrual cycle. *Recent Progress in Hormone Research*, **36**: 53-88.
- Krishnamoorthy, G., Venkataraman, P., Arunkumar, A., Vignesh, R.C., Aruldas, M.M. and Arunakaran, J. (2007). Ameliorative effect of vitamins (alpha-tocopherol and ascorbic acid) on PCB (Aroclor 1254) induced oxidative stress in rat epididymal sperm. *Reproductive Toxicology*, **23**: 239-245.
- Kutlubay, R., Oguz, E.O., Can, B., Guven, M.C., Sinik, Z. and Tuncay, O.L. (2007). Vitamin E protection from testicular damage caused by intraperitoneal aluminium. *International Journal of Toxicology*, **26**: 297-306.
- Lambers, D.S. and Clark, K.E. (1996). The maternal and fetal physiologic effects of nicotine. *Seminars in Perinatology*, **20**: 115-126.
- Luck, M.R., Jeyaseelan, I. and Scholes, R.A. (1995). Ascorbic acid and fertility. *Biology of Reproduction*, **52**: 262-266.
- Okewumi, T.A., Edo, E.G., Shittu, S.T., Oyeyemi, F.B., Ugwuezumba, P.C. and Oyeyemi, A. W. (2012). Vitamin E improves growth rate and reproductive functions in female rats exposed to nicotine. *International Journal of Biological and Medical Research*, **3**: 1715-1719.
- Oyeyipo, I.P., Raji, Y., Emikpe, B.O. and Bolarinwa, A.F. (2011). Effects of nicotine on sperm characteristics and fertility profile in adult male rats: A possible role of cessation. *Journal of Reproductive Infertility*, **12**: 201-207.
- Pigeolot, E.P., Corbisier, A., Houbion, D., Lambert, C., Michiels, M., Raes, M.D. and Remacle, J. (1990). Glutathione peroxidase, superoxide dismutase and catalase inactivation by peroxides and oxygen derived free radicals. *Mechanism of Ageing and Development*, **51**: 283-297.
- Raji, Y., Udoh, U.S., Mewoyeka, O.O., Ononye, F.C. and Bolarinwa, A.F. (2003). Implication of reproductive endocrine malfunction in male antifertility efficacy of *Azadirachta indica* extract in rats. *African Journal of Medical Sciences*, **32**: 159-165.
- Reddy, A., Sood, A., Rust, P.F., Busby, J.E., Varn, E. and Mathur, R.S. (1995). The effect of nicotine on in-vitro sperm motion characteristics. *Journal of Assisted Reproduction and Genetics*, **12**: 217-223.
- Reijo, R., Alagappan, R.K., Patrizio, P. and Page, D.C. (1996). Severe oligozoospermia resulting from deletions of azoospermia factor gene on Y chromosome. *Lancet*, **347**: 1290-1293.
- Russell, M.A., Jarvis, M.J., Devitt, G. and Feyerabend, C. (1981). Nicotine intake by snuff users. *British Medical Journal (Clinical Research Edition)*, **283**: 814-817.
- Sarkar, S.D., Maiti, R. and Ghosh, D. (2006). Management of fluoride induced testicular disorders by calcium and vitamin-E co-administration in the albino rat. *Reproductive Toxicology*, **22**: 606-612.
- Seema, P., Swathy, S.S. and Indira, M. (2007). Protective effect of selenium on nicotine-induced testicular toxicity in rats. *Biological Trace Element Research*, **120**: 212-218.

- Shittu, S.T., Oyeyemi, W.A., Okewumi, T.A. and Salman, T.M. (2013). Role of oxidative stress in therapeutic administration of artesunate on sperm quality and testosterone level in male albino rats. *African Journal of Biotechnology*, **12**: 70-73.
- Stillman, R.J., Rosenberg, M.J. and Sacks, B.P. (1986). Smoking and reproduction. *Fertility and Sterility*, **46**: 545-566.
- Sudheer, A.R., Muthukumaran, S., Devipriya, N., Devraj, H. and Menon, V.P. (2008). Influence of ferulic acid on nicotine induced lipid peroxidation, DNA damage and inflammation in experimental rats as compared to N-acetylcysteine. *Toxicology*, **243**: 317-329.
- Yales, C.A., Thomas, C., Kovacs, G.T. and De Krester, D.M. (1989). Androgen, male factor, infertility and IVF, in Wood C, Trouson A, editors, *Clinical in vitro fertilization*. (USA, Springer-Verlag). pp. 95-111.
- Yeşilli, C., Mungan, G., Seçkiner, I., Akduman, B., Açikgöz, S. and Altan, K. (2005). Effect of varicocele on sperm creatine kinase, Hsp A₂ chaperone protein (creatine kinase-M type), LDH, LDH-X, and lipid peroxidation product levels in infertile men with varicocele. *Urology*, **66**: 610-615.
- Yoshida, M., Kitani, T., Takenaka, A., Kudoh, K. and Katsuda, S.I. (2002). Lack of effects of oxonolic acid on spermatogenesis in young and aged male wistar rats. *Food Chemical Toxicology*, **40**: 1815-1825.
- Yue, D., Yan, L., Luo, H., Xu, X. and Jin, X. (2010). Effect of vitamin E supplementation on semen quality and the testicular cell membrane and mitochondrial antioxidant abilities in Aohan fine – wool sheep. *Animal Reproductive Sciences*, **118**: 217-222.
- Zavos, P.M. and Zarmakoupis-Zavos, P.N. (1999). Impact of cigarette smoking on human reproduction: its effects on male and female fecundity. *Technology*, **6**: 9-16.